SONOVue®

sulfur hexafluoride

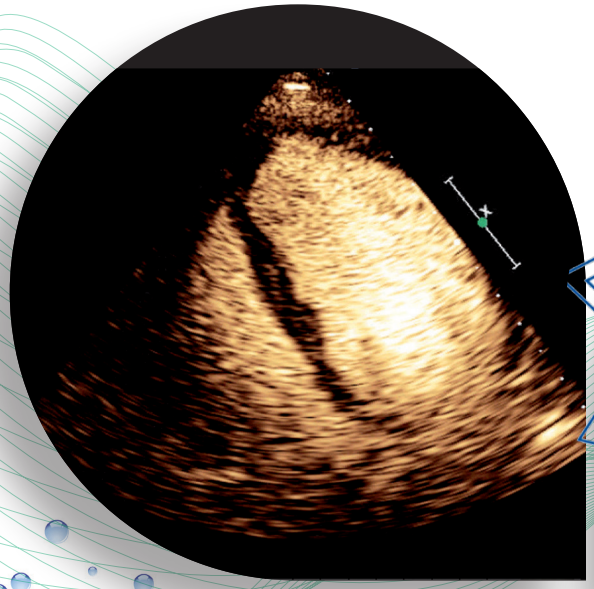

NEW INDICATION FOR **VUR** IN PEDIATRIC POPULATION

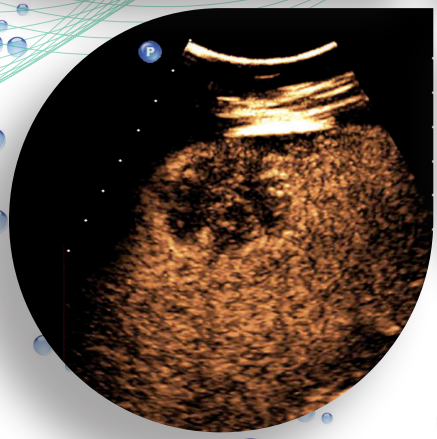

SONOVUE®

sulfur hexafluoride suspension for injection

DYNAMIC CONTRAST ENHANCEMENT IN REAL TIME

TABLE OF CONTENTS

PART I
HEALTH PROFESSIONAL INFORMATION

SUMMARY PRODUCT INFORMATION . . . 5
INDICATIONS AND CLINICAL USE . . . 5
CONTRAINDICATIONS . . . 5
WARNINGS AND PRECAUTIONS . . . 6
ADVERSE REACTIONS . . . 8
DRUG INTERACTIONS . . . 11
DOSAGE AND ADMINISTRATION . . . 12
OVERDOSAGE . . . 13
ACTION AND CLINICAL PHARMACOLOGY . . . 13
STORAGE AND STABILITY . . . 14
DOSAGE FORMS, COMPOSITION AND PACKAGING . . . 14

PART II
SCIENTIFIC INFORMATION

PHARMACEUTICAL INFORMATION . . . 15
CLINICAL TRIALS . . . 16
DETAILED PHARMACOLOGY . . . 18
IN VITRO DATA . . . 18
IN VIVO DATA . . . 19
TOXICOLOGY . . . 23
REFERENCES . . . 25

PART III
CONSUMER INFORMATION

CONSUMER INFORMATION . . . 26

PART I

HEALTH PROFESSIONAL INFORMATION

SUMMARY PRODUCT INFORMATION

ROUTE OF ADMINISTRATION	DOSAGE FORM/STRENGTH	CLINICALLY RELEVANT NON-MEDICINAL INGREDIENTS
Intravenous Intravesical	suspension for injection – 48µg/mL (8µL/mL)	For a complete listing, see the Dosage Forms, Composition and Packaging section of the product monograph

INDICATIONS AND CLINICAL USE

SonoVue® (sulfur hexafluoride) is indicated for use with ultrasound imaging to enhance the echogenicity of the blood, which results in an improved signal-to-noise ratio. SonoVue should only be used in patients where examination without contrast enhancement is inconclusive.

- **Endocardial Border Delineation:** SonoVue can be used in echocardiography in patients with suspected or established cardiovascular diseases to improve visualization of cardiac chambers and endocardial border delineation, which assists in the assessment of left ventricular wall motion.
- **Diagnostic Assessment of Vessels:** SonoVue increases the accuracy in detection or exclusion of abnormalities in cerebral and extracranial carotid and peripheral arteries by facilitating the Doppler evaluation of blood flow. SonoVue increases the quality of Doppler image and the duration of clinically useful signal enhancement in abdominal and renal arteries and in portal vein assessment.
- **Assessment of Vesicoureteral Reflux:** SonoVue is indicated for use in ultrasonography of the urinary tract in pediatric patients for the evaluation of suspected or known vesicoureteral reflux.

GERIATRICS (>65 YEARS OF AGE):
Evidence from clinical studies and experience suggests that use in the geriatric population is not associated with differences in safety or effectiveness (See WARNINGS AND PRECAUTIONS – Special Populations).

PEDIATRICS (<18 YEARS OF AGE):
Safety and efficacy in pediatric patients have not been established for use in echocardiography, nor in diagnostic assessment of vessels.

The product should be administered under the supervision of a qualified health professional who is experienced in the use of the diagnostic ultrasound contrast agents and in the management of hypersensitivity reactions, including severe allergic reactions. Appropriate management of therapy and complications is only possible when adequate diagnostic and treatment facilities are readily available.

CONTRAINDICATIONS

SonoVue is contraindicated in:

- Patients who are hypersensitive to this drug or to any ingredient in the formulation or component of the container. For a complete listing, see the DOSAGE FORMS, COMPOSITION AND PACKAGING section of the product monograph.
- Patients with known right-to-left cardiac shunts. In these patients, microbubbles can bypass filtering by the lung and directly enter the arterial circulation.
- Patients with severe pulmonary hypertension (pulmonary artery pressure >90 mmHg), uncontrolled systemic hypertension, and adult respiratory distress syndrome.

SonoVue should not be used in combination with dobutamine in patients with conditions suggesting cardiovascular instability where dobutamine is contraindicated.

WARNINGS AND PRECAUTIONS

SERIOUS WARNINGS AND PRECAUTIONS

Severe allergic reactions have been experienced with the use of SonoVue (see **WARNINGS AND PRECAUTIONS** – Immune and **ADVERSE REACTIONS** – Post-Market Adverse Drug Reactions).

Serious cardiopulmonary reactions, including fatalities, have occurred during or following the injection of SonoVue (see **WARNINGS AND PRECAUTIONS** – Cardiovascular). Most serious reactions occur within 30 minutes of administration.

- Assess all patients for the presence of any condition that precludes SonoVue administration (see **CONTRAINDICATIONS**).
- Always have resuscitation equipment and trained personnel readily available (see **WARNINGS AND PRECAUTIONS**).

GENERAL

Diagnostic procedures that involve the use of contrast agents should be carried out under direction of a physician with the prerequisite training and a thorough knowledge of the procedure to be performed. Appropriate facilities must be available for coping with any complication of the procedure, as well as for emergency treatment of severe reactions to the contrast agent itself.

The patient must be monitored for 30 minutes after the examination. Electrocardiogram (ECG) and blood pressure monitoring should be performed during a SonoVue-enhanced echocardiography with a pharmacological stress agent. Electrocardiogram monitoring should be also performed in high-risk patients as clinically indicated.

In animal studies, the application of echo-contrast agents revealed biological side effects (e.g., endothelial cell injury, capillary rupture) by interaction with the ultrasound beam. Although these biological side effects have not been reported in humans, exposure As Low As Reasonably Achievable (ALARA) should be used in any relevant mode of imaging. The use of a low mechanical index is recommended.

There is limited experience with SonoVue in patients with acute systemic inflammation and/or sepsis; SonoVue should be administered with extreme caution to patients with these conditions.

Particular caution should be taken with patients on beta blockers (including eye drop preparations) as in the event of an anaphylactic reaction following the administration of contrast media the effectiveness of the emergency medication will be reduced (see **DRUG-DRUG INTERACTIONS**).

CARCINOGENESIS AND MUTAGENESIS

No human data is available. No long-term animal studies were conducted to evaluate the carcinogenic potential of SonoVue since it is for single use.

The array of *in vitro* and *in vivo* tests performed on procaryotic organisms, animals, and cultured human lymphocytes with SonoVue did not reveal any problem or potential problem concerning mutagenesis or chromosome damage (See **TOXICOLOGY**).

CARDIOVASCULAR

It should be emphasised that stress echocardiography, which can mimic an ischaemic episode, could potentially increase the risk of SonoVue utilisation. Therefore, if SonoVue is to be used in conjunction with stress echocardiography, patients must have a stable condition verified by absence of chest pain or ECG modification during the two preceding days. Moreover, ECG and blood pressure monitoring should be performed during SonoVue-enhanced echocardiography with a pharmacological stress (e.g., with dobutamine).

Use extreme caution when considering the administration of SonoVue in patients with recent acute coronary syndrome or clinically unstable ischaemic cardiac disease, including: evolving or ongoing myocardial infarction, typical angina at rest within last 7 days, significant worsening of cardiac symptoms within last 7 days, recent coronary artery intervention or other factors suggesting clinical instability (for example, recent deterioration of ECG, laboratory or clinical findings), acute cardiac failure, Class III/IV cardiac failure, or severe rhythm disorders because in these patients allergy-like and/or vasodilatory reactions may lead to life threatening conditions. SonoVue should only be administered to such patients

after careful risk/benefit assessment and a close monitoring of vital signs should be performed during and after administration.

Emergency equipment and personnel trained in its use must be readily available.

Extreme caution should be exercised when considering administration of SonoVue to patients with congenital heart defects.

There is limited experience with SonoVue in patients with serious arrhythmias, recent infarction with ongoing and/or unstable angina, acute endocarditis, and prosthetic valves. SonoVue should be administered with extreme caution to patients with these conditions.

ELECTROCARDIOGRAPHIC (ECG) CHANGES

High ultrasound mechanical index values may cause microsphere cavitation or rupture and lead to ventricular arrhythmias. In addition, end-systolic triggering with high mechanical indices has been reported to cause ventricular arrhythmias following intravenous administration of a microsphere product.

Reports in biomedical literature note the development of ventricular arrhythmias and endothelial damage in association with systolic triggering or microsphere destruction at high mechanical index values.

The cardiac safety of SonoVue at mechanical indices higher than 0.8 and with the use of end-systolic triggering has not been fully established.

In a retrospective analysis of ECG recordings from patients in combined cardiac studies with SonoVue, 48/416 patients (11.5%) with validated ECGs had after administration of SonoVue prolonged QTc by 31-60 msec and 23/264 patients (5.5%) by >60 msec. In a separate analysis of validated ECG recordings from patients in two controlled cardiac studies, 9.4% (10/106) patients had a QTc prolongation >30 msec and 0.9% (1/106) >60 msec. Decreases in QTc intervals of similar magnitude were observed in a similar proportion of patients.

In a prospective study to assess the potential effect of SonoVue on ventricular repolarization in cardiac patients, ECG was monitored for up to 12 hours after administration of 0.1 mL/kg and 0.5 mL/kg of SonoVue and after placebo in 48 subjects with a documented history of coronary artery disease undergoing continuous B-mode echocardiography at mechanical index values of 0.7-0.8. The incidence of QTc interval prolongation of 30-60 msec measured by individual correction (QTcI) was in a similar range (4% to 10% of subjects) after the two doses of SonoVue and placebo. QTcI decreases of similar magnitude were observed in 4% to 29% of subjects. The clinical relevance of these changes is not known. No serious adverse events were reported in this study.

QTc prolongation may lead to an increased risk for ventricular arrhythmias including torsades de pointes. It has been observed with other drugs that prolong the QT interval that females may be at greater risk compared to males for developing torsades de pointes.

SonoVue has been shown to prolong the QT interval of the electrocardiogram in some patients. The drug should be avoided in patients with known prolongation of the QT interval, patients with hypokalemia, and patients receiving Class IA (e.g., quinidine, procainamide) or Class III (e.g., amiodarone, sotalol) antiarrhythmic agents, due to the lack of clinical experience with the drug in these patient populations and the potential risk.

Although no serious cardiac symptomatology or mortality attributable to QTc prolongation occurred in clinical trials with SonoVue, certain predisposing conditions may increase the risk for ventricular arrhythmias.

Pharmacokinetic studies between SonoVue and other drugs that prolong the QT interval such as cisapride, erythromycin, some antipsychotics, and tricyclic antidepressants have not been performed. An additive effect of SonoVue and these drugs cannot be excluded; therefore, SonoVue should be used with caution when given concurrently with these drugs.

The effect of SonoVue on patients with congenital prolongation of the QT interval has not been studied, but it is expected that these individuals may be more susceptible to drug-induced QT prolongation. Because of limited clinical experience, SonoVue should be used with extreme caution and only after careful risk/benefit assessment in patients with ongoing proarrhythmic conditions such as clinically significant bradycardia, acute myocardial ischemia, clinically relevant heart failure with reduced left ventricular ejection fraction or previous history of symptomatic arrhythmias. An ECG examination before use of SonoVue is recommended to exclude these conditions.

HEMATOLOGIC

There is limited experience with SonoVue in patients with hyperactive coagulation states and/or recent thromboembolism. SonoVue should be administered with extreme caution to patients with these conditions.

HEPATIC/BILIARY/PANCREATIC

There is limited experience with SonoVue in patients with end-stage hepatic disease. SonoVue should be administered with extreme caution to patients with this condition.

IMMUNE

During postmarketing surveillance, rare cases suggestive of hypersensitivity, which could include skin erythema, bradycardia, hypotension or anaphylactic shock, have been reported following the injection of SonoVue (see ADVERSE REACTIONS – Post-Market Adverse Drug Reactions).

NEUROLOGIC

SonoVue is not suitable for use in patients with unstable neurological disease since its safety in these conditions has not been studied.

PERI-OPERATIVE CONSIDERATIONS

Use of gas contrast agents in a diagnostic ultrasound examination is not recommended within 24 hours before extracorporeal shock wave lithotripsy.

RENAL

There is limited experience with SonoVue in patients with end-stage renal disease. SonoVue should be administered with extreme caution to patients with this condition.

RESPIRATORY

SonoVue is not suitable for use in patients with mechanical ventilation since its safety in this condition has not been studied.

There is limited experience with SonoVue in patients with severe pulmonary disease. SonoVue should be administered with extreme caution to patients with these conditions.

SPECIAL POPULATIONS

Pregnant Women: Reproduction studies have been performed in rats and rabbits at daily doses up to at least 17 times and 35 times the daily human exposure, respectively, based upon body surface area, and have revealed no evidence of impaired fertility or harm to the fetus due to SonoVue. There are, however, no adequate and well-controlled studies in pregnant women. Because animal reproduction studies are not always predictive of human response, SonoVue should be used during pregnancy only if clearly needed.

Nursing Mothers: It is not known whether this drug is excreted in human milk. Because many drugs are excreted in human milk, caution should be exercised when SonoVue is administered to a nursing woman.

Pediatrics: Safety and effectiveness in pediatric patients have not been established for use in echocardiography, nor in diagnostic assessment of vessels.

Effectiveness in pediatric patients has been established for use in ultrasonography of the excretory urinary tract for detection/exclusion of vesicoureteral reflux (see CLINICAL TRIALS – Ultrasonography of the Excretory Urinary Tract).

The safety of SonoVue intravesical administration to children in active phase of UTI has not been established.

Geriatrics: Of the total number of 1809 adult subjects in clinical studies of SonoVue, 41% were 65 and over. No overall differences in safety or effectiveness were observed between these subjects and younger subjects, and other reported clinical experience has not identified differences in responses between the elderly or younger patients, but greater sensitivity of some older individuals cannot be ruled out.

MONITORING AND LABORATORY TESTS

The patient must be monitored for 30 minutes after the examination. Electrocardiogram and blood pressure monitoring should be performed during a SonoVue-enhanced echocardiography with a pharmacological stress agent. Electrocardiogram monitoring should be also performed in high-risk patients as clinically indicated.

ADVERSE REACTIONS

ADVERSE DRUG REACTION OVERVIEW

In clinical trials, 1809 patients received SonoVue, of which 323 (17.9%) patients reported at least one adverse event. Serious adverse events were reported for 11 (0.6%) patients. All serious adverse events except one (sensory motor paresis of the arm; unknown relationship to SonoVue administration) were considered to be unrelated to SonoVue administration. The most frequently reported adverse events regardless of causality and dose were headache (39/1809; 2.2%), nausea (26/1809; 1.4%), and injection site pain (19/1809; 1.1%). All other adverse events were reported in less than 1% of patients. The majority of adverse events were mild in intensity and resolved without sequelae. A total of 5 (0.3%) patients discontinued due to adverse events, 3 of whom had adverse events considered to be unrelated to SonoVue administration, and 2 of whom had adverse events considered to be of possible or doubtful relation to SonoVue administration.

During postmarketing surveillance, rare cases suggestive of hypersensitivity, which could include skin erythema, bradycardia, hypotension, dyspnea, loss of consciousness, cardiac/cardio-respiratory arrest, or anaphylactic shock have been reported following the injection of SonoVue. In some of these cases, mostly in patients with underlying coronary artery disease, myocardial ischemia and/or myocardial infarctions were also reported.

CLINICAL TRIAL ADVERSE DRUG REACTIONS

Because clinical trials are conducted under very specific conditions, the adverse drug reaction rates observed in the clinical trials may not reflect the rates observed in practice and should not be compared to the rates in the clinical trials of another drug. Adverse drug reaction information from clinical trials is useful for identifying drug-related adverse events and for approximating rates.

SonoVue was studied in clinical trials involving 1809 adult subjects (122 healthy volunteers and 1687 patients). SonoVue was studied primarily in trials in adults during which no control was administered (n=1581 subjects). SonoVue was also studied in controlled trials with an active-control and/or a saline control arm (n=228 subjects). There were 1159 (64%) men and 650 (35.9%) women with a mean age of 59.0 years (range: 19 to 96 years). A total of 1653 (91.4%) subjects were Caucasian, 69 (3.8%) Black, 67 (3.7%) Asian, 10 (0.6%) Hispanic, and 9 (0.5%) other racial or ethnic groups.

Of the 1809 subjects who participated in clinical trials, 799 were patients with cardiac conditions, 450 were patients with vascular abnormalities; 400 were patients with parenchymal benign or malignant lesions, 38 were patients who participated in special population clinical pharmacology studies (13 subjects with NYHA Class II-IV congestive heart failure; 12 subjects with chronic obstructive pulmonary disease; 13 subjects with diffuse interstitial pulmonary fibrosis), and 122 were healthy volunteers. Most patients received multiple bolus doses of SonoVue in cross-over studies with a mean cumulative dose of 7.16 mL (range: 0.2-70.5 mL).

Table 1 lists adverse events that occurred regardless of causality and dose in at least 1.0% of 1809 adult subjects, in decreasing order of occurrence within each system organ class. The incidence for patients in all cardiac studies, all vascular studies, and a subgroup of patients enrolled in controlled cardiac trials are shown for purposes of comparison.

The overall incidence of adverse events in clinical studies was 17.9% (323/1809). The overall adverse event incidence rate for patients in cardiac studies and vascular studies were similar. The incidence of adverse events following administration of SonoVue in the cardiac studies was 19.4% (155/799). In controlled (parallel group) cardiac studies, the incidence of adverse events was lower for the SonoVue group (22/138; 15.9%) than for the control group (approved comparator/saline: 33/126; 26.2%). The incidence of adverse events for the vascular studies was 16.7% (75/450).

TABLE 1

ADVERSE EVENTS REPORTED BY ≥1.0% OF SUBJECTS WHO RECEIVED SONOVUE IN CLINICAL TRIALS

MEDDRA SYSTEM ORGAN CLASS/PREFERRED TERM	No. (%) of Subjects				
	ALL SUBJECTS	CARDIAC STUDIES	CONTROLLED CARDIAC STUDIES		VASCULAR STUDIES
	SonoVue	SonoVue	SonoVue	Controlled	SonoVue
Number of subjects who received study agent	1809[a]	799	138[b]	126[c]	450
Number of subjects with any adverse event	323 (17.9)	155 (19.4)	22 (15.9)	33 (26.2)	75 (16.7)
Gastrointestinal disorders					
Nausea	26 (1.4)	18 (2.3)	3 (2.2)	0	3 (0.7)
General disorders and administration site conditions					
Injection site pain	19 (1.1)	2 (0.3)	0	0	6 (1.3)
Nervous system disorders					
Headache	39 (2.2)	17 (2.1)	2 (1.4)	6 (4.8)	11 (2.4)

a All patients and healthy volunteers who received SonoVue only or SonoVue plus control agent.
b 0.5, 1, 2 and 4 mL
c Approved comparator (0.08 and 0.22 mL/kg) and saline (0.08 and 0.22 mL/kg)

LESS COMMON CLINICAL TRIAL ADVERSE DRUG REACTIONS

Adverse events that occurred in <1.0% of study subjects included:

Blood and lymphatic system disorders: eosinophilia.

Cardiac disorders: angina pectoris, arrhythmia, atrial fibrillation, atrial flutter, bradycardia, bundle branch block left, cardiac failure, cardiac failure congestive, supraventricular extrasystoles, supraventricular tachycardia, ventricular extrasystoles, ventricular tachycardia.

Ear and labyrinth disorders: deafness, vertigo.

Eye disorders: Eye irritation, lacrimation increased, vision blurred, vitreous floaters.

Gastrointestinal disorders: abdominal discomfort, abdominal pain, abdominal pain upper, diarrhea, dry mouth, dyspepsia, hypoaesthesia oral, proctalgia, salivary hypersecretion, stomach discomfort, vomiting.

General disorders and administration site conditions: application site bruising, application site erythema, application site irritation, application site pain, application site paraesthesia, application site pruritus, asthenia, chest discomfort, chest pain, chills, discomfort, fatigue, feeling abnormal, feeling cold, feeling hot, hunger, influenza-like illness, injection site coldness, injection site discomfort, injection site haemorrhage, injection site irritation, injection site paraesthesia, injection site reaction, injection site swelling, injection site warmth, malaise, oedema peripheral, pain, pyrexia, thirst.

Hepatobiliary disorders: hepatic pain.

Immune system disorders: hypersensitivity, anaphylaxis.

Infections and infestations: bronchitis, nasopharyngitis, sinusitis, upper respiratory tract infection, urinary tract infection.

Injury, poisoning and procedural complications: contusion, fall.

Investigations: activated partial thromboplastin time prolonged, alanine aminotransferase increased, aspartate aminotransferase increased, blood albumin decreased, blood bilirubin increased, blood creatinine increased, blood glucose increased, blood pressure diastolic increased, blood pressure increased, blood pressure systolic increased, blood urea increased, blood uric acid increased, electrocardiogram ST segment depression, electrocardiogram ST segment elevation, eosinophil count increased, gamma-glutamyltransferase increased, glucose urine present, lymphocyte count decreased, lymphocyte count increased, monocyte count increased, neutrophil count decreased, neutrophil count increased, platelet count decreased, platelet count increased, protein total decreased, specific gravity urine increased, white blood cell count decreased, white blood cell count increased.

Metabolism and nutrition disorders: hyperglycaemia, hypoglycaemia.

Musculoskeletal and connective tissue disorders: arthralgia, back pain, chest wall pain, limb discomfort, muscle tightness, musculoskeletal chest pain, musculoskeletal discomfort, neck pain, pain in extremity, sensation of heaviness, trismus.

Neoplasms benign, malignant and unspecified (incl cysts and polyps): hepatic neoplasm malignant, metastatic neoplasm.

Nervous system disorders: burning sensation, diabetic neuropathy, dizziness, dysgeusia, hemiparesis, hypoaesthesia, lethargy, migraine, myoclonus, paraesthesia, paraesthesia oral, paresis, parosmia, sinus headache, somnolence, tension headache, tremor.

Psychiatric disorders: anxiety, depressed mood, insomnia, logorrhoea, restlessness.

Renal and urinary disorders: haematuria, ketonuria, nephrolithiasis, proteinuria, renal failure.

Reproductive system and breast disorders: breast pain.

Respiratory, thoracic and mediastinal disorders: breath sounds decreased, cough, dry throat, dyspnoea, hyperventilation, lung infiltration, nasal congestion, pharyngolaryngeal pain, rhinitis allergic, rhinorrhoea, throat irritation, throat tightness.

Skin and subcutaneous tissue disorders: dermatitis allergic, dry skin, erythema, exanthem, hyperhidrosis, petechiae, pruritus, rash, rash macular.

Vascular disorders: circulatory collapse, diastolic hypertension, flushing, haemorrhage, hypertension, hypotension, peripheral coldness, thrombophlebitis.

No relationship between adverse events and dose, age, sex, formulation, or concomitant medications was observed. The incidence of adverse events in patients with cardiac conditions, vascular abnormalities, benign or malignant lesions, congestive heart failure, chronic obstructive pulmonary disease, and diffuse interstitial pulmonary fibrosis was similar to that seen in healthy volunteers involved in clinical trials with SonoVue.

In general, the adverse events were non-serious, transient and resolved spontaneously without residual effect.

Serious adverse events, including 6 deaths, were reported in 11 patients who received SonoVue. All of these events, except a case of sensory-motor paresis, were considered not to be related to the study agent.

Isolated changes in ECG and blood pressure were reported but these were not considered to be of clinical significance.

ABNORMAL HEMATOLOGICAL AND CLINICAL CHEMISTRY FINDINGS IN CLINICAL TRIALS

Isolated changes in some laboratory parameters were reported in clinical trials but these were not considered to be of clinical significance.

ASSESSMENT OF SONOVUE SAFETY AFTER INTRAVESICAL ADMINISTRATION IN PEDIATRIC PATIENTS

Safety of intravesical use of SonoVue was based on evaluation of 12 published studies involving use of SonoVue in over 6000 pediatric patients; the age range of patients in the studies was 2 days to 18 years. Overall, among the 12 publications, non-serious minor adverse events were reported in 37 patients. None of the reported adverse events were considered related to SonoVue, but instead were considered related to the catheterization procedure during VUS. All events were reported in one study of 1010 children. In this single study, adverse events were reported in 19 males (mean age: 2.8 years, range: 1 month-8.6 years) and 18 females (mean age: 3.4 years, range: 1 month - 8.9 years), or 3.7% of the study population. Dysuria was the most frequently reported symptom, in 26 children. Other reported adverse events included abdominal pain (n=2), anxiety (n=1) and crying (n=1) during micturition, blood and mucous discharge (n=1), increased frequency of micturition (n=1), vomiting (n=1), perineal irritation (n=1), and urinary tract infection 10 days after VUS (n=1). Of the 37 adverse events, 91.9% occurred between 2 and 24 hours after the ultrasound procedure. All reported events were self-limiting and none required hospitalization.

POST-MARKET ADVERSE DRUG REACTIONS

During postmarketing surveillance, rare cases suggestive of hypersensitivity, which could include skin erythema, bradycardia, hypotension, dyspnea, loss of consciousness, Cardiac/cardio-respiratory arrest or anaphylactic shock, have been reported following the injection of SonoVue. In some of these cases, mostly in patients with underlying coronary artery disease, myocardial ischemia and/or myocardial infarctions were also reported.

In very rare cases, fatal outcomes have been reported in temporal association with the use of SonoVue. Most of these patients had a high underlying risk for major cardiac complications, which could have led to the fatal outcome.

DRUG INTERACTIONS

OVERVIEW

No specific interaction studies have been performed in humans.

Drug interaction studies performed in animals did not detect interactions with drugs studied.

DRUG-DRUG INTERACTIONS

Interactions with other drugs have not been established.

There was no apparent relationship with respect to occurrence of adverse events in the clinical studies for patients receiving various categories of the most common concomitant medications (i.e., antihypertensive and anticoagulants). Use of SonoVue with concomitant medications known to cause prolonged QT interval should be done with extreme caution.

Patients who experience hypersensitivity reactions while taking a beta blocker may be resistant to emergency medication.

Potential pharmacokinetic drug-drug interactions with SonoVue have not been assessed.

Pharmacokinetic studies between SonoVue and other drugs that prolong the QT interval such as cisapride, erythromycin, some antipsychotics, and tricyclic antidepressants have not been performed. An additive effect of SonoVue and these drugs cannot be excluded; therefore, SonoVue should be used with caution when given concurrently with these drugs.

Studies in a hypertensive rat model showed that SonoVue does not interact with a series of antihypertensive drugs such as captopril, propranolol and nifedipine. Other animal studies showed that it does not interact either with anticoagulant activity of heparin, and with the cardiovascular effects of isosorbide dinitrate and of digoxin. There was also no effect of SonoVue on the antiplatelet effect of acetylsalicylic acid in rats (See DETAILED PHARMACOLOGY).

DRUG-FOOD INTERACTIONS

Interactions with food have not been established.

DRUG-HERB INTERACTIONS

Interactions with herbal products have not been established.

DRUG-LABORATORY TEST INTERACTIONS

Interactions with laboratory tests have not been established.

DOSAGE AND ADMINISTRATION

Endocardial Border Delineation: The recommended dose of SonoVue for visualization of cardiac chambers and endocardial borders delineation is 2 mL administered as an intravenous bolus injection during echocardiography performed at rest or stress. The recommended rate of administration of the injection is 2 mL over a period of 1 second. During a single examination, a second injection of 2 mL may be administered when deemed necessary by the physician.

Diagnostic Assessment of Vessels: The recommended dose of SonoVue for diagnostic assessment of vessels is 1.2 mL administered as an intravenous bolus injection during Doppler ultrasound. The recommended rate of administration of the injection is 1.2 mL over a period of 1 second; however, for transcranial Doppler a slower injection rate of 1.2 mL over 2-3 seconds is recommended to reduce blooming artifacts. During a single examination, a second injection of 1.2 mL may be administered when deemed necessary by the physician.

Each injection described above should be followed immediately by an intravenous bolus injection flush of 5 mL of sodium chloride injection (0.9%) w/v, which is intended to enhance the imaging process. As the SonoVue kit does not provide a second syringe of sodium chloride injection 0.9% for this flush, the user must have this immediately available from another source.

Ultrasonography of the Excretory Urinary Tract: The recommended dose of SonoVue for ultrasonography of the excretory urinary tract is 1 mL of reconstituted solution by intravesical administration. Introduce a sterile 6F-8F urinary catheter into the bladder under sterile conditions. Empty the bladder of urine, and then fill the bladder with saline (normal sterile 0.9% sodium chloride solution) to approximately one third or half of its predicted total volume [(age in years + 2) x 30] mL. Inject the SonoVue dose and then continue filling the bladder with saline until the patient has the urge to micturate or there is the first slight sign of back pressure to the infusion. Immediately following the first voiding, the bladder may be refilled with normal saline for a second cycle of voiding and imaging, without the need of a second SonoVue administration.

ADMINISTRATION

RECONSTITUTION

Prior to administration, SonoVue for Injection should be reconstituted with 5 mL of sterile sodium chloride injection (0.9%) to give a final concentration of 8µL/mL of sulfur hexafluoride microbubbles. After adding the sodium chloride solution, the vial should be shaken vigorously for twenty seconds after which the desired volume of the product is withdrawn into a syringe for administration to the patient. As the SonoVue kit does not provide a second syringe of sodium chloride injection 0.9%, intended for the intravenous flush following injection of SonoVue, the user must have this immediately available from another source.

The method of reconstitution of the lyophilized product is as follows:

1. Connect the plunger rod by screwing it clockwise into the syringe.
2. Open Mini-Spike Plus 6/8R blister and remove syringe tip cap.
3. Open transfer system cap and connect the syringe to the transfer system by screwing it in clockwise.
4. Remove Flip Cap plastic protective disk from the vial. Slide the vial into the transparent sleeve of the transfer system and press firmly to lock the vial in place.
5. Empty the contents of the syringe into the vial by pushing on the plunger rod.
6. Shake vigorously for 20 seconds to mix all the contents in the vial (white milky liquid).
7. Invert the system and carefully withdraw SonoVue into the syringe.
8. Unscrew the syringe from the transfer system.

Single dose product. As with all parenteral drug products, syringes should be inspected visually for clarity, particulate matter, precipitate, discoloration and leakage prior to administration whenever solution and container permit. Solutions showing haziness, particulate matter, precipitate, discoloration or leakage should not be used. Following reconstitution of the lyophilisate and prior to injecting the product, it is mandatory to inspect the suspension to make sure that a homogeneous white milky liquid has been obtained. Discard the product if the suspension is not white, not milky, not homogeneous and/or if solid parts of the lyophilisate are seen in the suspension. Reconstituted product should be used within 6 hours. Discard unused portion.

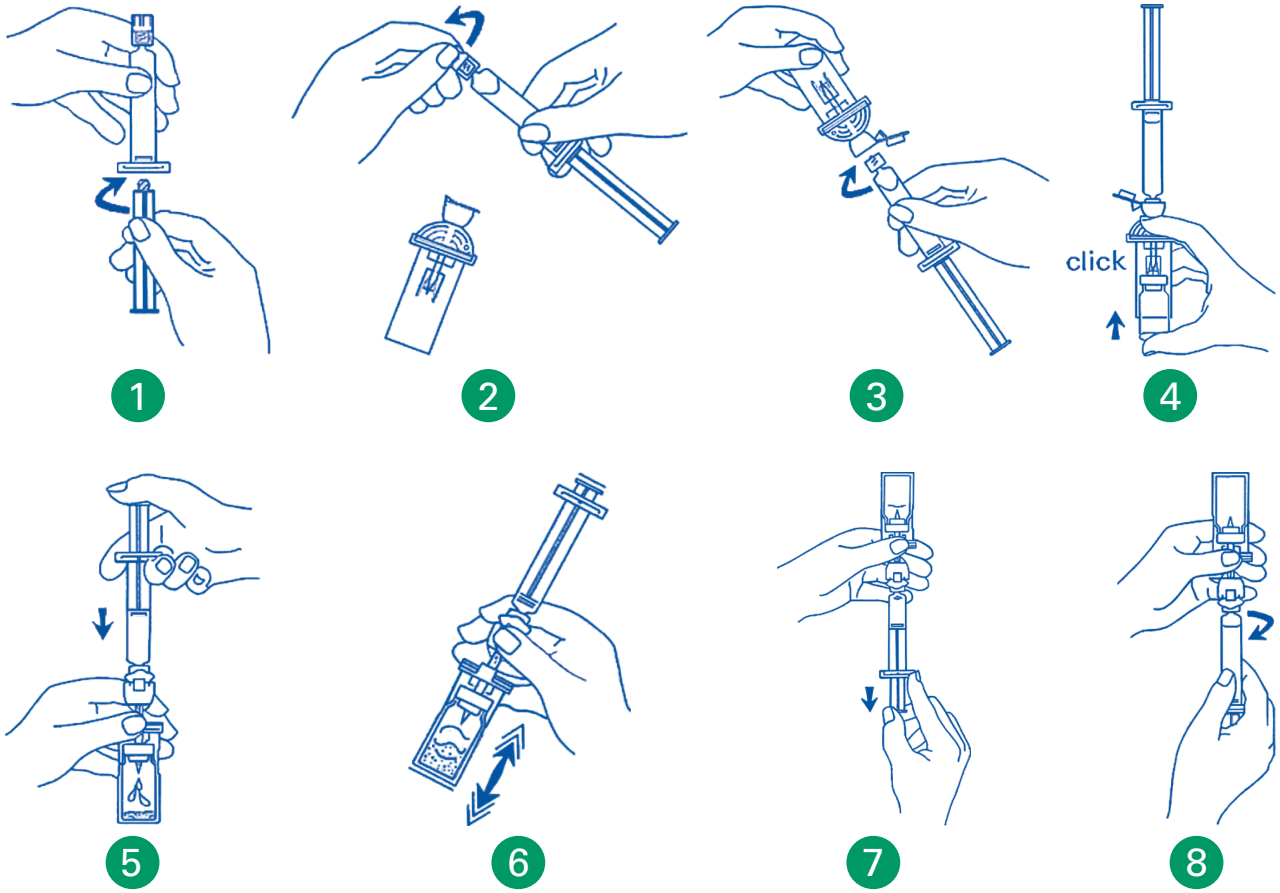

OVERDOSAGE

No clinical signs or symptoms of overdosage with SonoVue have been reported to date.

Repeated bolus doses of up to 52 mL of SonoVue (3 successive injections over 60 minutes) were administered to healthy volunteers in a safety study without any serious adverse events. For the 1776 subjects who received SonoVue 5 mg/mL, the mean cumulative dose was 7.16 mL (range: 0.2 to 70.5 mL). Eighty-five percent of subjects received cumulative doses ranging from >1 to 10 mL.

In the event of overdosage, treatment is directed toward the support of all vital functions, and prompt institution of symptomatic therapy.

ACTION AND CLINICAL PHARMACOLOGY

MECHANISM OF ACTION

SonoVue is a stabilised microbubble preparation for diagnostic use with ultrasound imaging to enhance the echogenicity of the blood, which results in an improved signal-to-noise ratio.

For ultrasonography of the urinary tract in pediatric patients, intravesically administered SonoVue increases the signal intensity of fluids within the urethra, bladder, ureters, and renal pelvis.

PHARMACODYNAMICS

The acoustic impedance of the SonoVue microbubble gas is much lower than that of the surrounding aqueous medium. Therefore, the interface between the SF_6 bubble and the aqueous medium acts as a reflector of the ultrasound beam. The ultrasound waves that are scattered and reflected at the microbubble-blood interface are ultimately visualized in the ultrasound image and result in an increased contrast between the blood and the surrounding tissues.

In clinical studies, a bolus injection of the recommended dose of SonoVue has been shown to provide marked increase in signal intensity of more than 2 minutes for B-mode imaging in echocardiography and of 3 to 8 minutes for Doppler imaging of the vessels.

In ultrasonography of the urinary tract, SonoVue facilitates the detection of reflux of fluid from the bladder into the ureters.

PHARMACOKINETICS

Studies in humans have evaluated the pharmacokinetics of the gas sulfur hexafluoride [SF_6], the active component in SonoVue microbubbles. SF_6 dissolves in the blood and is subsequently exhaled.

Twelve healthy adult volunteers (7 men and 5 women) received a single intravenous bolus injection of 0.03 mL/kg and 0.3 mL/kg of SonoVue, corresponding to approximately 1 and 10 times the recommended doses for diagnostic use. Concentrations of SF_6 in blood peaked within 1 to 2 minutes following intravenous injection of both doses of SonoVue and then declined very rapidly. The terminal half-life of SF_6 in blood averaged approximately 10 minutes for the 0.3 mL/kg dose (at the 0.03 mL/kg dose it was not measurable). The estimated area under the curve ($AUC_{(0\text{-}60\ min)}$) of SF_6 was dose-proportional.

Absorption: Not applicable for an intravenous dosage form.

Distribution: In healthy volunteers, mean values for the apparent steady-state volume of distribution of SF_6 were 341 L and 710 L for SonoVue doses of 0.03 mL/kg and 0.3 mL/kg, respectively. These values are likely to exceed the true volume of distribution because of the influence of first-pass extraction by the lungs (see Excretion).

The binding of SF_6 to plasma proteins and the partitioning into blood cells have not been studied.

Metabolism: SF_6 does not undergo biotransformation.

Excretion: The SF_6 contained in SonoVue is eliminated via the lung. Twenty minutes following injection, the mean cumulative recovery of SF_6 in expired air was 82±20% (SD) at the 0.03 mL/kg dose and 88±26% (SD) at the 0.3 mL/kg dose.

SF_6 undergoes a substantial degree of first pass elimination within the pulmonary circulation; approximately 40-50% of the SF_6 content was eliminated in the expired air during the first minute following SonoVue injection. At 11 minutes post-dose, approximately 80-90% of the SF_6 content was eliminated. Data on the time or rate of final clearance of intact microbubbles are not available.

SPECIAL POPULATIONS AND CONDITIONS

Pulmonary Impairment: In patients with mild-to-moderate pulmonary impairment, blood concentrations of SF_6 peaked at 1 to 4 minutes following administration of SonoVue. The cumulative recovery of SF_6 in expired air was 102±18% (mean±SD), and the terminal half-life of SF_6 in blood was similar to that measured in healthy volunteers. It would appear that dose adjustment may not be necessary in this type of patients. Pharmacokinetics of SonoVue in patients with chronic obstructive pulmonary disease has not been studied (See DETAILED PHARMACOLOGY).

Renal or Hepatic Impairment: Because SF_6 is eliminated via the lungs, no studies of SF_6 pharmacokinetics were performed in patients with renal or hepatic impairment. Negligible amounts of SF_6 were recovered in the urine of rabbits injected with 0.3 or 1.0 mL/kg of SonoVue.

Pediatrics: The pharmacokinetics of SF_6 was not studied in pediatric patients.

Geriatrics: The effect of age group (i.e., geriatrics) on the pharmacokinetics of SF_6 has not been studied.

Gender: No consistent or clinically relevant differences in pharmacokinetic parameters have been observed between men and women.

Race: The effect of race on pharmacokinetics of SF_6 has not been studied.

STORAGE AND STABILITY

Store the kit before and after reconstitution at 15-25°C. Once reconstituted, the suspension should be used within 6 hours.

DOSAGE FORMS, COMPOSITION AND PACKAGING

SonoVue for Injection is supplied in a kit consisting of a clear glass vial containing 25 mg of lyophilized powder sealed under sulfur hexafluoride gas and capped with Flip Cap closure, a Mini-Spike Plus 6/8R transfer system and a 5-mL prefilled syringe containing sterile 0.9% sodium chloride solution for reconstitution. Five kits are packaged per carton.

The headspace of the vial is filled with sulfur hexafluoride (SF_6), approximately 58 mg. When reconstituted with 5 mL sodium chloride solution 0.9% (w/v), the resulting suspension contains approximately 48 µg/mL sulfur hexafluoride.

DOSAGE FORM NON-MEDICINAL INGREDIENTS:

Each vial of reconstituted lyophilized powder contains:

- dipalmitoylphosphatidylglycerol (DPPG.Na) - 0.19 mg
- distearoylphosphatidylcholine (DSPC) - 0.19 mg
- palmitic acid - 0.04 mg
- polyethylene glycol - 24.56 mg
- sodium chloride (0.9% solution for reconstitution) - 5 mL

PART II

SCIENTIFIC INFORMATION

PHARMACEUTICAL INFORMATION

	DRUG SUBSTANCE
TRADE NAME	SonoVue
COMMON NAME	sulfur hexafluoride
CHEMICAL NAME	sulfur hexafluoride
STRUCTURAL FORMULA	Sulfur hexafluoride is an octahedral structure, with Oh point symmetry and a symmetry number of 24. The S-F bond length is 1.564_ and the F-S-F bond angle is 90°

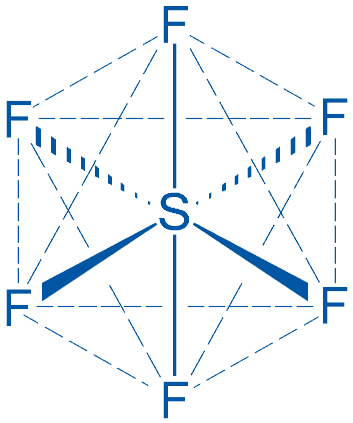

MOLECULAR FORMULA	SF_6
MOLECULAR MASS	146.05
PROPERTIES	Colourless odourless gas, approximately 5 times heavier than air. Chemically stable, sparingly soluble in water, somewhat more in alcohol. Sublimes at (-63.8°C).

CLINICAL TRIALS

Endocardial Border Delineation

STUDY DEMOGRAPHICS AND TRIAL DESIGN

SonoVue (sulfur hexafluoride) was studied in 3 multicenter controlled clinical studies in a total of 317 patients with highly suspected cardiac disease requiring 2D transthoracic echocardiography. Two of these studies were identical in design, with subjects receiving either SonoVue (138 patients) or a comparator (a contrast agent approved at the time the studies were conducted or saline, 126 patients) in a parallel-group design. The third study was a crossover design during which 53 patients received SonoVue and a comparator (a contrast agent approved at the time the studies were conducted). Of these 317 patients, SonoVue was administered to 191 patients (127 men and 64 women) with a mean age of 58.5 years (range 22 to 96 years). The racial and ethnic representations were 79.1% Caucasian, 16.2% Black, 3.7% Hispanic, 0.5 % Asian, and 0.5% other racial or ethnic groups. The mean weight was 204.4 lbs (range 92.4 to 404.8 lbs). Approximately 20% of the patients had a chronic pulmonary disorder and 30% had a history of previous heart failure. Of the 106 patients for which a NYHA (New York Heart Association) classification of heart failure was assigned, 49% were Class I, 33% were Class II, and 18% were Class III. Patients with NYHA Class IV heart failure were not included in these studies. For the 53 patients in the third controlled study, 30% of the patients had an ejection fraction less than 40%. The demographics and baseline characteristics were similar for the patients who received a comparator in these studies.

In two studies, patients randomly received intravenous bolus injections of all four doses of SonoVue, 0.5, 1, 2, and 4 mL, or two doses of the approved comparator and two doses of agitated saline. In the third study, each patient randomly received two doses of SonoVue (1 mL and 2 mL) and one dose of the approved comparator. A recording of 2D echocardiography was obtained from 30 seconds prior to each injection of study agent (baseline) to at least 15 minutes after dosing or until the disappearance of the contrast effect (return to baseline), whichever was longer. Preinjection and postinjection echocardiographic images for each patient were evaluated by two independent echocardiographers. The independent readers were blinded to patient identity, other patient information, and study agent. Left ventricular (LV) endocardial border delineation was evaluated for two apical views (2- and 4-chamber divided into 6 segments each) on a 3-point scale (0=inadequate, 1=sufficient, 2=good), with a total possible score of 24.

STUDY RESULTS

In all three studies, administration of SonoVue resulted in statistically significant improvements in left ventricular endocardial border delineation scores compared to baseline with optimal increases observed at the 2.0 mL dose of SonoVue (see Table 2). These increases were significantly greater for SonoVue than for the active control. Additionally, the majority of the patients who received a 2.0 mL dose of SonoVue had clinically significant increases (>4; visualization of at least two additional segments) in endocardial border delineation score (Table 2).

TABLE 2

TOTAL LEFT VENTRICULAR ENDOCARDIAL BORDER DELINEATION SCORE[a] 2.0-ML DOSE OF SONOVUE

	N	Baseline Mean	Mean Change (SD) From Baseline	Patients With Increase ≥4[b]
STUDY A				
Reader 1	76	7.5	7.0 (5.15)*	67.1%
Reader 2	76	7.6	9.6 (5.13)*	88.2%
STUDY B				
Reader 3	62	9.0	5.1 (4.08)*	56.5%
Reader 4	62	4.6	17.2 (6.08)*	95.2%
STUDY C				
Reader 5	53	11.9	3.6 (4.47)*	41.5%
Reader 6	53	6.7	4.5 (3.96)*	62.3%

a Total score is the sum of the scores of the apical 4-chamber view and apical 2-chamber view. Each view consists of 6 segments. Scores for each segment are as follows:
0 = Inadequate (border not visible);
+ 1 = Sufficient (border barely visible);
+ 2 = Good (border clearly visible).

* $p<0.001$ based on t-test.

b Clinically significant increase in score (≥4; visualization of at least two additional segments).

This improvement in endocardial border delineation score resulted in a marked reduction in the percentage of patients with inadequate border delineation in at least one segment. Furthermore, moderate or complete left ventricle opacification was observed in up to 80% of the patients following administration of a 2.0-mL dose of SonoVue. The mean duration of useful contrast effect ranged from 1.7 to 3.1 minutes (i.e., from the first useful appearance of contrast within the left ventricle, moderate or complete opacification, until the useful effect had ended).

The relationship between improved endocardial border delineation and quantitative indices of left ventricular function was evaluated for the 53 patients in the third controlled study. To evaluate the relationship to quantitative assessment of global ventricular function, preinjection and postinjection ejection fractions were determined and compared to the outcome of a radionuclide ventriculogram (reference standard). At the 2.0-mL dose, the correlation coefficient between echocardiographic assessment and radionuclide ventriculography based on reader=s global assessment increased from 0.66 following non-contrast echocardiography to 0.76 following the administration of SonoVue, however, the difference was not statistically significant.

As the visualization of endocardial borders has clinical importance during rest and stress echocardiography, an additional multicenter parallel-group study was conducted in 211 patients with known or suspected cardiac disease. In this study, patients received 0.5, 1.0, 2.0, or 4.0 mL of SonoVue during transthoracic echocardiography at rest and during peak pharmacological stress. Endocardial border delineation was evaluated for two apical views (2- and 4-chamber divided into 6 segments each) on a 3-point scale (0 = inadequate, 1 = sufficient, 2 = good), with a maximum possible score of 24. Significant increases from baseline (based on an ANCOVA model) in total apical view score were observed at rest and during pharmacological stress. At the 2.0-mL dose of SonoVue, mean values for the increases from baseline in endocardial border delineation scores were 4.2 at rest and 4.8 during pharmacological stress (consistent with visualization of at least two additional segments).

Diagnostic Assessment of Vessels

STUDY DEMOGRAPHICS AND TRIAL DESIGN

SonoVue was studied in two identical multicenter, baseline-controlled crossover design studies in a total 361 patients with suspected pathology and who did not have a fully diagnostic unenhanced Doppler examination of cerebral artery, extracranial carotid or peripheral arteries, abdominal or renal arteries, or portal circulation. Of these 361 patients, 358 patients (222 men and 136 women) with a mean age of 61.7 years (range 22 to 88) were included in the efficacy analysis of SonoVue.

The racial and ethnic representations were 94.1% Caucasian, 2.8% Asian, 2.5% Black, and 0.6% other racial or ethnic groups. Of the 358 patients, 113 patients had Doppler ultrasound investigations for cerebral arteries, 81 for extracranial or peripheral arteries, 80 for abdominal or renal arteries, and 84 for portal circulation.

Four intravenous bolus injections of SonoVue (0.3, 0.6, 1.2, and 2.4 mL) were administered to each patient according to a randomized dose sequence. Doppler investigations of the designated vessel were performed at baseline and after each injection of SonoVue, with videotape recording of images beginning 30 seconds prior to injection and continuing until the end of the contrast effect. At each timepoint, the designated vessel was studied first with either colour Doppler or power Doppler (only one mode was used for a patient), and then with spectral Doppler imaging. All SonoVue administration and imaging procedures were completed on the same day. Assessment of Doppler images was performed by 2 independent readers for each anatomical area. The readers were blinded as to patient identity, clinical history, timepoint, and dose. The images were rated on a global 4-point scale (0=very poor, 1=some, 2=adequate, 3=excellent) relating to the quality of the visualization of blood flow within the vessel. For patients with a reference imaging modality available from which a diagnosis could be made (i.e., angiography, magnetic resonance angiography, or computed tomography angiography), a committee of three independent physicians (Accuracy Review Committee) compared the diagnosis obtained with Doppler images with the diagnosis obtained with the reference modality. The portal circulation was excluded from these analyses since Doppler ultrasound was considered the standard reference modality.

STUDY RESULTS

Administration of SonoVue resulted in significant increases from baseline in global quality of Doppler investigation score, with 31% to 86% of the patients having an improved score with the 1.2 mL or 2.4 mL dose (across readers and vascular territories). The mean duration of useful signal enhancement for the 1.2 mL or 2.4 mL dose ranged from 1.9 to 6.3 minutes for cerebral arteries, from 2.7 to 6.2 minutes for extracranial carotid or peripheral arteries, from 3.0 to 8.6 minutes for abdominal and renal arteries and from 3.2 to 5.3 minutes for portal vein.

For the subgroup of 192 patients who had an appropriate reference imaging modality available, the agreement between Doppler diagnosis and diagnosis from the reference imaging modality was significantly greater for SonoVue-enhanced images compared to unenhanced images in cerebral, extracranial carotid or peripheral arteries but not in abdominal or renal arteries (Table 3).

TABLE 3

AGREEMENT[a] BETWEEN DIAGNOSIS FROM SONOVUE-ENHANCED DOPPLER INVESTIGATION AND DIAGNOSIS FROM REFERENCE MODALITY[b] 2.4-ML DOSE OF SONOVUE

	% of Patients			
	STUDY A		STUDY B	
CEREBRAL ARTERIES				
	Reader 1	Reader 2	Reader 3	Reader 4
	N=61		N=17	
Baseline	8.2%	24.6%	11.8%	11.8%
SonoVue	67.2%*	67.2%*	41.2%*	47.1%*
EXTRACRANIAL CAROTID OR PERIPHERAL ARTERIES				
	Reader 5	Reader 6	Reader 7	Reader 8
	N=32		N=27	
Baseline	6.3%	31.3%	55.6%	29.6%
SonoVue	71.9%*	59.4%*	70.4%	74.1%*
ABDOMINAL OR RENAL ARTERIES				
	Reader 9	Reader 10	Reader 11	Reader 12
	N=36		N=19	
Baseline	41.7%	36.1%	21.1%	42.1%
SonoVue	47.2%	55.6%	21.1%	47.4%

The readers were different for each studay and for each territory.
a Full and basic.
b angiography, magnetic resonance angiography, or computed tomography angiography.
* $p<0.05$ based on change from baseline in agreement rate using McNemar's test

In portal circulation, SonoVue increased the diagnostic confidence scores and the percentage of patients with diagnosis possible when this percentage was low at baseline examination.

In clinical trials with SonoVue, there was a small number of patients (13 or 2%) with exceptionally long duration of contrast enhancement (34 min, to over 4 hours). Seven of these patients were enrolled in a rechallenge study, in which 6 of them again demonstrated a prolonged retention of SonoVue in the portal circulation. The reason for this is not clear and no pharmacokinetic data was available for these patients. However, prolongation of contrast did not appear to be associated with adverse events in these patients.

In a study using B-mode examination of extracranial carotid artery including 89 patients, SonoVue did not improve the extent of delineation of the artery. SonoVue may not be useful in this mode of examination of macrovasculature.

ASSESSMENT OF VESICOURETERAL REFLUX

In 4 published studies, 508 pediatric patients referred for assessment of vesicoureteral reflux (275 males, 233 female, age range: 2 days to 13 years) were evaluated after intravesical administration of 1.0 mL of SonoVue.

The findings of SonoVue ultrasound images were compared to voiding cystourethrography as the truth standard. In these studies, the sensitivity of SonoVue enhanced ultrasonography for detecting vesicoureteral reflux ranged from 80% to 100%, while the specificity ranged from 77% to 86%.

A meta-analysis based on the same four studies (508 patients, 1,023 ureter units) resulted in pooled sensitivity of 89% (95% CI: 80% to 97%) and pooled specificity of 81% (95% CI: 76% to 86%).

DETAILED PHARMACOLOGY

MECHANISM OF ACTION, PHARMACODYNAMICS

IN VITRO DATA

The echogenic characteristics, backscatter and attenuation coefficients, of the SonoVue microbubbles were measured *in vitro* over the whole medical range, i.e. from 2 to 10 MHz. The maximum attenuation and backscatter was found to extend over a wide range of frequencies between 4 and 9 MHz and is centred around 4-4.5 MHz thus indicating that a majority of microbubbles resonate in this frequency range. As the variations of the backscatter coefficient and of the attenuation are not very important in the 2-10 MHz range, the acoustic properties of SonoVue can be considered as being essentially constant over the entire medical range.

The resistance to pressure of SonoVue preparations was evaluated *in vitro*. The method involves the measurement of the absorbency at 700 nm of the preparation while applying a gradually increasing pressure to the preparation. The critical Pc (corresponding to the pressure at which the absorbency decreased by 50%) was evaluated. Typical Pc values for SonoVue are higher than 100 mm Hg. Under the same condition, sonicated albumin preparations provide values of 60 mm Hg, indicating a much lower resistance to pressure. Imaging experiments in animals showed that preparations with Pc<80 mm Hg will hardly be able to increase the echo signal in the left ventricle.

IN VIVO DATA

HUMAN DATA: PHARMACODYNAMICS

Imaging Studies

A Phase I/II, single-center, open-label, randomized, crossover study was conducted to evaluate the efficacy of SonoVue in enhancing the Doppler signal (power Doppler or spectral pulsed wave Doppler) and in increasing the signal-to-noise ratio in hepatic and renal vessels and to evaluate the quality and duration of the contrast effect. Eleven healthy male subjects were enrolled, of which one discontinued after completion of the first test session due to a non-serious adverse event (mild nausea, vomiting and diarrhea) considered by the investigator to be of doubtful relationship to SonoVue and likely due to a viral infection (n=10 included in analysis). Administration of SonoVue (0.15, 0.3, 0.6, and 1.2 mL) during Doppler investigation of the renal arteries produced a dose-related increase in image quality and duration of signal enhancement. All four doses of SonoVue administered during Doppler investigation of portal vein (0.6, 1.2, 2.4, and 4.8 mL) were equally effective in enhancing the quality of the Doppler spectrum, suggesting that maximum enhancement was obtained at the lowest dose administered; however the duration of spectrum signal enhancement did increase with increasing dose.

Dose-Ranging, Dose Tolerance Studies

A single-center, single-blind, placebo-controlled, ascending-dose study was conducted to determine the safety and tolerability of SonoVue when administered as a single intravenous bolus injection (0.003, 0.01, 0.03, 0.06, 0.09, or 0.12 mL/kg), and to investigate the presence of contrast enhancement and facilitated visualization of the cardiac chambers with SonoVue administration during 2D echocardiography. A total of 24 healthy male volunteers received SonoVue (n=4 per dose) and 12 received saline placebo (n=2 per dose). Single intravenous bolus dose administration of SonoVue up to 0.12 mL/kg (8.4 mL in a 70-kg person) was well-tolerated in healthy male subjects. Off-site assessment of echocardiographic images indicated an improvement in endocardial border definition relative to baseline with all doses of SonoVue, while no change in endocardial border definition score was observed with placebo. The balance between contrast enhancement and attenuation appeared to be optimal at the 0.01 mL/kg SonoVue dose, while duration of contrast enhancement appeared to be optimal at doses of 0.06 and 0.09 mL/kg. Kinetic parameters obtained from video intensity versus time curves indicated that the time to peak contrast in the left ventricle was relatively constant (about 20 seconds) at doses of 0.003 to 0.03 mL/kg. Contrast persistence (time elapsing from the first appearance of contrast in the left chamber to ½ peak intensity) was dose-related from 0.003 mL/kg (28 seconds) to 0.09 mL/kg (142 seconds), but did not increase further at the 0.12 mL/kg dose (107 seconds).

ANIMAL DATA: PHARMACODYNAMICS

Imaging Studies

SonoVue produced opacification in the right and the left heart chambers in rabbits, dogs and minipigs and improved significantly border delineation after bolus IV administration. A dose-dependent increase in intensity was observed in the left ventricle up to approximately 0.03 mL/kg. This dose showed reproducible results in minipig. Increasing the dose resulted in no additional increase in intensity, but did result in a prolongation of contrast, which consisted of an increase in half-life and in the area under the curve. Extensive acoustic attenuation (shadowing) became important above 0.1 mL/kg. In all three animal species, the best results for left heart opacification were obtained with 0.01 to 0.05 mL/kg.

In the minipig, contrast enhancement of the myocardium was detectable in B-mode after IV injection of SonoVue at doses ranging from 0.05 to 0.25 mL/kg.

In a study performed in dogs, SonoVue permitted detection of myocardial perfusion abnormalities experimentally produced in this animal species by acute thrombotic coronary occlusion, and to assess the spatial event of perfusion defects.

A study performed in minipigs and in rabbits using various sonographic devices, showed that SonoVue produced left heart cavity opacification in fundamental 2D-mode at doses of 0.003 to 0.1 mL/kg in the minipig. It enhanced the pulsed wave Doppler signal of the mitral valve and carotid artery in the minipig. In the rabbit, it enhanced the abdominal artery, portal vein and renal artery from 0.0003 to 0.003 mL/kg and the colour Doppler energy signal in the liver and kidney at doses of 0.015 to 0.6 mL/kg. A demonstration of the effect on the Doppler signal in the mid-cerebral artery was also done in sheep showing an imaging dose of 0.05 mL/kg for pulsed wave Doppler and 0.01 mL/kg in colour Doppler imaging and colour Doppler energy modes.

Effects on the Central Nervous System

The general behavioural response and potential neurotoxic effects at high doses of SonoVue were evaluated by clinical observations during the single and repeated dose studies. No drug-related abnormal findings were observed in the monkeys treated at 20 mL/kg (corresponding to approximately at least 140 times the highest proposed human dose based upon body surface area) during the single dose toxicity study, nor in the rats and monkeys treated daily for 28 days up to the dose of 5 mL/kg during the repeated dose studies. The 5 mL/kg in rats and 5 mL/kg in monkeys corresponded to at least 17 times and 35 times the human exposure to the highest proposed dose of SonoVue, respectively.

Effects on the Cardiovascular and Respiratory Systems

In preliminary studies with preparations of other echogenic products, which had some compositional and physical similarities to SonoVue, systemic hypotension and/or pulmonary hypertension were observed in dogs and minipigs, but not in rats, rabbits or monkeys. Similar reactions were observed by other investigators with preparations containing particulates, phospholipid emulsions or liposomes. These reactions included systemic hypotension as described with liposomal doxorubicin, and pulmonary hypertension in ungulates. It has been shown that pigs and other ungulates are not appropriate models for safety pharmacology testing of IV administered products containing particles as they have a very high number of intravascular macrophages in their pulmonary vessels. It should be noted that in the pig the effect is related to the injection of particulates and not specifically to phospholipids or liposomes.

The observed effects may be mediated by substances released in the circulation during the phagocytosis of liposomes by the RES macrophages or by stimulation of the pulmonary microvasculature. These effects are counteracted by indomethacin pre-treatment. Differences between animal species may be due to different modalities of interaction between erythrocytes, platelets and phagocyting cells during phagocytosis and to different body distribution of phagocyting cells in these species. Moreover, a different involvement of complement activation among various species may also play an important role because of interference between complement activity and phagocytosis or liposome-platelet binding.

Extensive optimization studies have led to the final formulation of SonoVue, for which the cited pharmacological effects should be absent or minimized. Moreover, the proposed clinical dose corresponds to a dose of lipids far lower than those that had induced the effects described above. Nevertheless, because of this background, documentation of SonoVue includes the study of effects on systemic and pulmonary BP in some animal models. A series of studies has been performed in rats, rabbits as well as in dogs after a single dose of 0.3 mL SonoVue kg or a single dose of 1 mL SonoVue/kg. These doses in animals ranged from at least 1 to 10 times the maximum human exposure to SonoVue, based upon body surface area.

Effects on the Cardiovascular and Respiratory Systems in the Rat

After a single IV administration of 0.3 mL SonoVue/kg or 1 mL SonoVue/kg to anesthetized rats, no statistically significant changes in airways resistance, lung compliance, heart rate, systemic arterial pressure were observed in the treated animals when compared to control animals receiving saline under the same experimental conditions. After a single IV administration of 0.3 mL SonoVue/kg or 1 mL SonoVue/kg to unanesthetized rats, no modifications in arterial blood gases (PCO_2 and PO_2) and pH were observed. These doses in rats represented at least 1 to 3.5 times the maximum human exposure to SonoVue, based upon body surface area.

Effects on the Cardiovascular and Respiratory Systems in the Rabbit

After a single IV administration of 0.3 mL SonoVue/kg to anesthetized rabbits, the airways resistance, lung compliance, heart rate and pulmonary arterial pressure were recorded prior and up to 60 min after administration. No effects were observed. No statistically significant changes were observed for the same parameters in the treated animals receiving 1 mL SonoVue/kg when compared to control animals receiving saline in the same experimental conditions. These doses in rabbits represented at least 2 to 7 times the maximum human exposure to SonoVue, based upon body surface area.

Effects on Arterial Pressure and Hematology in the Dog

In a study carried out in non-anesthetized dogs, SonoVue was administered IV by bolus at the dose of 0.3 mL/kg. No changes were observed in systemic arterial pressure or hematology parameters in the treated animals (2 males and 2 females) either during or after administration of SonoVue. A second experiment was performed at the dose of 1 mL/kg. An effect of the product inducing hypotension and thrombocytopenia/leukopenia was noted. Only two dogs out of seven treated with SonoVue showed hypotension. The effect was transient and the animals recovered quickly. Hypotension was reversed and normalized within 10 minutes after administration, and hematology parameters have returned to normal values when measured 2 hours after dosing. These doses in dogs represented at least 3 to 10 times the maximum human exposure to SonoVue, based upon body surface area.

Effect on the Cardiovascular System in Monkeys

Cardiovascular parameters were studied in monkeys (Macaca fascicularis) during the single and repeated dose toxicity studies. Systemic arterial BPs and heart rates were monitored before and up to 30 minutes after dosing in the single dose toxicity study in monkeys at 20 mL/kg. No treatment related changes were observed.

During the repeated dose study in the monkey ECGs were recorded at the beginning of the experiment, 1 hour before and 1 hour after the first dosing and at the end of treatment, once during Week 4, 1 hour before and 1 hour after dosing. No treatment-related changes

were observed in controls and in monkeys dosed at 0.2, 1 and 5 mL/kg. These doses in monkeys represented at least 1.4 to 139 times the maximum human exposure to SonoVue, based upon body surface area.

Effect on Microcirculation

Hamster Cheek Pouch Model: The potential side effect of SonoVue on microcirculation was studied using the hamster cheek pouch model. SonoVue was injected IV via the jugular vein at doses of 3.8 or 7.6 mL/kg in Syrian golden hamsters. The following aspects were evaluated by microscopic observation of the capillaries in the cheek pouch: apparent interruption of flow in all parts of the vascular bed, microvascular contraction or dilatation (arterial diameter increase or decrease), microvascular protein leakage (extravasation of FITC-dextran which appears as fluorescent spots mainly at postcapillary venule sites), effect on leukocyte adhesion to postcapillary venules (fluorescent leukocytes). No apparent interruption of the microvascular blood flow was noticed, no apparent modification of the diameter of the arterioles was detected and no microvascular permeability to macromolecules was seen.

Rat Study: A study evaluated the behavior of SonoVue microbubbles in the spinotrapezius muscle microcirculation in the rat and the extent of microbubbles retention by intravital microscopy immediately after intra-arterial injection of 1, 2.5 or 5 mL/kg (i.e., up to 17 times the human dose relative to body surface area, 100 times relative to body weight). A total of 67 intra-arterial injections of SonoVue were performed in 38 rats and overall 1729 microscopical fields were observed. The product was injected directly into the aortic trunk via a carotid cannula. There were no substantial changes in arteriolar, venular and capillary blood flow except in microvessels where bubbles were transiently retained. When the red blood cell (RBC) flux was transiently interrupted, it resumed spontaneously as soon as the bubbles moved or disappeared. There was no evidence of RBC modification, or of leukocyte and platelet adhesion at the site of retainment, nor of thrombosis. Retained microbubbles (defined as those retained at a single site for >5 s) were primarily observed in capillaries (<6 µm). No retained microbubbles were observed in post-capillary venules. The number of retained bubbles decreased rapidly as a function of time. Retained microbubbles were very flexible and could modify their shape. Elongation of microbubbles was seen in microvessels. Retained microbubbles moved along the microvessels intermittently while decreasing in size due to gas dissolution. No retained microbubbles were observed 20 minutes after an intra-arterial injection of SonoVue, at all three doses.

Effect on Brain Circulation

SonoVue in the brain was demonstrated after intracarotid injection in the rat. In this experiment SonoVue was administered directly into the right carotid artery of anesthetized rats at the dose of 1 mL/kg (at 3.5 times the human exposure at the maximum proposed dose). The ischemia-induced cerebral damages were evaluated by histology and by the assay of the neuron-specific enolase (NSE), a specific marker of neuronal degeneration, in the cerebrospinal fluid. No cerebral infarct was detected in the brain after the intracarotid injection of saline or SonoVue (1 mL/kg). NSE was not affected after injection of SonoVue. In positive control groups, cerebral infarcts were detected after the injection of 1500, 2900 or 7500 polystyrene 50 µm microspheres. In these groups, the incidence of cerebral injuries, the infarct volume, the score of the lesion were dose dependent. Significant increases in cerebrospinal fluid NSE were detected, showing also a dose dependence. The results of this study show that SonoVue (1 mL/kg in a carotid artery) did not induce any cerebral ischemic lesion after intracarotid injection.

Effect in Dogs with Compromised Pulmonary Function

A study was conducted to evaluate compromised pulmonary function. Pulmonary arterial hypertension was induced in anesthetized dogs by the injection of glass beads (150-200 µm) into the right ventricle of the heart. In dogs with induced PAH, cumulative doses of SonoVue (0.1, 0.3 and 1 mL/kg) administered at 15 min intervals had no effects on arterial blood pressure, heart rate and on QT and QTc (Frederica's formula) intervals of the ECG. Furthermore, increasing doses of SonoVue did not modify the myocardial (LVP and myocardial contractility) or pulmonary (tidal volume and respiratory rate) functions. At the highest dose (1 mL/kg) of SonoVue only, a transient increase (2.5±1.3 mmHg, n=4) in pulmonary arterial pressure was observed between 5 to 7 min after administration, this effect was more marked in 1 of the 4 animals tested.

In addition a review of the microscopic finding of all the toxicology studies in animals did not indicate a pulmonary safety concern at high multiples of human exposure.

Drug Interaction Studies

Patients receiving SonoVue may also be treated with antihypertensive agents such as captopril, propranolol and nifedipine. Propranolol and nifedipine have also antihypertensive properties and, in addition, propranolol is used in angina pectoris or myocardial infarct treatment.

The possible interactions between SonoVue and these drugs were studied in spontaneous hypertensive animal models in a study in rats. The drugs were infused intravenously to the anaesthetised hypertensive rats and SonoVue was administered concurrently as a bolus i.v. injection (1 mL/kg). The effect of SonoVue was assessed

by the mean arterial blood pressure (ABP) and heart rate (HR) monitoring. SonoVue did not interact with the effect of propranolol, captopril and nifedipine on rat ABP or HR. This study suggests that SonoVue does not interact with the antihypertensive therapeutic efficiency of propranolol, captopril or nifedipine.

Other studies showed that there was no effect of a concurrent administration of SonoVue in the rat with the anticoagulant activity of heparin, and with the cardiovascular effects of isosorbide dinitrate and of digoxin. There was also no effect of SonoVue on the antiplatelet effect of acetylsalicylic acid on the rat platelet-enriched plasma *in vitro*.

PHARMACOKINETICS

IN VITRO DATA

KINETICS OF INTACT MICROBUBBLES

The pharmacokinetics of the "intact" microbubbles is best characterized using echography. Since only intact microbubbles that contain gas can be imaged, the disappearance of the image coincides with disintegration of the intact microbubble and release of the encapsulated gas. However the fate of smaller bubbles (<2 µm) which are present in high concentration in SonoVue cannot be followed by echography since these bubbles are non-echogenic and therefore non-imageable. In order to follow the fate of this particular category of bubbles, and to obtain information on the stability and fragility of SonoVue microbubbles in plasma (independently of their size), an in vitro study was performed by incubating the product in saline or plasma at 37°C. The changes in concentration and size distribution of the microbubbles as a function of incubation time were followed by light microscopy. At 37°C all bubbles disappear within 20 minutes. The initial disappearance rate (from 0 to 10 minutes) follows a mono-exponential decay curve with a half life of 2.2 minutes and is independent of bubble sizes. The good stability of SonoVue microbubbles in saline at 22°C is lost when the temperature is raised to 37°C. Similarly, incubation in plasma even at 22°C leads to a rapid disappearance of SonoVue microbubbles. This study shows that a prolonged presence in the blood stream of SonoVue bubbles or of a sub-population of SonoVue bubbles is unlikely to occur beyond 20 minutes after injection.

IN VIVO DATA

HUMAN DATA: PHARMACOKINETICS

An open-label, two-period crossover study conducted in 12 healthy volunteers (7 males, 5 females) to establish the blood kinetics and pulmonary elimination of SF_6 after intravenous administration of escalating doses of SonoVue (0.03 and 0.3 mL/kg). Blood concentrations of SF_6 reached a maximum within 1 to 2 minutes postdose for both doses of SonoVue and for both males and females. Following C_{max}, SF_6 concentrations declined rapidly. For the 0.3 mL/kg dose, the decline was bi-phasic, with a mean distribution phase half-life of 1.11 minutes and a terminal elimination phase half-life of 9.88 minutes. For the 0.03 mL/kg dose, the terminal elimination phase could not be defined and half-lives could not be calculated. Blood pharmacokinetic parameters were generally similar for males and females and were dose-proportional over the dose range tested. Pulmonary elimination of SF_6 was extremely rapid, with means of approximately 39% to 45% (males) and 43% to 47% (females) of the administered dose eliminated within the first minute postdose at both the 0.03 and 0.3 mL/kg dose levels. By 11 minutes postdose, 81% to 84% (males) and 78% to 89% (females) of the administered doses had been expired. Examination of the mean cumulative pulmonary elimination of SF_6 showed that at 90 minutes after the injection, 86% of the 0.03 mL/kg dose and 94% of the 0.3 mL/kg dose was recovered in expired air. However, there was a high degree of inter-subject variability in the recovery of SF_6, ranging from 54% to 128% at the 0.03 mL/kg dose and from 61% to 153% at the 0.3 mL/kg dose.

A Phase I, open-label study conducted in 13 patients with a known diagnosis of diffuse interstitial pulmonary fibrosis (8 males, 5 females). All patients received a single intravenous bolus injection of 0.3 mL/kg SonoVue (12 patients included in pharmacokinetic analysis). Maximum concentrations of SF_6 in blood (C_{max}) ranged 10-fold from 0.35 to 3.79 µg/L and occurred between 0.97 and 4.0 minutes after administration of SonoVue. The mean terminal half-life of 11.6 minutes was similar to that observed in healthy subjects (9.88 min). Linear regression analysis demonstrated a statistically significant decrease in apparent total blood clearance as the severity of pulmonary impairment increased ($p=0.0469$); however, the strength of the relationship diminished when clearance estimates were normalized to body weight ($p=0.0831$). Elimination half-lives ranged from 17.1 to 75.6 minutes with a mean of 31.3 minutes. The actual percentage of the dose recovered as SF_6 in the expired air ranged from 69.7% to 128.7% with an overall mean value of 102.2%. This is similar to the range observed in healthy volunteers who received the same dose of SonoVue, ie, 61% to 153% at the 0.3 mL/kg dose.

ANIMAL DATA: PHARMACOKINETICS

Kinetics of the Gas Forming the Microbubbles

The blood kinetics and elimination of SF_6 after a single IV dose of SonoVue (0.3 or 1 mL) was studied in rabbits.

Distribution

The maximum total volume of SF_6 (in microbubbles and dissolved in the liquid phase) in an imaging clinical dose of 2 mL SonoVue would be approximately 30 µL or about 6 µL/L of blood. Therefore, SF_6 is administered to patients in a trace amount that is rapidly excreted via the pulmonary route.

Metabolism

The phospholipid components of SonoVue forming the envelope of the microbubbles are all natural products and therefore enter natural metabolism through exchange between phospholipid vesicles and lipoproteins or plasma membranes in blood and inside phagocytic cells. Moreover, the quantities of phospholipids in a clinical dose (2.3µg/kg) are negligible in comparison with the quantities of their endogenous equivalents, so an imbalance due to contrast medium administration should not be evident.

Excretion

After IV injection, SF_6 disappeared rapidly from the blood. Approximately 80% of the injected dose was cleared in the first minute after dosing. The blood levels of SF_6 dropped to background levels by 11 minutes after the 0.3 mL/kg dose and 20 minutes after the 1 mL/kg dose. Total clearance of SF_6 from blood was extremely rapid (218 to 231mL/min/kg) and the half-life of elimination of blood SF_6 was less than 1 minute. The SF_6 was eliminated almost exclusively via the pulmonary route, with more than 90% of the injected dose recovered in expired air within 3 minutes. Only ultra-trace quantities (less than 0.1 ng/g-urine) were detected in urine that was contained in the bladder at 2 hours after dosing, indicating that renal excretion is not an elimination route for SF_6.

TOXICOLOGY

CARCINOGENESIS, MUTAGENESIS AND IMPAIRMENT OF FERTILITY

No long-term animal studies were performed to evaluate the carcinogenic potential of SonoVue or potential effects on fertility.

The array of *in vitro* and *in vivo* tests performed on procaryotic organisms, animals, and cultured human lymphocytes with SonoVue did not reveal any problem or potential problem concerning mutagenesis or chromosome damage.

REPRODUCTION STUDIES

Reproduction studies have been performed in rats and rabbits at daily doses up to at least 17 times and 35 times the daily human exposure, respectively, based upon body surface area, and have revealed no evidence of impaired fertility or harm to the fetus due to SonoVue.

SINGLE AND REPEATED DOSE STUDIES

A single IV dose of SonoVue had no adverse effects in rats and monkeys at approximately 69 times and 140 times the highest proposed human dose, respectively, based upon body surface area. No drug-related adverse effects were observed after daily repeated dosing of 5 mL SonoVue/kg for 28 days in rats and monkeys (representing daily doses of 17 times and 35 times the highest proposed human dose, respectively), with the exception of a species-specific colon and cecal lesion that was observed only in rats. This colon and cecal lesion was not reproducible in a second 28-day rat study, and did not occur in all repeated dose rat studies. Additionally, this finding did not occur in rats after a single 20 mL/kg IV dose of SonoVue, which represented at least 69 times the highest proposed human exposure to SonoVue after a single dose based upon body surface area.

HISTOPATHOLOGICAL FINDINGS AFTER EXPOSURE TO SONOVUE AT VARIOUS MECHANICAL INDEX VALUES

A study was carried out in the rat to examine microscopically the organs after an intravenous injection up to 5 mL/kg and exposure to ultrasound at various mechanical index values. In this study, 10 seconds after starting the ultrasound exposure the animals were injected with either SonoVue (1 or 5 mL/kg) or saline. The organs (liver, spleen, kidneys, intestines and abdominal vessels, stomach, pancreas, heart, thymus, lung and carotid arteries) were exposed to ultrasound at various mechanical index values (MI of 0.4, 0.8 and 1.9) for a total duration of 5 minutes. The maximum dose level of SonoVue corresponded to 17 times the human dose relative to body surface area (more than 100 times relative to body weight). In rats sacrificed 1 hour after exposure, some minimal areas of blood suffusion within the pulmonary alveoli or close to the mesenteric blood vessels were observed microscopically in both the saline and the SonoVue treated animals. The incidence and grade of these findings show that they are not related to the administration or the dose of SonoVue. The mesenteric lesions were rare and represent probably artifacts related to the necropsy procedure. The pulmonary lesions, observed both in the saline control groups and the SonoVue treated groups were related to the ultrasound exposure itself. Similar hemorrhagic lesions were also reported in the literature after ultrasound exposure alone in the lung of rats. No other histopathological lesions, which could be attributed to the treatment of SonoVue and ultrasound exposures, were observed. In particular there were no lesions on the carotid arteries, in the heart or in the intestinal tract, which can be related to the administration of SonoVue during ultrasound exposure at these various MI values.

REFERENCES

Avelar E, Kolias T, Portis M, Bosson E, Batra S, Vannan M. Assessment of resting myocardial perfusions using SonoVue myocardial contrast echocardiography using triggered pulse inversion harmonic imaging: A comparison to SPECT sestamibi imaging [abstract]. Eur Heart J. 1999;20:167.

Avelar E, Portis M, Li P, Batra S, Vannan M. Myocardial contrast echocardiography by parametric imaging using intravenous SonoVue compared to SPECT sestamibi to detect myocardial perfusion defects [abstract]. Circulation. 1999;110 (18 supp):1060.

Ay T, Havaux X, Van Camp G, Campanelli B, Gisellu G, Pasquet A, et al. Destruction of microbubbles by ultrasound: Effect on myocardial function, coronary perfusion pressure, and microvascular integrity. Circulation. 2001;104:461-6.

Bogdahn U, Hölscher T, Ludger R, Götz B, Schlachetzki F. Contrast-enhanced transcranial and extracranial duplex sonography: Preliminary results of a multicenter phase II/III study with SonoVue. Echocardiography. 1999;16:761-6.

HC 2001 Guidelines for the Safe Use of Diagnostic Ultrasound. www.hc-sc.ca/hecs-sesc/ccrpb/01hecs255.pdf

Kaps M, Seidel G, Bokor D, Modrau B, Algermissen C. Safety and ultrasound-enhancing potentials of a new sulfur hexafluoride-containing agent in the cerebral circulation. J Neuroimag. 1999;9:150-4.

Lindner JR, Villaneuva SF, Dent JM, Wei K, Sklenar J, Kaul S. Assessment of resting perfusion with myocardial contrast echocardiography: Theoretical and practical considerations. Am Heart J. 2000;139:231-40.

Morel DR, Schwieger I, Hohn L, Terrettaz J, Llull JB, Cornioley YA, et al. Human pharmacokinetics and safety evaluation of SonoVue, a new contrast agent for ultrasound. Invest Radiol. 1999;16:761-6.

Nanda NC, Hack TC, Wistran DC, Carr MA, Hall JJ, Ryan T, et al. Multicenter evaluation of SonoVue for improved endocardial border delineation: Comparison with Albunex [abstract]. Circulation. 1999;110(18 supp):2347.

Schneider M, Arditi M, Barrau MB, Brochot J, Broillet A, Vent R, et al. BR1: A new ultrasonographic contrast agent based on sulfur hexafluoride-filled microbubbles. Invest Radiol. 1995;30:451-7.

Senior R, Kaul S, Soman P, Lahiri A. Power doppler harmonic imaging: A feasibility study of a new technique for the assessment of myocardial perfusion. Am Heart J. 2000;139 (no.2, pt 1):245-51.

Van der Wouw, Brauns AC, Bailey SE, Powers JE, Wilde AA. Premature ventricular contractions during triggered imaging with ultrasound contrast. J Am Soc Echocardiogr. 2000;13:288-94.

Wible JH, Galan KP, Wojdyla JK, Hughes MS, Klibanov AL, Brandenburger GH. Microbubbles induce renal hemorrhage when exposed to diagnostic ultrasound in anesthetized rats. Ultrasound Med Biol. 2002;28:1535-46.

PART III

CONSUMER INFORMATION

SONOVUE®

sulfur hexafluoride

This leaflet is part III of a three-part "Product Monograph" published when SonoVue® was approved for sale in Canada and is designed specifically for consumers. This leaflet is a summary and will not tell you everything about SonoVue. Contact your doctor or pharmacist if you have any questions about the drug.

ABOUT THIS MEDICATION

WHAT THE MEDICATION IS USED FOR

SonoVue is a stabilised microbubble preparation for diagnostic use with ultrasound imaging.

WHAT IT DOES

SonoVue reflects the ultrasound beam and provides a better echo and view of the subject tissues and abnormalities of the body.

WHEN IT SHOULD NOT BE USED

You should not take SonoVue if you:

- have right-to-left shunts of the heart;
- have a condition where medicines or devices are needed to help maintain normal blood pressure and heart function (e.g. cardiovascular instability) and are taking dobutamine;
- have a severe increase in pulmonary artery blood pressure;
- have uncontrolled hypertension (high blood pressure);
- have adult respiratory distress syndrome;
- shortness of breath
- had allergy-like reactions to SonoVue or any non-medicinal ingredient in the formulation. (see "What the important non-medicinal ingredients are" section.)

WHAT THE MEDICINAL INGREDIENT IS

sulfur hexafluoride

WHAT DOSAGE FORMS IT COMES IN

Suspension for injection.

WHAT THE IMPORTANT NON-MEDICINAL INGREDIENTS ARE

Each vial of reconstituted lyophilized powder contains: dipalmitoylphosphatidylglycerol (DPPG.Na) - 0.19 mg, distearoylphosphatidylcholine (DSPC) - 0.19 mg, palmitic acid - 0.04 mg, polyethylene glycol - 24.56 mg, sodium chloride (0.9% solution for reconstitution) - 5 mL

OVERDOSE

No overdosing has so far been reported. If you think you have been administered too much SonoVue, contact your attending healthcare professional for the procedure, even if there are no symtoms.

INTERACTIONS WITH THIS MEDICATION

Drugs that may interact with SonoVue:
No drug interaction studies have been done for SonoVue. Tell your doctor if you are taking any other medications, including non-prescription drugs.

PROPER USE OF THIS MEDICATION

Usual dose:
Usual adult dose is 1.2 mL or 2.0 mL depending on condition, as determined by your doctor.

SIDE EFFECTS AND WHAT TO DO ABOUT THEM

SonoVue will only be administered to you by a qualified health care professional during an ultrasound examination. Report to them any side effects you experience during or after the procedure. You will be monitored for 30 minutes after your examination. Common side effects include headache, nausea, injection site pain, paresthesia (tingling in the extremities), and less commonly, vomiting.

WARNINGS AND PRECAUTIONS

BEFORE you use SonoVue, talk to your doctor or pharmacist if:

- You are pregnant or planning to become pregnant;
- You are breast feeding or planning to breastfeed;
- You had a heart attack (myocardial infarction) or any procedure on the artery supplying blood to the heart (coronary artery);
- You suffer from angina or chest pain, or heart failure or severe heart rhythm disorders,
- You have had changes in the electrical activity of your heart (electrocardiography changes).
- You have a congenital heart defect (including right-to-left ventricular shunts), severe increased pulmonary hypertension (high blood pressure in the blood vessels of the lung), acute or severe congestive heart failure, unstable angina (blockage of the heart's arteries), a severe arrhythmia (irregular heartbeat), unstable neurological disease, chronic obstructive pulmonary disease, or a recent organ transplant;
- You have any personal or family history of altered heart rhythm e.g. QTc prolongation, proarrhythmic conditions such as recent hypopotassemia (low potassium blood levels), significant bradycardia (low heartbeat), acute myocardial ischemia (insufficient blood supply to the heart), clinically relevant heart failure with reduced left-ventricular ejection fraction or previous history of symptomatic arrhythmias.
- You are taking any medications, including non-prescription drugs before having this procedure.
- You are taking beta blockers, including some eye drop medicines.
- You have liver or kidney disease.
- You have ongoing serious infection (sepsis).
- You have recent thromboembolism (a blood clot blocking blood flow in the body).

SERIOUS WARNINGS AND PRECAUTIONS

Severe allergic reactions have been experienced with SonoVue (see **Side Effects**). Serious reactions involving both the heart and lungs, including deaths, have been experienced during or after the injection of SonoVue (see **Warnings and Precautions**). Most serious reactions happened within 30 minutes of the administration. Your doctor will consider your condition to determine whether SonoVue is suitable for you. Your attending healthcare professional will ensure that resuscitation equipment and personnel are at hand during and after the imaging procedure, in case of a serious reaction to SonoVue.

SERIOUS SIDE EFFECTS, HOW OFTEN THEY HAPPEN AND WHAT TO DO ABOUT THEM

	SYMPTOM/EFFECT	TALK WITH YOUR DOCTOR OR PHARMACIST	
		Only if severe	In all cases
UNCOMMON	Cardiac arrhythmia (irregular heartbeat)		X
VERY RARE	Severe allergic reaction, which may include shock, with symptoms such as a sensation of light-headedness and loss of strength, low heartbeat, low blood pressure, skin rash, swelling of the mouth and throat, difficulty breathing.		X

This is not a complete list of side effects. For any unexpected effects while taking SonoVue, contact your doctor or pharmacist.

HOW TO STORE IT

Healthcare professionals will store the kit before and after reconstitution at 15-25°C.

REPORTING SUSPECTED SIDE EFFECTS

You can help improve the safe use of health products for Canadians by reporting serious and unexpected side effects to Health Canada. Your report may help to identify new side effects and change the product safety information.

3 ways to report:

- Online at MedEffect;
- By calling 1-866-234-2345 (toll-free);
- By completing a Consumer Side Effect Reporting Form and sending it by:
  Fax to 1-866-678-6789 (toll-free), or
  Mail to: Canada Vigilance Program
  Health Canada, Postal Locator 1908C
  Ottawa, ON K1A 0K9

Postage paid labels and the Consumer Side Effect Reporting Form are available at MedEffect.

NOTE: Contact your health professional if you need information about how to manage your side effects. The Canada Vigilance Program does not provide medical advice.

BRACCO IMAGING Canada
11065 boul. L.-H. Lafontaine, Anjou, Quebec, Canada H1J 2Z4

Date of Revision: October 2020