80th ANNUAL SCIENTIFIC MEETING
80e CONGRÈS SCIENTIFIQUE ANNUEL

APRIL 20 – 23, 2017 | LE CENTRE SHERATON | MONTRÉAL, QUÉBEC | DU 20 AU 23 AVRIL 2017

1937–2017
Radiology Care:
A VALUE-DRIVEN APPROACH

1937–2017
Les soins de radiologie :
UNE APPROCHE AXÉE SUR LA VALEUR DES SERVICES

Canadian Association of Radiologists
L'Association canadienne des radiologistes

CARadiologists #CAR2017ASM 613 860-3111 education@car.ca

THANK YOU TO OUR SPONSORS
REMERCIEMENTS À NOS COMMANDITAIRES

Thank you to our sponsors for generously providing educational grants in support of the CAR 80th Annual Scientific Meeting.

Nous remercions les commanditaires suivants pour leur subvention de formation envers le 80e Congrès scientifique annuel de la CAR.

Platinum / Platine

GE

Gold / Or

Bayer

BRACCO
BRACCO IMAGING Canada

CADTH Evidence Driven.
ACMTS Preuves à l'appui.

CHRISTIE INNOMED

Silver / Argent

BARD CANADA

Canon

CCE MEDICAL EQUIPMENT
SAMSUNG

College of Medical Radiation Technologists of Ontario
Ordre des technologues en radiation médicale de l'Ontario

eRAD

IBM Watson Health
MERGE An IBM Company

Institute for Quality Management in Healthcare

Intelerad® Distributed Radiology Solutions™

methapharm Specialty Pharmaceuticals

Northwest Territories Health and Social Services Authority

PHILIPS

ROYAL COLLEGE OF PHYSICIANS AND SURGEONS OF CANADA
COLLÈGE ROYAL DES MÉDECINS ET CHIRURGIENS DU CANADA

SIEMENS Healthineers

terarecon

TD

TOSHIBA MEDICAL

uOttawa
Faculté de médecine
Faculty of Medicine

WORKOPOLIS

CAR 80th ANNUAL SCIENTIFIC MEETING
80e CONGRÈS SCIENTIFIQUE ANNUEL DE LA CAR

THANK YOU TO OUR VOLUNTEERS

The Canadian Association of Radiologists wishes to extend its sincere thanks to the volunteer members of the ASM Working Group. It is their dedication, expertise and pursuit of excellence that has shaped this year's outstanding educational programme.

REMERCIEMENTS À NOS VOLONTAIRES

L'Association canadienne des radiologistes souhaite transmettre ses remerciements les plus sincères aux membres bénévoles du Groupe de travail du Congrès scientifique annuel. Leur dévouement et leur expertise ont contribué à mettre sur pied un programme scientifique d'une qualité exceptionelle.

Canadian Association of Radiologists 80th Annual Scientific Meeting Working Group Members
Membres du groupe de travail du 80e Congrès scientifique annuel de l'Association canadienne des radiologistes

Jonathon Leipsic, MD, Radiologist | radiologiste, Vancouver, Chair | président du groupe de travail
Basma Al-Arnawoot, MD, Radiology Resident | résidente en radiologie, Hamilton
Tanya Chawla, MD, Radiologist | radiologiste, Toronto
Carole Dennie, MD, Radiologist | radiologiste, Ottawa
Gina Di Primio, MD, Radiologist | radiologiste, Oakville
Angus Hartery, MD, Radiologist | radiologiste, St. John's
Iain Kirkpatrick, MD, Radiologist | radiologiste, Winnipeg
Emil Lee, MD, Radiologist | radiologiste, Vancouver
Caitlin McGregor, MD, Radiologist, radiologiste, Toronto
Haron Obaid, MD, Radiologist / radiologiste, Saskatoon
Michael Patlas, MD, Radiologist | radiologiste, Hamilton
Bruce Precious, MD, Radiologist | radiologiste, Halifax
Francesca Proulx, MD, Radiologist, radiologiste, Montreal
Elena Scali, MD, Radiology Resident | résidente en radiologie, Vancouver
Gilles Soulez, MD, Radiologist | radiologiste, Montreal
Michelle Zhang, MD, Radiology Resident | résidente en radiologie, Montreal

Working Group Disclosures / Divulgations du Groupe de travail

Dr. Iain Kirkpatrick declares that
- his travel expenses have been covered to speak at the Siemens Innovations Symposium in Vancouver, October 2016.

Dr. Emil Lee declares that
- he is a principal for MedVal Systems Inc.

Dr. Jonathon Leipsic declares that he
- is a consultant with Edwards Lifesciences, CircleCVT, Heartflow, Neovasc, Philips, Pi Cardia and Samsumg; and,
- has been a speaker for GE Healthcare and received a grant from Heartflow.

Dr. Gilles Soulez declares that he
- received an honorarium for a conference with Cook Medical;
- received a grant for research study from Siemens Medical, BTG Medical and CAE Medical; and,
- participated in a clinical trial with TVA Medical and Biotronik.

TABLE OF CONTENTS / TABLE DES MATIÈRES

BRACCO IMAGING Canada

Your Patient, **Our Priority**

For more information on our products, please call 1-800-465-5820

BRACCO IMAGING Canada, 11065 Louis H.-Lafontaine, Anjou, Québec, H1J 2Z4


BAYER
Clear Direction.
From Diagnosis to Care.

WELCOME LETTERS
MOTS DE BIENVENUE

Dear colleagues,

It is with great pleasure that I welcome all of you to Montreal for the 80th Annual Scientific Meeting of the Canadian Association of Radiologists.

Developed with an overarching theme of *Radiology Care: A Value-Driven Approach*, the meeting will address many current issues that are central to our profession, such as new technologies, how to integrate them thoughtfully, and how to use imaging to help guide therapeutic decision-making to improve clinical outcomes.

Featuring an exciting mix of didactic lectures, debates and a hands-on workshop, along with great social activities, this conference is the perfect setting to share expertise, as well as discuss the advances and breakthroughs in the field of radiology with colleagues from across Canada.

This year, the CAR is offering two sister events to provide further learning opportunities. The first is a mainstay of our CME offerings: the Advanced Cardiac Life Support for Radiologists (ACLS-r) course, held in conjunction with CAE Health and the Université de Montréal. The second is our inaugural Leadership in Radiology course, co-developed by your CAR leaders, the Canadian Radiological Foundation, and UBC Sauder School of Business.

I would like to take this opportunity to thank: Dr. Jonathon Leipsic (Chair) and the members of the ASM Working Group for their exceptional efforts in preparing such a strong and interesting educational program; our invited speakers for generously sharing their time and expertise; our industry partners, whom I encourage you to visit in the exhibit hall, for their continued support of our profession; and of course, the CAR staff for their diligence and work in organizing this meeting.

This ASM will mark the end of my term as President. I invite all of you to join me in welcoming Dr. Emil Lee as our incoming President at the CAR Wine & Cheese Reception and Awards Ceremony on Saturday.

Wishing you all a successful meeting.

Chers collègues,

Je suis ravi de vous accueillir à Montréal à l'occasion du 80e Congrès scientifique annuel de l'Association canadienne des radiologistes.

Ayant pour thème *Les soins de radiologie : une approche axée sur la valeur des services*, le congrès permettra d'aborder de nombreux enjeux actuels qui sont au cœur de notre profession, par exemple les nouvelles technologies et leur intégration réfléchie, ainsi que l'utilisation de l'imagerie pour orienter la prise de décisions thérapeutiques et améliorer les résultats cliniques.

Heureux mélange de conférences didactiques, de débats, d'ateliers pratiques et de passionnantes activités sociales, le congrès représente l'occasion idéale de partager votre expertise et de discuter des derniers progrès en radiologie avec des collègues de partout au Canada.

Cette année, la CAR présente deux événements en marge du congrès pour offrir davantage des occasions d'apprentissage. Le premier occupe une place centrale dans notre offre pour la formation médicale continue : il s'agit du cours Soins avancés en réanimation cardiorespiratoire pour les radiologistes (SARC/ACLS-r), offert en collaboration avec CAE Santé et l'Université de Montréal. Le deuxième est notre premier cours de leadership en radiologie, créé de concert par les dirigeants de la CAR, la Fondation radiologique canadienne et la Sauder School of Business de la UBC.

Je tiens à remercier le Dr Jonathon Leipsic (président de l'événement) et les membres du groupe de travail du Congrès scientifique annuel pour les efforts exceptionnels investis dans l'élaboration d'un programme rigoureux et passionnant; les conférenciers, qui prennent le temps de partager leur expertise; nos partenaires de l'industrie (que je vous invite à rencontrer dans le hall d'exposition) pour leur appui constant envers notre profession; et, bien sûr, le personnel de la CAR pour sa diligence et son travail d'organisation du congrès.

Cette édition du Congrès scientifique annuel marque la fin de ma présidence. Je vous invite tous à vous joindre à moi pour souhaiter la bienvenue au Dr Emil Lee, notre nouveau président, à l'occasion de la soirée vins et fromages et remise des prix de la CAR qui se déroulera le samedi.

Je vous souhaite un excellent congrès.

Dr. William Miller
President / Président
Canadian Association of Radiologists / L'Association canadienne des radiologistes

Canadian Association of Radiologists
L'Association canadienne des radiologistes

Santé Canada Health Canada

MESSAGE FROM THE MINISTER OF HEALTH
CANADIAN ASSOCIATION OF RADIOLOGISTS' 80th ANNUAL SCIENTIFIC MEETING
MONTREAL, QUEBEC APRIL 20 – 23, 2017

MESSAGE DE LA MINISTRE DE LA SANTÉ
80e CONGRÈS SCIENTIFIQUE ANNUEL DE L'ASSOCIATION CANADIENNE DES RADIOLOGISTES
MONTRÉAL (QUÉBEC) DU 20 AU 23 AVRIL 2017

As Minister of Health, I want to extend warm greetings to the participants of the 80th Annual Scientific Meeting of the Canadian Association of Radiologists. This year's theme, *Radiology Care: A Value-Driven Approach*, will focus on exploring the appropriateness and use of advanced equipment and tools in therapeutic decision-making to provide patients with optimal healthcare experiences and outcomes.

I understand how integral your role is in the health care system and how important it is as radiologists to remain up-to-date and informed on current research and emerging technologies, to ensure the best possible care for patients. As a policy maker, I am working closely with the provinces, territories and the health care community to help ensure our health care system continues to adapt to new challenges, and that it continues to evolve and innovate to help improve the quality of care provided to Canadians.

On behalf of the Government of Canada, I want to thank you for your dedication and professionalism in ensuring the proper diagnosis and treatment of your patients. Through your expertise and commitment, you provide Canadians accurate, safe and appropriate diagnostic testing that contributes to their improved health and well-being.

I wish you all a very successful meeting.

À titre de ministre de la Santé, je tiens à saluer chaleureusement les participants au 80e Congrès scientifique annuel de l'Association canadienne des radiologistes. Le thème de cette année, « Les soins de radiologie : une approche axée sur la valeur des services », mettra l'accent sur l'exploration de la pertinence et de l'utilisation d'équipement et d'outils de pointe dans la prise de décisions thérapeutiques pour fournir aux patients une expérience de soins et des résultats optimaux.

Je comprends à quel point vous jouez un rôle crucial au sein du système de soins de santé et à quel point il est important que les radiologistes se gardent au fait et à jour par rapport aux recherches et aux technologies nouvelles afin d'offrir aux patients les meilleurs soins possible. Comme décideuse, je collabore étroitement avec les autorités provinciales et territoriales et le milieu des soins de santé pour veiller à ce que notre système de santé continue de s'adapter aux nouveaux défis et continue d'évoluer et d'innover en vue d'améliorer la qualité des soins offerts à la population canadienne.

Au nom du gouvernement du Canada, je tiens à vous remercier pour votre dévouement et votre professionnalisme à veiller à ce que vos patients reçoivent de bons diagnostics et de bons traitements. Par votre expertise et votre détermination, vous fournissez à la population canadienne des tests diagnostiques exacts, sûrs et pertinents qui contribuent à l'amélioration de sa santé et de son bien-être.

Je vous souhaite à tous un très bon congrès.

The Honourable Jane Philpott, P.C., M.P. / L'honorable Jane Philpott, C.P., députée
Minister of Health / Ministre de la Santé

Canada

MESSAGE DU MINISTRE DE LA SANTÉ ET DES SERVICES SOCIAUX

MESSAGE FROM THE MINISTER OF HEALTH AND SOCIAL SERVICES

Les récentes réformes apportées par notre gouvernement au réseau de la santé et des services sociaux ont permis de mieux nous préparer à affronter les défis à venir. Ces changements, destinés à améliorer à la fois la qualité et l'accessibilité des services pour la population, ont d'ailleurs bénéficié de la collaboration de tous les intervenants du réseau, et ce, dans un esprit d'interdisciplinarité et de mise en commun de l'expertise qui m'apparaît essentiel et salutaire.

Ce climat d'échange, nous le retrouvons également chez les nombreux professionnels de la santé de notre réseau, notamment à travers la tenue d'événements rassembleurs tels que le Congrès scientifique annuel de l'Association canadienne des radiologistes. Devenu une véritable tradition au fil des ans, ce congrès annuel, qui en est à sa 80e édition cette année, témoigne de l'importance que revêt un tel rassemblement chez les radiologistes.

En proposant de la formation ainsi que des discussions sur les enjeux actuels du milieu de la radiologie, ce congrès vous offre à tous une belle occasion de parfaire vos connaissances et d'en faire bénéficier les usagers du réseau. Le thème de cette année met d'ailleurs l'accent sur une approche axée sur la valeur des services, et je suis ravi de constater que cette volonté s'inscrit en parfaite cohérence avec les efforts que nous avons déployés depuis deux ans pour recentrer notre réseau sur les besoins réels des patients.

Je suis persuadé que ce congrès vous permettra de faire de nombreuses rencontres ainsi que des découvertes qui vous amèneront à optimiser vos façons de faire. De même, je crois que vous saurez faire profiter vos collègues de votre expérience et de vos connaissances de pointe, pour notre bien à tous!

Sur ce, je vous souhaite un excellent congrès et un bon 80e anniversaire!

Our government's recent reforms to the health and social services network have helped us to better prepare for future challenges. These changes, which aim to improve both the quality and accessibility of services for the public, benefited from the cooperation of all network stakeholders in a spirit of interdisciplinarity and sharing of expertise, which I feel is vital and beneficial.

This climate of exchange can also be found among the many health professionals in our network, particularly through engaging events such as the Canadian Association of Radiologists' Annual Scientific Meeting. This conference, which has become a true yearly tradition over the last 80 years, attests the importance of such symposiums for radiologists.

Featuring training on and discussions of current issues in radiology, this conference is a great opportunity for all of you to enhance your knowledge for the benefit of network users. This year's theme emphasizes a value-driven approach to services, and I am delighted to see that it aligns perfectly with the efforts we have deployed over the past two years to refocus our network on the real needs of patients.

I am confident that the conference will give you a chance to network and make discoveries that will help you optimize your practices. I am also counting on you to take this great opportunity to share your experience and leading-edge knowledge with your colleagues for our collective benefit!

On that note, enjoy the conference and have a happy 80th anniversary!

Gaétan Barrette
Ministre de la Santé et des Services sociaux / Minister of Health and Social Services
Gouvernement du Québec / Government of Québec

Québec

Montréal est fière d'accueillir le 80e Congrès annuel de l'Association canadienne des radiologistes.

Je salue le travail et l'engagement de tous les praticiens qui œuvrent dans le domaine de la radiologie, un service essentiel auquel nous avons tous recours un jour.

Je vous souhaite la plus cordiale bienvenue dans cette ville de savoir où la santé est considérée primordiale pour la qualité de vie de tout citoyen. Dans cette ville ouverte sur le monde et sur l'innovation, sur l'avancement et la recherche scientifique, je suis convaincu que vous y trouverez un lieu propice à de fructueux échanges et au partage des meilleures pratiques.

Je vous convie à profiter de Montréal, reconnue pour sa vitalité effervescente, sa gastronomie, ses musées et son architecture. Cette grande métropole culturelle du monde vous invite aussi à célébrer son 375e anniversaire, en 2017. Venez rencontrer les Montréalais, appréciés pour leur caractère chaleureux et festif!

Bon séjour parmi nous!

Montréal is pleased to welcome the 80th Annual Scientific Meeting of the Canadian Association of Radiologists.

I would like to acknowledge the work and dedication of these health practitioners involved in the field of radiology, which is so vital to our well-being.

It is with great pleasure that I welcome you to Montréal, a city of knowledge, where health is essential to the quality of life of our community. Montréal is open to the world and promotes innovation, scientific advancement and research. I am convinced that you will find in Montréal an ideal city for productive exchange and sharing the best practices.

I invite you to enjoy Montréal, a city that is recognized for its vibrancy, fine cuisine, museums and architecture. Our great international cultural city invites you to celebrate its 375th anniversary in 2017. Come and meet with Montrealers and discover their warm and festive spirit.

Enjoy your stay with us!

Denis Coderre
Maire de Montréal / Mayor of Montréal

Montréal

Au nom de Tourisme Montréal et des professionnels de l'industrie touristique de notre ville, je vous souhaite la bienvenue à Montréal pour le 80e Congrès scientifique annuel de la CAR.

Nous sommes honorés que vous ayez choisi Montréal pour votre prestigieuse rencontre. Réputée pour son secteur des sciences de la vie des plus prospères, sa communauté de recherche florissante et son réseau dynamique de professionnels de la santé, Montréal offre de nombreuses opportunités de partage, d'apprentissage et de découverte.

Chez nous, le printemps est toujours excitant et, avec les célébrations du 375e anniversaire de Montréal qui battent leur plein, vous ne manquerez pas de choses à voir et à faire. Alors que le mercure monte et que la nature s'éveille, vous pourrez profiter de l'agréable température des soirs d'avril pour découvrir Cité Mémoire, un spectacle multimédia unique du Vieux-Montréal qui vous plongera dans notre riche histoire.

Montréal est une destination urbaine dynamique, innovatrice et créative. Nous espérons que vous profiterez de votre temps libre pour vous promener dans ses rues dynamiques, faire connaissance avec les locaux, déguster sa cuisine renommée et vous imprégner de sa scène culturelle en constante évolution. L'atmosphère effervescente et le style charmant de notre ville font fondre bien des cœurs, et nous sommes ravis de pouvoir partager ses images et sons avec vous!

On behalf of Tourisme Montréal and our city's tourism industry professionals, I would like to welcome you to Montréal for the Canadian Association of Radiologists 80th Annual Scientific Meeting.

We are honoured that you have chosen Montréal for your prestigious meeting. With its thriving life sciences sector, reputed research community and dynamic network of healthcare professionals, Montréal offers many rich opportunities for sharing, learning and discovery.

Spring here is always buzzing with excitement, and with Montréal's 375th anniversary celebrations going on, there is even more to see and do. As the city freshens up and the flowers start blooming, you can take advantage of the gentler April evenings to go see Cité Mémoire, a unique multimedia show in Old Montréal that immerses you in our rich history.

Montréal is a vibrant, innovative and innately creative urban destination. Make the most of your free time and explore its dynamic streets, get to know the locals, sample its legendary cuisine and soak up its ever-changing cultural scene. It's a city whose spirited ambiance and charming style win hearts over, and we are thrilled to be able to share all its sights and sounds with you!

Yves Lalumière
President and Chief Executive Officer / Président-directeur général
Tourisme Montréal

tourisme / montréal

GENERAL INFORMATION
RENSEIGNEMENTS GÉNÉRAUX

CAR ANNUAL SCIENTIFIC MEETING MISSION STATEMENT

The Canadian Association of Radiologists annual scientific meeting provides collaborative learning opportunities to enhance radiologists' knowledge and competencies in diagnostic and therapeutic medical imaging to help deliver optimal quality health care for patients and the Canadian public at large.

CAR ANNUAL SCIENTIFIC MEETING VISION STATEMENT

The CAR annual scientific meetings are developed to offer the most thorough and progressive professional development opportunities, using traditional and innovative learning methods, for all Canadian radiologists with the aim of supporting them in providing medical imaging care to patients.

MEETING THEME

RADIOLOGY CARE: A VALUE-DRIVEN APPROACH

In seeking to provide patients with optimal healthcare experiences and outcomes, radiologists seek to deliver proficient services in a timely manner and with the most appropriate and advanced equipment and tools. The Canadian Association of Radiologists (CAR) Annual Scientific Meeting (ASM) Working Group has prepared a dynamic scientific program articulated around appropriateness and the use of advanced equipment and tools to help guide therapeutic decision-making and help improve clinical outcomes. Canadian radiologists have expressed an explicit interest in learning more about these topics at past annual meetings and through consultative outreach.

The theme of the 80th ASM is Radiology Care: A Value-Driven Approach. The meeting will cover a broad range of subjects designed for both practicing radiologists and radiologists-in-training. The didactic lectures, panel discussions and hands-on workshops provide a wide variety of formats to enhance every participant's learning experience.

ACCREDITATION

Participants should only claim the credits commensurate with the extent of their participation in the activity.

Canadian Radiologists

The Canadian Association of Radiologists (CAR) 80th Annual Scientific Meeting is an Accredited Group Learning Activity (Section 1) as defined by the Maintenance of Certification (MOC) program of the Royal College of Physicians and Surgeons of Canada (RCPSC) and approved by the CAR for a maximum of **18 credit-hours**.

Participants in the **HRCT of the Chest – A Hands-On Practical Workshop of Diffuse Lung Disease** are eligible to claim a maximum of **9 credit-hours** (3 credits per hour) under Section 3 of the RCPSC MOC program. The RCPSC recording system will automatically convert the credit-hours for this workshop to 3 credits per claimed hour (i.e., 3 hours x 3 credits = 9 credit-hours).

American Radiologists

Through an agreement between the Royal College of Physicians of Surgeons of Canada and the American Medical Association (AMA), physicians may convert Royal College MOC credits to *AMA PRA Category 1 Credits™*. Information on the process to convert Royal College MOC credits to AMA credits can be found at **www.ama-assn.org/go/internationalcme**.

Canadian Technologists

The CAR 80th ASM has also been accredited by the Canadian Association of Medical Radiation Technologists (CAMRT) for **Category A credits**.

CERTIFICATE OF ATTENDANCE

After the event, participating Canadian radiologists will be able to download a fillable PDF to complete their certificate of attendance at **www.car.ca/CAR2017cert.pdf**

Participants can document their learning in the RCPSC MAINPORT portal at **https://login.royalcollege.ca/oamlogin/login.jsp**

LEARNING OBJECTIVES

At the end of the meeting, participants will be able to:

1. Recognize the importance of multidisciplinary consultation in the diagnosis of diffuse lung disease. (CanMEDS roles: Collaborator, Medical Expert)
2. Discuss imaging and treatment of acute ischemic, hemorrahagic stroke and decision-making for brain death. (CanMEDS roles: Communicator, Medical Expert)
3. Describe the key elements of reporting rectal cancer MRI, prostate MRI, and hepatic CT/MR necessary to enhance the value of these studies for clinicians and improve patient care. (CanMEDS roles: Collaborator, Medical Expert)
4. Optimize the technique for bowel and polytrauma imaging in emergency setting. (CanMEDS roles: Medical Expert, Collaborator)
5. Identify strategies to engage in academic activities and contribute to the academic life of a radiology department. (CanMEDS role: Scholar)
6. Identify leading-edge innovations in breast imaging that are having a positive impact on patient-centered care. (CanMEDS role: Health Advocate)
7. Define the role and utilization of advanced technology in clinical imaging. (CanMEDS roles: Communicator, Leader)
8. Discuss the opportunities of big data and artificial intelligence to improve on the diagnostic performance and predictive value of imaging. (CanMEDS roles: Health Advocate, Scholar)
9. Discuss how imaging can help inform therapeutic decision-making that help improve outcomes. (CanMEDS roles: Health Advocate, Leader)
10. Detect, describe, diagnose and provide disposition recommendations for a wide variety of chest and cardiac findings as seen on x-ray, CT and MRI. (CanMEDS roles: Medical Expert, Scholar)
11. Identify and avoid common blind spots, recognize and avoid common misinterpretations in each of the following subspecialties: Cardiac, MSK, Emergency Radiology, Abdominal Imaging (or GU/GI), Neuroradiology and Vascular Pathology. (CanMEDS roles: Professional, Scholar)
12. Discuss the importance of radiologists maintaining an active role on clinical teams. (CanMEDS roles: Collaborator, Health Advocate, Leader, Professional)
13. Discuss the changes that have occurred in imaging over the last two decades to help form an understanding of the changes that may be coming. (CanMEDS roles: Health Advocate, Leader, Professional)
14. Apply a value-based strategy to the radiological management of thoracic disease in the adult pediatric population. (CanMEDS roles: Collaborator, Health Advocate, Medical Expert)

REGISTRATION AND INFORMATION DESK HOURS

Thursday, April 20: 4:00 p.m. – 8:30 p.m.
Friday, April 21: 7:15 a.m. – 6:30 p.m.
Saturday, April 22: 6:30 a.m. – 7:30 p.m.
Sunday, April 23: 7:30 am – 12:45 p.m.

PRESENTATIONS

Unless otherwise indicated under individual sessions, each presentation is scheduled for 30 minutes. Speakers are allotted 25 minutes to present and 5 minutes to answer questions from the audience. Every session has been designed as an educational offering to advance practitioners' professional development and the profession.

ASM EVALUATION FORMS

Your comments and feedback are instrumental in helping us plan future meetings and events.

ONLINE EVALUATIONS

We encourage all participants to fill out the overall meeting and session/speaker evaluations available via the conference app at **www.eventmobi.com/car2017/**

HARD COPY EVALUATION FORMS

The overall meeting evaluation form is included in your registration package. Session and speaker evaluation forms will be available at each session. Completed forms can be returned to the CAR Registration Desk or via fax at 613 860-3112.

DISCLAIMER

No responsibility is assumed by the CAR for any injury and/or damage to persons or property as a matter of product liability, negligence or otherwise, or from any use or operations of any methods, products, instructions or ideas contained in materials distributed or described during presentations throughout the CAR 80th Annual Scientific Meeting. Because of rapid advances in the medical sciences, in particular, independent verification of diagnoses and drug dosages should be made.

Although all advertising material on location and in print is expected to conform to ethical (medical) standards, inclusion in this event does not constitute a guarantee or endorsement of the quality or value of such product or of the claims made of it by its manufacturer and representatives.

SOCIAL EVENTS

All social events will be held at:
Le Centre Sheraton Montreal
1201 René Lévesque Blvd. West
Montreal, Quebec

80TH ANNIVERSARY CELEBRATION COCKTAIL

Come join the celebration as the CAR marks its 80th anniversary! From its humble beginnings in 1937 as a grassroots gathering of Canadian radiologists, to its current pan-Canadian role as the voice of radiologists; come walk through our retrospective of the history of medical imaging in Canada and the CAR itself, and test your knowledge of our Association's past.

Note: due to a conflicting engagement with the Awards Ceremony on Saturday, the CAR will be presenting Dr. Karel ter Brugge with his CAR Distinguished Career Achievement Award during this event.

Friday, April 21
5:00 p.m. – 6:00 p.m.
Salle de bal est, Level 4

CAR WINE & CHEESE RECEPTION AND AWARDS CEREMONY

New this year, the CAR invites **all of its ASM delegates** to join us in celebrating this year's distinguished award winners and this year's successful ASM contest winners at the **CAR Wine & Cheese Reception and Awards Ceremony**. This is a complimentary social event as part of the ASM registration.

CAR Gold Medal Award – Dr. Raquel Z. delCarpio-O'Donovan

CAR Distinguished Career Achievement Award – Dr. Karel ter Brugge (award to be presented in person on Friday at the 80th Anniversary Celebration Cocktail)

CAR Young Investigator Award – Dr. Nicola Schieda

We will also be honouring our many volunteers for their invaluable contributions to the CAR. The CAR exists because of the work they do in the name of radiology in Canada.

Saturday, April 22
5:30 p.m. – 7:15 p.m.
Salle de bal est, Level 4

ELECTRONIC ACCESS

This programme is available electronically at **www.car.ca/prog2017asm.pdf**

The abridged version of the programme is available via the conference app at **www.eventmobi.com/car2017/**

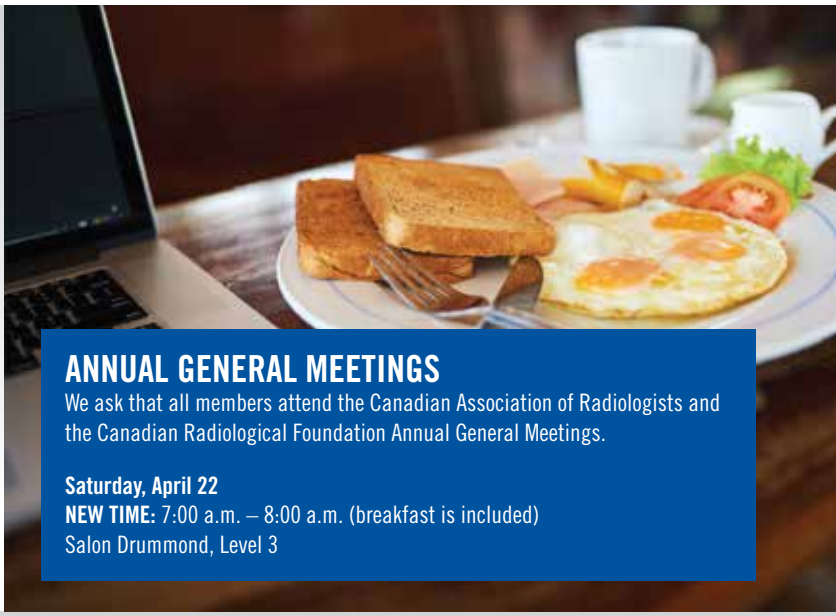

ANNUAL GENERAL MEETINGS

We ask that all members attend the Canadian Association of Radiologists and the Canadian Radiological Foundation Annual General Meetings.

Saturday, April 22
NEW TIME: 7:00 a.m. – 8:00 a.m. (breakfast is included)
Salon Drummond, Level 3

ÉNONCÉ DE MISSION DU CONGRÈS SCIENTIFIQUE ANNUEL DE LA CAR

Le Congrès scientifique annuel de l'Association canadienne des radiologistes (CAR) propose aux radiologistes des occasions de collaboration et d'apprentissage qui enrichiront leurs connaissances et leurs compétences en imagerie médicale à visée diagnostique et thérapeutique, ce qui contribue à la qualité optimale des soins prodigués aux patients et profite à la population canadienne dans son ensemble.

ÉNONCÉ DE VISION DU CONGRÈS SCIENTIFIQUE ANNUEL DE LA CAR

Les congrès scientifiques annuels de la CAR offrent aux radiologistes canadiens des occasions de perfectionnement professionnel rigoureuses et avancées, fondées sur des méthodes d'enseignement traditionnelles et novatrices, afin de les soutenir dans la prestation des soins d'imagerie médicale aux patients.

THÈME DU CONGRÈS

LES SOINS DE RADIOLOGIE : UNE APPROCHE AXÉE SUR LA VALEUR DES SERVICES

Dans le but de fournir aux patients des soins de santé et des résultats optimaux, les radiologistes ont à cœur d'offrir des services efficaces en temps opportun, avec de l'équipement et des outils de pointe. Le groupe de travail du Congrès scientifique de L'Association canadienne des radiologistes (CAR) a conçu un programme scientifique dynamique et opportun s'articulant autour des notions complémentaires de la pertinence et de l'utilisation d'équipement et d'outils de pointe pour guider la prise de décisions thérapeutiques et aider à améliorer les résultats cliniques. Lors des congrès annuels antérieurs et des activités de consultation, les radiologistes canadiens ont exprimé leur intérêt marqué envers le perfectionnement de leurs connaissances des sujets abordés.

Le 80e Congrès scientifique annuel adresse un éventail de sujets tout désignés pour les radiologistes en exercice et les résidents en radiologie. Les présentations didactiques, les débats et les ateliers pratiques forment un heureux mélange de formats qui rehaussera l'expérience d'apprentissage de chaque participant.

HEURES DU BUREAU D'INSCRIPTION ET D'INFORMATION

Jeudi 20 avril: 16 h à 20 h 30
Vendredi 21 avril: 7 h 15 à 18 h 30
Samedi 22 avril: 6 h 30 à 19 h 30
Dimanche 23 avril: 7 h 30 à 12 h 45

AGRÉMENT

Le participant doit réclamer ses unités de formation (crédits) proportionnellement à sa participation à l'activité.

Radiologistes canadiens

Le 80e Congrès scientifique annuel de l'Association canadienne des radiologistes (CAR) est reconnu comme une activité d'apprentissage de groupe (Section 1) par le programme de Maintien du certificat (MDC) du Collège royal des médecins et chirurgiens du Canada (CRMCC), et la CAR approuve donc, au maximum, **18 heures-crédits** dans le cadre de cette activité.

Les participants à **La TDM thoracique à haute résolution : un atelier pratique sur les pneumopathies diffuses** peuvent obtenir, au maximum, **9 heures-crédits** (3 crédits par heure) sous la Section 3 du programme de MDC du CRMCC. Le système de suivis du CRMCC convertira automatiquement chaque heure réclamé pour cet atelier à 3 heures-crédits (c.-à-d., 3 heures x 3 crédits = 9 heures-crédits).

Radiologistes américains

En vertu d'une entente entre le Collège royal des médecins et chirurgiens du Canada (CRMCC) et l'American Medical Association (AMA), les médecins peuvent convertir les crédits du MDC du CRMCC en crédits « *AMA PRA Category 1 Credits 1™* ». Pour de plus amples renseignements relatifs au processus de conversion, visitez le **www.ama-assn.org/go/internationalcme**.

Technologues canadiens

Le 80e Congrès scientifique annuel de la CAR a aussi été agréé par l'Association canadienne des technologies en radiation médicale (ACTRM) pour des **crédits de catégorie A.**

CERTIFICAT DE PARTICIPATION

À l'issue du Congrès, les radiologistes canadiens qui y ont participé pourront télécharger un fichier PDF modifiable afin de préparer leur certificat de participation au **www.car.ca/CAR2017cert.pdf**

Les participants peuvent documenter leur apprentissage par le biais du portail MAINPORT du CRMCC au **https://login.royalcollege.ca/oamlogin/login.jsp**

PRÉSENTATIONS

À moins d'indication contraire, la durée prévue des présentations est de 30 minutes. Les conférenciers ont 25 minutes pour faire leur exposé et 5 minutes pour répondre aux questions des participants. Chaque session de formation offre un contenu éducationnel favorisant le perfectionnement professionnel du praticien et contribuant à l'avancement de la profession dans son ensemble.

FORMULAIRES D'ÉVALUATION DU CONGRÈS

Les commentaires et les observations que vous nous transmettez nous sont d'une aide précieuse pour l'organisation des congrès et des activités à venir. Trois options de rétroaction s'offrent aux participants.

ÉVALUATIONS EN LIGNE

Nous invitons tous les participants à remplir l'évaluation générale sur le congrès ainsi que les évaluations sur les sessions de formation et les conférenciers au moyen de l'application de la conférence. Celle-ci se trouve à l'adresse **www.eventmobi.com/car2017/.**

FORMULAIRES D'ÉVALUATION EN FORMAT PAPIER

Le formulaire d'évaluation générale du congrès se trouve dans votre trousse d'inscription. Les formulaires d'évaluation des sessions de formation et des conférenciers seront remis dans le cadre de chaque activité. Les formulaires dûment remplis peuvent être acheminés au bureau d'inscription de la CAR ou envoyés par télécopieur au 613-860-3112.

AVIS DE NON-RESPONSABILITÉ

La responsabilité de la CAR ne saurait en aucune façon être engagée pour tout préjudice ou dommage aux personnes ou aux biens découlant du fait des produits, de la négligence ou autre, ou encore de l'utilisation ou de l'application de produits, de méthodes, d'instructions ou d'idées contenus lors du 80e Congrès scientifique annuel de la CAR. En raison notamment des progrès rapides du domaine des sciences médicales, un contrôle indépendant des diagnostics et de la posologie devrait être effectué.

Bien que tout matériel publicitaire imprimé et sur les lieux soit tenu de respecter les normes d'éthique (du domaine médical), la présence lors de cet événement de tel matériel ne constitue en rien une garantie, ni ne vient appuyer la qualité ou la valeur des produits ou les promesses du fabricant ou de ses délégués à leur égard.

LES OBJECTIFS D'APPRENTISSAGE

À l'issue du Congrès, les participants seront en mesure de :

1. Reconnaître l'importance de la consultation multidisciplinaire pour le diagnostic des pneumopathies diffuses. (Rôles CanMEDS : collaborateur, expert médical)
2. Discuter de l'imagerie et du traitement des AVC aigus ischémiques hémorragiques et de la prise de décisions liées à la mort cérébrale. (Rôles CanMEDS : communicateur, expert médical)
3. Décrire les éléments clés nécessaires dans les rapports d'IRM pour les cancers du rectum, d'IRM de la prostate et de TDM et IRM du foie pour renforcer la valeur de ces examens pour les cliniciens et améliorer les soins aux patients. (Rôles CanMEDS : collaborateur, expert médical)
4. Optimiser la technique d'imagerie relative aux intestins et aux polytraumatismes dans un contexte d'urgence. (Rôles CanMEDS – expert médical, collaborateur)
5. Établir des stratégies pour participer aux activités du milieu universitaire et contribuer à la vie scolaire d'un département de radiologie. (Rôle CanMEDS : érudit)
6. Déterminer les innovations de pointe en imagerie du sein qui ont des retombées positives pour les soins centrés sur le patient. (Rôle CanMEDS : promoteur de la santé)
7. Définir le rôle et l'utilisation de la technologie de pointe en imagerie clinique. (Rôles CanMEDS : communicateur, leader)
8. Discuter des possibilités offertes par les mégadonnées et l'intelligence artificielle pour améliorer l'efficacité diagnostique et la valeur prédictive de l'imagerie. (Rôles CanMEDS : promoteur de la santé, érudit)
9. Discuter de la façon dont l'imagerie peut aider à prendre des décisions thérapeutiques qui amélioreront les résultats (Rôles CanMEDS : promoteur de la santé, leader)
10. Détecter, décrire et diagnostiquer une grande variété de résultats de radiographies, de TDM et d'IRM thoraciques et cardiaques et faire des recommandations concernant la disposition des images. (Rôles CanMED : expert médical, érudit)
11. Cerner et éviter les zones d'ombre courantes, ainsi que reconnaître et éviter les erreurs d'interprétation courantes propres à chacune des sous-spécialités suivantes : radiologie cardiaque, musculosquelettique et d'urgence, imagerie génito-urinaire et gastro-intestinale, neuroradiologie et affections vasculaires. (Rôles CanMEDS : professionnel, érudit)
12. Discuter de l'importance du rôle actif des radiologistes au sein des équipes cliniques. (Rôles CanMEDS : collaborateur, promoteur de la santé, leader, professionnel)
13. Discuter des changements des 20 dernières années en imagerie pour aider à orienter et à comprendre les changements à venir. (Rôles CanMEDS : promoteur de la santé, leader, professionnel)
14. Adopter une stratégie fondée sur les valeurs pour la prise en charge radiologique des maladies thoraciques chez les patients adultes et pédiatriques. (Rôles CanMEDS : collaborateur, promoteur de la santé, expert médical)

ACTIVITÉS SOCIALES

Toutes les activités sociales auront lieu à l'hôtel suivant :
Le Centre Sheraton Montréal
1201, boulevard René-Lévesque Ouest
Montréal (Québec)

SOIRÉE COCKTAIL DU 80E ANNIVERSAIRE

Joignez-vous aux célébrations marquant le 80e anniversaire de la CAR! Depuis ses modestes débuts en 1937 en tant que simple regroupement de radiologistes canadiens, la CAR est devenue une association pancanadienne agissant comme porte-parole des radiologistes. Venez explorer une rétrospective de l'imagerie médicale au Canada et de la CAR, en plus de mettre à l'épreuve vos connaissances sur l'histoire de l'association.

Remarque : En raison d'un conflit d'horaire avec la cérémonie de remise de prix du samedi, la CAR présentera le Prix d'excellence de la CAR pour une éminente carrière au Dr Karel ter Brugge au cours de cette soirée.

Vendredi 21 avril
De 17 h à 18 h
Salle de bal est, niveau 4

SOIRÉE VINS ET FROMAGES ET REMISE DES PRIX DE LA CAR

Pour la première fois cette année, la CAR convie **tous les délégués du Congrès scientifique annuel à la soirée vins et fromages et remise des prix de la CAR** organisée en l'honneur des lauréats des prix remis cette année et des gagnants des concours du Congrès. Cette activité sociale est offerte gracieusement avec l'inscription au Congrès.

Prix de la Médaille d'or de la CAR – Dre Raquel Z. delCarpio-O'Donovan

Prix d'excellence de la CAR pour une éminente carrière – Dr Karel ter Brugge (prix remis en personne lors de la soirée cocktail du 80e anniversaire)

Prix du jeune chercheur de la CAR – Dr Nicola Schieda

Nous soulignerons également la précieuse contribution des nombreux bénévoles de la CAR. L'association doit son existence au travail qu'ils accomplissent pour la radiologie au Canada.

Samedi 22 avril
De 17 h 30 à 19 h 15
Salle de bal est, niveau 4

ASSEMBLÉES GÉNÉRALES ANNUELLES

Nous demandons à tous les membres d'assister aux assemblées générales annuelles de la CAR et de la Fondation radiologique canadienne.

Samedi 22 avril
NOUVELLE HEURE : de 7 h à 8 h (petit-déjeuner compris)
Salon Drummond, niveau 3

ACCÈS ÉLECTRONIQUE

Ce programme est disponible en format électronique au :
www.car.ca/prog2017asm.pdf

Ce programme est aussi disponible par l'entremise de l'application-conférence :
www.eventmobi.com/car2017/

THE CAR PARTNER PROGRAM
LE PROGRAMME DES PARTENAIRES DE LA CAR

The Canadian Association of Radiologists places tremendous value on the industry partnerships it has cultivated. These partnerships are essential for the CAR in achieving its goal of advancing the profession through leadership in healthcare and excellence in patient care. We would like to extend our sincere gratitude to the following CAR partners and supporter for their leadership and continued support.

L'Association canadienne des radiologistes accorde une extrême importance aux partenariats qu'elle forge dans l'industrie. Aux yeux de la CAR, en stimulant le leadership et en encourageant l'excellence en soins de santé, ces ententes sont essentielles à l'avancement de notre profession. C'est pourquoi nous souhaitons exprimer notre sincère reconnaissance envers les partenaires et le sympathisant de la CAR en considération de leurs qualités de leader et de leur appui constant.

CAR PARTNERS | PARTENAIRES DE LA CAR

BRACCO
LIFE FROM INSIDE

CHRISTIE INNOMED

SIEMENS Healthineers

CAR SUPPORTER | SYMPATHISANT DE LA CAR

AGFA HealthCare

AWARDS OF EXCELLENCE
PRIX D'EXCELLENCE

Canadian Association of Radiologists
L'Association canadienne des radiologistes

2017 CAR GOLD MEDAL AWARD
DR. RAQUEL Z. DELCARPIO-O'DONOVAN

The Canadian Association of Radiologists is pleased to announce that Dr. Raquel Z. delCarpio-O'Donovan has been named the recipient of the 2017 CAR Gold Medal Award.

Dr. delCarpio-O'Donovan is a distinguished neuroradiologist who has had an immensely successful academic career in her 30 years at McGill University. Her unconditional commitment to her profession is evident in her outstanding record of teaching and mentorship. As a teacher, she has helped shape the careers of innumerable radiologists who now practice around the world. Her emphasis on lifelong learning has led to numerous prestigious teaching awards, in addition to having been an Osler Fellow, a McGill University title for mentors to medical students.

During her academic career, she has published 43 peer-reviewed papers, co-authored 6 book chapters, been involved in 23 research projects, and has been an invited speaker at countless national and international meetings. Her reputation as a clinical leader in neuroradiology is evidenced by the sheer number and breadth of her publications and academic endeavours.

Apart from her longstanding involvement with the Canadian Association of Radiologists, Dr. delCarpio-O'Donovan has been a tireless advocate for radiology and neuroradiology at the hospital, university, and provincial level. Additionally, she has been a member of the Council of Physicians, Dentists and Pharmacists, Canadian Radiology Foundation, and has sat on the Education Committee and Specialty Committee in Neuroradiology at The Royal College of Physicians and Surgeons of Canada.

Born in Peru, Dr. delCarpio-O'Donovan has been deeply and actively involved in the development of diagnostic radiology in South America. Further, she has been an advocate for international medical development, demonstrating her statesmanship in the field of diagnostic radiology. Her conciliatory approach to problem solving has made her the ideal ambassador for her profession at home and abroad, as evidenced by her work in supranational societies such as SILAN, CIR, ASNR, and ISMRM.

Dr. delCarpio-O'Donovan has been the recipient of numerous awards and recognitions throughout her career, beginning with an Honorary Mention for her scientific exhibit "High resolution CT scan in the study of the middle ear" in 1982. In 1995, she won the McGill Teacher of the Year award, followed by SILAN Award of Honour for Scientific Excellence (1997), Sociedad Peruana de Radiología Award of Recognition for Teaching (1997), Faculty Honour List for Educational Excellence (1998), and the YMCA Montreal Women of Distinction Award (2003). In 2010 she was named one of the 10 most influential Hispanics in Canada, and Mentor of the Year for Region 4 by the Royal College of Physicians and Surgeons of Canada. In 2013 she received the Prix Professeur Clinicien from the Quebec Medical Association and in 2016 the Gold Medal for Excellence from the Peruvian Radiological Society.

In addition to her outstanding professional commitment and academic honours, Dr. delCarpio-O'Donovan's professionalism, generosity, and kindness have endeared her to her patients and her peers. She is truly a shining light among radiologists in Canada and a role model for young clinicians, particularly women, who aspire to emulate her successful career and record of achievement.

We congratulate Dr. delCarpio-O'Donovan on her extraordinary career, and her seemingly limitless commitment to her chosen profession. For her countless contributions to radiology teaching, research, and international development, we are proud to present Dr. delCarpio-O'Donovan with the 2017 CAR Gold Medal Award.

Tel./Tél. : 613-860-3111 Fax/Téléc. : 613-860-3112 | 600-294 rue Albert Street, Ottawa, Ontario K1P 6E6 CANADA | www.car.ca

PRIX DE LA MÉDAILLE D'OR DE LA CAR 2017
DRE RAQUEL Z. DELCARPIO-O'DONOVAN

L'Association canadienne des radiologistes (CAR) est heureuse d'annoncer la remise du Prix de la Médaille d'or 2017 de la CAR à la Dre Raquel Z. delCarpio-O'Donovan.

La Dre delCarpio-O'Donovan est une éminente neuroradiologiste qui a connu une carrière extrêmement brillante pendant ses 30 années à l'Université McGill. Ses résultats exceptionnels comme enseignante et comme mentor illustrent clairement son engagement inconditionnel envers sa profession. En sa qualité d'enseignante, elle a contribué à orienter la carrière d'un nombre incalculable de radiologistes qui œuvrent maintenant partout dans le monde. L'importance qu'elle accorde à l'apprentissage continu lui a valu de nombreux prix d'enseignement prestigieux. Elle a également été nommée boursière Osler, un titre que l'Université McGill décerne aux mentors d'étudiants en médecine.

Pendant sa carrière universitaire, elle a publié 43 articles évalués par les pairs, corédigé 6 chapitres de livres, participé à 23 projets de recherche et agi comme conférencière dans le cadre d'innombrables rencontres nationales et internationales. La quantité et la portée mêmes de ses publications et de ses projets universitaires attestent sa réputation de chef de file clinique en neuroradiologie.

Outre son engagement de longue date au sein de l'Association canadienne des radiologistes, la Dre delCarpio-O'Donovan a défendu sans relâche les intérêts de la radiologie et de la neuroradiologie auprès des hôpitaux, des universités et des provinces. Elle a aussi été membre du Conseil des médecins, dentistes et pharmaciens et de la Fondation radiologique canadienne en plus de siéger au Comité de l'éducation et au Comité de spécialité en neuroradiologie du Collège royal des médecins et chirurgiens du Canada.

Née au Pérou, la Dre delCarpio-O'Donovan a participé activement à l'essor de la radiologie diagnostique en Amérique du Sud. Elle a également fait la promotion du développement international de la médecine, démontrant sa prééminence dans le domaine de la radiologie diagnostique. Sa façon conciliante de gérer les problèmes en a fait l'ambassadrice idéale de sa profession ici et à l'étranger, comme le prouvent ses travaux pour des organismes supranationaux comme la SILAN, le CIR, l'ASNR et l'ISMRM.

La Dre delCarpio-O'Donovan a reçu de nombreux prix et récompenses tout au long de sa carrière. En 1982, on lui décernait une mention d'honneur pour son exposition scientifique sur les TDM de haute résolution pour l'étude de l'oreille moyenne. En 1995, elle a gagné le prix de l'enseignante de l'année à McGill, puis le prix honorifique pour l'excellence scientifique de la SILAN (1997), le prix de reconnaissance pour l'enseignement de la Sociedad Peruana de Radiología (1997), une nomination sur la Liste des honneurs aux professeurs pour l'excellence en éducation (1998) et le Prix Femmes de mérite de la Fondation Y des femmes de Montréal (2003). En 2010, elle s'est classée parmi les 10 hispanophones les plus influents au Canada et a été nommée Mentor de l'année pour la région 4 par le Collège royal des médecins et chirurgiens du Canada. En 2013, elle a reçu le prix Professeur clinicien de l'Association médicale du Québec, et la Société radiologique du Pérou lui a décerné en 2016 la médaille d'or pour l'excellence.

En plus de démontrer un engagement professionnel exceptionnel et de cumuler les distinctions universitaires, la Dre delCarpio-O'Donovan a gagné l'estime de ses patients et de ses pairs par son professionnalisme, sa générosité et sa gentillesse. C'est un véritable modèle dans la communauté canadienne des radiologistes et un exemple pour les jeunes cliniciens, particulièrement les femmes, qui espèrent vivre une carrière aussi fructueuse et cumuler un bilan de réussites aussi impressionnant.

Nous félicitons la Dre delCarpio-O'Donovan pour sa carrière exceptionnelle et son profond engagement envers la profession qu'elle a choisie. Pour ses innombrables contributions aux domaines de l'enseignement, de la recherche et du développement international en radiologie, nous sommes fiers de remettre à la Dre delCarpio-O'Donovan le Prix de la Médaille d'or de la CAR 2017.

Canadian Association of Radiologists
L'Association canadienne des radiologistes

2017 CAR DISTINGUISHED CAREER ACHIEVEMENT AWARD

DR. KAREL TER BRUGGE

The Canadian Association of Radiologists (CAR) is very proud to present the inaugural CAR Distinguished Career Achievement Award to Dr. Karel ter Brugge. Widely considered the father of interventional neuroradiology in Canada, Dr. ter Brugge is an internationally-acclaimed clinician and researcher, who has dedicated his career to the treatment of adult and pediatric patients with vascular disorders affecting the central nervous system such as brain and spinal arteriovenous malformations, aneurysms and acute stroke. Dr. ter Brugge was among a handful of early innovators who recognized a patient need for specialized intervention, and had the fortitude to bring it to clinical fruition. He and his close collaborator Dr. Pierre Lasjaunias were among the first to highlight the importance of detailed cerebral vascular anatomy and embryology in the practice of interventional neuroradiology.

Born in Holland, Dr. ter Brugge attended medical school at the University of Utrecht, obtained his specialty training in radiology at the University of Toronto, and completed his fellowship training in Neuroradiology at the Montreal Neurological Institute at McGill University. He joined the staff of the Toronto Western Hospital as a neuroradiologist in 1976, and developed a multidisciplinary program in Interventional Neuroradiology at the University of Toronto in 1984. As Professor of Radiology & Surgery at the University of Toronto, Dr. ter Brugge directed Toronto's first course in Vascular Anatomy and Interventional Neuroradiology in 1992.

Dr. ter Brugge was instrumental in the establishment of a strong diagnostic neuroradiology division at the University of Toronto that continues to function across four hospital systems. Together with Dr. Chris Wallace he was the co-founder of what became a highly successful national and international referral center for cerebral vascular disorders at the Toronto Western Hospital. Over the course of his career, Dr. ter Brugge was the Head of the Division of Neuroradiology at the University of Toronto and the JDMI at the University Health Network, Women's College and Mount Sinai Hospitals (1992-2016). He was the inaugural holder of the David Braley and Nancy Gordon Chair in Interventional Neuroradiology at the University of Toronto (2006-2016).

In addition to his clinical and academic leadership, Dr. ter Brugge is recognized as a leading statesman of international neuroradiology organizations. He has served as President of the World Federation of Interventional and Therapeutic Neuroradiology (1999-2001), the Chairman of the second Congress of the WFITN in Vancouver 1993, and the past Secretary General of the World Federation of Neuroradiological Societies (2008-2010). He is the current President of the Canadian Neuroradiological Society.

A prolific scholar, Dr. ter Brugge has over 300 publications in scientific journals and chapters in books. He co-authored with Drs. Lasjaunias and Berenstein the 2nd edition of the three-volume textbook on Surgical Neuroangiography. He is also co-authored with Drs. Krings and Geibprasert the textbooks Case-Based Interventional Neuroradiology and Neurovascular Anatomy in Interventional Neuroradiology. Dr. ter Brugge is the current Editor in Chief of Interventional Neuroradiology, and has decades of professional service as an editor and reviewer for esteemed journals in neuroradiology and interventional neuroradiology.

Dr. ter Brugge is a visionary researcher, clinician, teacher and radiology leader whose relentless energy, focus, and dedication have encouraged hundreds of radiologists to achieve professional excellence. Over the decades he has trained numerous interventional neuroradiologists who now provide service and leadership in centers across Canada, and around the world. He was the inaugural recipient of the Lifetime Achievement Award of the Department of Medical Imaging at the University of Toronto in 2015. In 2016, for his contributions to the development and evolution of interventional Neuroradiology, Dr. ter Brugge became the first radiologist to be recognized with the UHN Global Impact Award, which honours UHN staff members who have changed the world of health and healthcare.

For his long and incomparable career in interventional neuroradiology, his influence on generations of radiology trainees, and his dedication to his profession, we are proud to present Dr. ter Brugge with the 2017 CAR Distinguished Career Achievement Award.

Tel./Tél. : 613-860-3111 Fax/Téléc. : 613-860-3112 | 600-294 rue Albert Street, Ottawa, Ontario K1P 6E6 CANADA | www.car.ca

Canadian Association of Radiologists
L'Association canadienne des radiologistes

PRIX D'EXCELLENCE DE LA CAR POUR UNE ÉMINENTE CARRIÈRE 2017

DR KAREL TER BRUGGE

L'Association canadienne des radiologistes (CAR) est très heureuse de remettre son tout premier Prix d'excellence de la CAR pour une éminente carrière au Dr Karel ter Brugge. Considéré par beaucoup comme le père de la neuroradiologie interventionnelle au Canada, le Dr ter Brugge est un clinicien et un chercheur de renommée internationale qui a consacré sa carrière au traitement de patients de tous âges souffrant de troubles vasculaires qui s'attaquent au système nerveux central tels que les malformations artérioveineuses cérébrales et spinales, les anévrismes et les AVC aigus. Le Dr ter Brugge compte parmi les rares précurseurs à avoir reconnu le besoin d'interventions spécialisées des patients et il a eu le courage de transposer ses convictions dans le contexte clinique. Le Dr ter Brugge et le Dr Pierre Lasjaunias, un proche collaborateur, ont été parmi les premiers à faire valoir l'importance de l'anatomie et de l'embryologie cérébrovasculaires détaillées dans la pratique de la neuroradiologie interventionnelle.

Né en Hollande, le Dr ter Brugge a fréquenté l'école de médecine de l'Université d'Utrecht, a obtenu une spécialisation en radiologie à la University of Toronto et effectué sa formation postdoctorale en neuroradiologie à l'Institut neurologique de Montréal de l'Université McGill. Il s'est joint à l'équipe du Toronto Western Hospital comme neuroradiologiste en 1976 et a mis au point un programme multidisciplinaire de neuroradiologie interventionnelle à la University of Toronto en 1984. En sa qualité de professeur de radiologie et de chirurgie à la University of Toronto, le Dr ter Brugge a donné le premier cours de cet établissement en anatomie vasculaire et en neuroradiologie interventionnelle en 1992.

Le Dr ter Brugge a joué un rôle prépondérant dans la création d'une division de neuroradiologie diagnostique solide à la University of Toronto, qui demeure active dans quatre systèmes hospitaliers. En collaboration avec le Dr Chris Wallace, il a cofondé au Toronto Western Hospital ce qui est devenu un centre spécialisé des troubles cérébrovasculaires, reconnu à l'échelle nationale et internationale. Au cours de sa carrière, le Dr ter Brugge a dirigé les divisions de neuroradiologie de la University of Toronto, du département conjoint d'imagerie médicale de l'hôpital University Health Network (UHN) ainsi que des hôpitaux du Women's College et de Mount Sinai (de 1992 à 2016). Il a été le premier titulaire de la Chaire David Braley et Nancy Gordon en neuroradiologie interventionnelle de la University of Toronto (de 2006 à 2016).

En plus de ses travaux de pointe dans les domaines clinique et universitaire, le Dr ter Brugge est reconnu pour sa prééminence dans les organismes internationaux de neuroradiologie. Il a été président de la World Federation of Interventional and Therapeutic Neuroradiology (WFITN [de 1999 à 2001]), président du deuxième congrès de la WFITN à Vancouver en 1993 et secrétaire-général de la World Federation of Neuroradiological Societies (de 2008 à 2010). Il est actuellement président de la Société canadienne de neuroradiologie.

Universitaire prolifique, le Dr ter Brugge a rédigé plus de 300 chapitres de livres et articles dans des revues scientifiques. Il a corédigé avec les Drs Lasjaunias et Berenstein la deuxième édition du manuel en trois volumes sur la neuroangiographie chirurgicale. Il a également coécrit avec les Drs Krings et Geibprasert les manuels *Case-Based Interventional Neuroradiology* et *Neurovascular Anatomy in Interventional Neuroradiology*. Le Dr ter Brugge est actuellement rédacteur en chef d'*Interventional Neuroradiology*. Pendant plusieurs décennies, il a aussi agi comme rédacteur en chef et réviseur pour des revues prestigieuses en neuroradiologie et en neuroradiologie interventionnelle.

Le Dr ter Brugge est un chercheur, un clinicien, un enseignant et un chef de file visionnaire en radiologie. Son énergie et sa détermination inépuisables ont incité des centaines de radiologistes à atteindre l'excellence professionnelle. Au fil des années, il a formé de nombreux neuroradiologistes interventionnels qui œuvrent maintenant comme intervenants et comme leaders dans des centres partout au Canada et dans le monde. Il a été le premier lauréat du prix Lifetime Achievement Award du département d'imagerie médicale de la University of Toronto en 2015. Ses contributions au développement et à l'évolution de la neuroradiologie interventionnelle ont valu au Dr ter Brugge d'être le premier radiologiste à obtenir en 2016 le prix Global Impact Award de l'UHN qui honore les membres de son personnel qui ont changé le monde de la santé et des soins de santé.

Pour sa longue carrière incomparable en neuroradiologie interventionnelle, son influence sur des générations d'étudiants en radiologie et son engagement envers sa profession, nous sommes fiers de décerner au Dr ter Brugge le Prix d'excellence de la CAR pour une éminente carrière 2017.

Tel./Tél. : 613-860-3111 Fax/Téléc. : 613-860-3112 | 600-294 rue Albert Street, Ottawa, Ontario K1P 6E6 CANADA | www.car.ca

Canadian Association of Radiologists
L'Association canadienne des radiologistes

2017 CAR YOUNG INVESTIGATOR AWARD
DR. NICOLA SCHIEDA

The Canadian Association of Radiologists (CAR) is pleased to announce Dr. Nicola Schieda as the winner of the 2017 CAR Young Investigator Award.

Dr. Schieda has become an authority in renal/adrenal and other areas in genitourinary imaging and has undeniably earned the status of rising star within the radiology community. Upon completing his residency at the University of Ottawa, Dr. Schieda took on a fellowship in abdominal radiology/body MRI at the University of Pennsylvania. He returned to Ottawa in 2012, taking up the position of staff radiologist at The Ottawa Hospital.

Dr. Schieda is regarded as both a reliable colleague and an enthusiastic mentor, earning a remarkable amount of praise from those who come into contact with him, despite having only been in practice for four years. In this short time, he has established himself amongst the staff in the radiology department as a leader in research and clinical practice, he was recently awarded the department's first University of Ottawa sponsored Junior Clinical Research Chair position.

With an impressive publication history, Dr. Schieda has authored or co-authored over 70 peer-reviewed articles in high impact imaging journals, including: the American Journal of Roentgenology, Radiology, European Radiology and the Journal of Magnetic Resonance Imaging. These accomplishments are highlighted by his recent appointment to the editorial board of European Radiology in MRI. A testament to his dedication to quality research and the potential clinical application of his research, Dr. Schieda collaborates with radiation oncologists, urologists, and pathologists routinely in clinical and research endeavours. His collaborative approach to research is highlighted by joint publication with his colleagues in non-imaging journals.

As the recipient of grants from the Canadian Heads of Academic Radiology and from The Ottawa Hospital Academic Medical Organization, among others, it is undeniable that Dr. Schieda's work has distinguished him within his field. Particularly, his role as Director of Abdominal and Pelvic MRI at The Ottawa Hospital has established their program as one of the leaders in Body MRI in Canada.

What sets Dr. Schieda apart from his peers is the time he invests in the next generation – no other staff member has supervised and mentored more radiology trainees, including residents or fellows in abdominal imaging during his time at the University of Ottawa. He devotes tremendous effort to help his trainees improve their skills in areas such as literature review, research methodology, oral presentations and manuscript writing, making him an indispensable faculty member.

We are delighted to honour him with this year's CAR Young Investigator Award.

PRIX DU JEUNE CHERCHEUR DE LA CAR 2017
DR NICOLA SCHIEDA

L'Association canadienne des radiologistes (CAR) est heureuse d'annoncer la remise du Prix du jeune chercheur de la CAR 2017 au Dr Nicola Schieda.

Le Dr Schieda est devenu une sommité dans le domaine de l'imagerie des reins, des glandes surrénales et des autres éléments du système génito-urinaire et a indéniablement mérité le statut d'étoile montante dans la communauté de la radiologie. Après sa résidence à l'Université d'Ottawa, il a obtenu une bourse de recherche en radiologie de l'abdomen/IRM du corps à la University of Pennsylvania. Il est retourné à Ottawa en 2012 pour occuper un poste de radiologiste à l'Hôpital d'Ottawa.

Le Dr Schieda est perçu comme un collègue fiable et un mentor enthousiaste, suscitant un remarquable cortège d'éloges de la part de ceux qui l'ont côtoyé bien qu'il ne pratique que depuis quatre ans. Pendant cette courte période, il s'est imposé dans le département de radiologie comme chef de file en recherche et en pratique clinique. Il a récemment obtenu la première Chaire de recherche clinique junior du département, financée par l'Université d'Ottawa.

Le Dr Schieda a déjà beaucoup de publications à son actif : il a rédigé, seul ou avec d'autres, plus de 70 articles évalués par les pairs dans des revues d'imagerie influentes dont l'*American Journal of Roentgenology, Radiology, European Radiology* et le *Journal of Magnetic Resonance Imaging*. Ces réalisations lui ont récemment valu d'être nommé au comité éditorial responsable de l'IRM pour *European Radiology*. Preuve de son engagement envers des recherches de qualité et leurs applications cliniques potentielles, le Dr Schieda collabore régulièrement avec des radio-oncologues, des urologues et des pathologistes dans le cadre de ses projets de recherche et cliniques. Ses publications conjointes avec ses collègues dans des revues portant sur des sujets autres que l'imagerie témoignent de sa vision collégiale de la recherche.

Les travaux du Dr Schieda lui ont incontestablement permis de se distinguer dans son domaine, comme le prouvent les bourses qui lui ont été décernées par la Canadian Heads of Academic Radiology et l'Ottawa Hospital Academic Medical Organization, entre autres. Il a notamment permis, à titre de directeur du programme d'IRM de l'abdomen et du pelvis de l'Hôpital d'Ottawa, de placer ce programme parmi les meilleurs au Canada en IRM du corps.

Ce qui distingue le Dr Schieda de ses pairs est le temps qu'il consacre à la prochaine génération. Aucun autre membre du personnel n'a supervisé et encadré plus d'étudiants en radiologie, entre autres des résidents et des boursiers en imagerie de l'abdomen, qu'il ne l'a fait pendant son séjour à l'Université d'Ottawa. Il déploie énormément d'efforts pour aider ses stagiaires à améliorer leurs compétences dans des domaines tels que la revue de la littérature, la méthodologie de recherche, les présentations orales et l'écriture manuscrite, ce qui fait de lui un membre indispensable du corps enseignant.

Nous sommes ravis de lui décerner cette année le Prix du jeune chercheur de la CAR.

AGENDA
SOMMAIRE DU PROGRAMME

THURSDAY, APRIL 20, 2017

16:00	Registration Opens (Fourth Floor)
17:45 – 18:45	Opening Cocktail (Fourth Floor Foyer)
18:45 – 19:00	**80 Years of CAR – Jonathon Leipsic** (Salle de bal ouest)
19:00 – 19:45	**Opening Lecture: Changing Acute Stroke: A Journey – Mayank Goyal** (Salle de bal ouest)
19:45 – 20:30	**Feature Lecture: Empathy and Patient Engagement in 21st-Century Radiology – Brian Goldman (CBC Radio Host: White Coat, Black Art)** (Salle de bal ouest)

FRIDAY, APRIL 21, 2017

08:00 – 17:00	Scientific and Educational Exhibits (Electronic Presentations) (Fourth Floor Foyer)
06:45 – 07:30	**NEW – 5K Fun Run** (Hotel Lobby)
07:30 – 08:00	Breakfast – Exhibit Hall
08:00 – 08:40	**Plenary: Rethinking Stroke Imaging in Light of Recent Evidence – Mayank Goyal** (Salle de bal ouest)
08:40 – 08:55	**Welcoming Address: William Miller, President of the CAR** (Salle de bal ouest)

Track Title *Moderator(s)* (Location)	**Radiology Care: A Value-Driven Approach (Neuro)** *Jai J. Shankar* (Salle de bal ouest)	**Departmental Clinical Audit Projects Contest** *Bruno Morin* (Salon Jarry / Joyce – Level A)	**Employment and Retirement** *Edward Lyons* (Salle de bal est)
09:00 – 09:30	Values Need Connections to Reality: The Role of Research in Clinical Care – *Jean Raymond*	Judges: *Sukhvinder Dhillon* *Najla Fasih* *Reza Forghani*	The Radiologist Was Once an Integral Member of the Health Care Team – *Edward Lyons* **(9:00 – 9:15)**
09:30 – 10:00	Advanced Imaging of Cerebral and Spinal Vascular Malformations – *Frédéric Clarençon*		A Radiologist's View of Retirement – *David Vickar* **(9:15 – 9:30)** Building the Right Retirement Plan for You – *Danny Caccavelli* **(9:30 – 9:50)** Questions & Answers Period **(9:50 – 10:00)**
10:00 – 10:30	Imaging in Brain Death – *Jai J. Shankar*		Speaking Out or Being Outspoken: The Difference Between Responsible and Disruptive Behaviour in Radiology – *Tino Piscione*

10:30 – 10:50 Nutrition Break

Track Title *Moderator(s)* (Location)	**Radiology Care: A Value-Driven Approach (Thoracic)** *Carole Dennie* (Salle de bal ouest)	**The Challenges and Opportunities in Undergraduate Medical Education** *David Barnes* (Salle de bal est)
10:50 – 11:20	Pre-Operative CT-Guided Microcoil Lung Nodule Localization: Our Added Value – *Elsie Nguyen*	Collaborating with Anatomists: The Future of Pre-Clinical Radiology – *Bruce Forster* **(10:50 – 11:10)** Ultrasound in Undergraduate Medical Education: A Tale of Two Programs – *Heather Curtis & Petter Tonseth* **(11:10 – 11:30)**
11:20 – 11:50	The Radiologist: Art Critic or Consultant in Patient Care? – *Erika Mann*	Radiology Electives: Strategies to Improve the Student Experience – *Ning Su* **(11:30 – 11:50)**
11:50 – 12:20	Transforming Lung Cancer Referrals: Ensuring a Value-Added Service – *Carole Dennie*	National Radiology Curriculum for Undergraduate Medicine – *Elsie Nguyen* **(11:50 – 12:10)** Questions & Answers Period **(12:10 – 12:20)**

12:20 – 13:25 Lunch – Exhibit Hall

Track Title *Moderator(s)* (Location)	Radiology Care: A Value-Driven Approach (GU / GI) *Iain Kirkpatrick* (Salle de bal ouest)	CAR Radiologists-in-Training Contest *Gilles Bouchard* (Salon Jarry / Joyce – Level A)	MSK: Sports Injuries *Robert Bleakney* (Salle de bal est)
13:30 – 14:00	Bottoms Up! Pitfalls and Pearls in Rectal MRI: What the Radiologist Needs to Know in 2017 – *Zahra Kassam*	Judges: *Marco Essig* *Faisal Khosa* *Mark Levental*	Sports MRI of the Hip and Groin – *Robert Bleakney*
14:00 – 14:30	PI-RADS V2: What You Need to Know – *Iain Kirkpatrick*		Current Concepts: Imaging the Shoulder and Elbow in Athletes – *Tom Powell*
14:30 – 15:00	Liver Imaging Reporting and Data System (LI-RADS): What You Need to Know – *Chris Lindquist*		Not Uncommon Foot and Ankle Diagnoses for the General Radiologist – *Thomas Mammen*
15:00 – 15:25	Nutrition Break		

Track Title *Moderator(s)* (Location)	Radiology Care: A Value-Driven Approach (Emergency Radiology) *Adnan Sheikh* (Salle de bal ouest)	CAR Radiologists-in-Training Contest *Gilles Bouchard* (Salon Jarry / Joyce -Level A)	Development of Academic Life *An Tang* (Salle de bal est)
15:30 – 16:00	Role of the ER Section in a Radiology Department – *Savvas Nicolaou*	Judges: *Marco Essig* *Faisal Khosa* *Mark Levental*	A Primer on Effective Abstract Writing – *Peter Munk*
16:00 – 16:30	Polytrauma: Is it Always Whole-Body CT? – *Ferco Berger*		How to Optimize Research Publication Probability! – *Matthew McInnes*
16:30 – 17:00	Differentiation of Bowel Ischema – *Timothy O'Connell*		Tips to Obtain a First Peer-Review Research Grant – *An Tang*
17:00 – 18:00	80th Anniversary Celebration Cocktail		
18:30 – 20:00	Reception for Radiologists-in-Training		

SATURDAY, APRIL 22, 2017

08:00 – 17:00	Scientific and Educational Exhibits (Electronic Presentations – Fourth Floor Foyer)
07:00 – 08:00	NEW TIME – CAR / CRF Annual General Meetings – Breakfast (Salon Drummond)
08:00 – 08:40	**Plenary: Radiologic-Pathologic Correlation of Polycystic Kidney Disease and Other Ciliopathies – Ellen Chung** (Salle de bal ouest)

Track Title *Moderator(s)* (Location)	Advanced Technologies: CT *Khashayar Rafatzand* (Salle de bal ouest)	HRCT of the Chest: A Hands-on Practical Workshop of Diffuse Lung Disease *Daria Manos, Carolina Souza*	Post-Residency Panel *Cameron Hague* (Salle de bal est)
08:45 – 09:15	Recent Advancements in Cardiac CT – *Karl Sayegh*	*Ana-Maria Bilawich, Joy Borgaonkar, Ashish Gupta, João Inácio, Daria Manos, Anastasia Oikonomou, Carolina Souza, Marie-Michèle Thériault* **Intensive hands-on experience reviewing and interpreting cases** **(Pre-registration required)**	Preparing for Your First Year Out of Residency: Tips and Tricks *Jason Clement* *Mario Kontolemos* *Jonathan Scheske* *Lisa Smyth*
09:15 – 09:45	Dual Energy CT: Principles, Technology, and Clinical Applications – *Rajiv Gupta*		
09:45 – 10:15	Latest Advancements in CT Scan Technology – *Khashayar Rafatzand*		
10:15 – 10:40	Nutrition Break		

Track Title *Moderator(s)* (Location)	Imaging Complications of Oncological Therapy and MR Elastography *Tanya Chawla* (Salle de bal ouest)	HRCT of the Chest: A Hands-on Practical Workshop of Diffuse Lung Disease *Daria Manos, Carolina Souza*	Resident Review: Thoracic Imaging, Part 1 *Cameron Hague* (Salle de bal est)
10:45 – 11:15	Liver Magnetic Resonance Elastography: Concepts and Applications – *An Tang*	*Ana-Maria Bilawich, Joy Borgaonkar, Ashish Gupta, João Inácio, Daria Manos, Anastasia Oikonomou, Carolina Souza, Marie-Michèle Thériault* **Intensive hands-on experience reviewing and interpreting cases** **(Pre-registration required)**	How Do I Approach Cardiac MR? – *Elena Peña*
11:15 – 11:45	Oncology Complications in Neuroradiology – *Jeremy Rempel*		The Chest X-Ray: What You Need to Know – *Lisa Smyth*
11:45 – 12:15	Imaging the Complications of Oncological Therapy in the Abdomen – *Tanya Chawla*		Game-Changing Cardiac Cases – *Jonathan Scheske*

12:15 – 13:25 Lunch – Exhibit Hall

Track Title *Moderator(s)* (Location)	**Advanced Technologies: Novel Technologies** *Frank Rybicki* (Salle de bal ouest)	**Controversies in Radiology** *Mark Levental, Michael Patlas* (Salon Drummond)	**Resident Review: Thoracic Imaging, Part 2** *Cameron Hague* (Salle de bal est)
13:30 – 14:00	Determining Risk of Myocardial Infarction from Cardiac CT: Unlocking the Power of Artificial Intelligence – *Will Guest*	Imaging of the Acute Abdomen: Oral Contrast a Must – *Michael Patlas*	Cardiac CT: Beyond the Coronary Arteries – *João Inácio*
14:00 – 14:30	The Role of the Radiologist in 3D Printing – *Frank Rybicki*	Controversies in Femoroacetabular Impingement – *Kawan Rakhra*	The Mediastinum – *Giselle Revah*
14:30 – 15:00	Software Development, Implementation, and Outcomes for Measuring Radiologist Productivity in a Canadian Radiology Department – *Cynthia Walsh*	Controversies and Opportunities in the Diagnosis of Endometriosis – *Margaret A. Fraser*	Diffuse Air Space Disease – *Daria Manos*

15:00 – 15:25 Nutrition Break

Track Title *Moderator(s)* (Location)	**CAR Hot Topics** *André Picard* (Salle de bal ouest)	**Breast Imaging** *Jean Seely* (Salon Drummond)	**Junior Hot Seat Session for Residents** *Cameron Hague* (Salon 4)	**Senior Hot Seat Session for Residents** *Cameron Hague* (Salon 5)
15:30 – 16:00	Fiscal Pressures on Healthcare in Quebec – *Gaétan Barrette* **(15:30 – 15:55)**	Radioactive Seed Localization: Practical Tips for Starting the Program – *Jean Seely*	Junior Hot Seat Session for Residents (PGY-1, 2 and 3) *(Angus Hartery, Marie-Hélène Lévesque)*	Senior Hot Seat Session for Residents (PGY-3, 4 and 5) *(Julie Hurteau-Miller, Jonathan Scheske)*
16:00 – 16:30	Access to Healthcare in Canada and How Canada Ranks Compared to the Rest of the World – *Brian Day* **(15:55 – 16:20)**	Breast Tomosynthesis in Practice: Early Experience with Screening and Diagnosis – *Shiela Appavoo*		
16:30 – 17:00	Questions and Answers Period **(16:20 – 17:00)**	Breast MRI: Recent Advances – *Lara Richmond*	**Pre-registration required (Reserved Tickets)**	**Pre-registration required (Reserved Tickets)**

17:30 – 19:15 NEW – Wine & Cheese Reception and Awards Ceremony (Salle de bal est)

SUNDAY, APRIL 23, 2017

07:30 – 08:00 Breakfast (Salle de bal centre)

08:00 – 08:40 Plenary: CMPA – Mobile Device Use in Clinical Practice: Opportunities and Realities – Tino Piscione (Salle de bal ouest)

Track Title *Moderator* (Location)	**Mistakes We All Make** *Caitlin McGregor* (Salle de bal ouest)
08:45 – 09:15	Neuroradiology – *Carlos Torres*
09:15 – 09:45	Emergency Radiology – *Faisal Khosa*
09:45 – 10:15	Improving MSK Interpretation Prowess – *Dean Bruce*
10:15 – 10:40	Nutrition Break
10:45 – 11:15	Abdominal Imaging – *Angus Hartery*
11:15 – 11:45	Making the Black Box of the Heart More Transparent – *Elena Peña*
11:45 – 12:15	Vascular Imaging and Intervention – *Jason Clement*

PRESENTATIONS
PRÉSENTATIONS

SPECIAL PRESENTATION — THURSDAY, APRIL 20, 2017

80 YEARS OF CAR

Dr. Jonathon Leipsic
18:45–19:00
Salle de bal ouest

This presentation is a 15-minute didactic lecture.

PRESENTATION SUMMARY: The audience will be taken on a journey through the rich 80-year history of the CAR: the successes and accomplishments, but also the challenges it has faced and continues to face.

LEARNING OBJECTIVES: At the end of the presentation, participants will be able to:

1. Provide a historical perspective of the organization.
2. Consider CAR's journey through the advancements in imaging over the last 80 years.
3. Predict what the future in diagnostic imaging may bring in the next 50 years.

OPENING LECTURE — THURSDAY, APRIL 20, 2017

CHANGING ACUTE STROKE: A JOURNEY

Dr. Mayank Goyal
19:00–19:45
Salle de bal ouest

This presentation will be 35 minutes, followed by a 10-minute interactive question period.

PRESENTATION SUMMARY: After the failure of IMS3 in 2013, the future of endovascular treatment of acute stroke seemed dismal. However, through this failure came learning opportunities. Using these learnings, there were recently five positive trials (all published in NEJM). This led to a revolution in acute stroke treatment and change in guidelines around the world. The degree of benefit from this treatment was shown to be tremendous.

In the treatment of acute stroke: time is brain. This is not only intuitively obvious but is backed by extensive data. These data will be discussed. Strategies to improve workflow and make stroke workflow more efficient will be discussed in detail.

These recent changes in acute stroke care have presented many challenges and opportunities for the near future. Key challenges and potential solutions will be discussed. Opportunities and future research directions will be presented.

LEARNING OBJECTIVES: At the end of this presentation, participants will be able to:

1. Identify and review a historical perspective of the challenges of acute stroke treatment and steps to overcome these.
2. List up-to-date current evidence that led to the recent changes in standard of care for acute stroke treatment.
3. Ponder on future challenges, opportunities, research and clinical directions.

FEATURE LECTURE — THURSDAY, APRIL 20, 2017

EMPATHY AND PATIENT ENGAGEMENT IN 21st-CENTURY RADIOLOGY

Dr. Brian Goldman
19:45–20:30
Salle de bal ouest

This presentation will be 35 minutes, followed by a 10-minute interactive question period.

PRESENTATION SUMMARY: Radiologists are increasingly being called upon to provide direct patient care, which necessitates reconnecting with patients and their families. The empathic response was once considered a core competence of practicing physicians. Time pressure, distraction, complexity of illness and increased litigation have reduced the time available to build the doctor–patient relationship. Empathy has been devalued in the culture of modern medicine. Lack of empathy between doctor and patient and between allied health professionals leads to medical errors, erodes the trust between radiologist and patient, and leads to burnout, depression and emotional distress. Contrary to widespread belief, the empathic response can be taught. Taking the patient and family perspective leads to stronger radiologist–patient relations, and can lead to concrete improvements in health care.

LEARNING OBJECTIVES: At the end of this presentation, participants will be able to:

1. Identify systemic and professional factors that inhibit the empathic response in radiologist–patient relationships.
2. Establish the importance of the empathic response and the growing role of radiologists in direct patient care.
3. Demonstrate how to extend the empathic response to patients and give concrete examples of the empathic response in the care of patients.

MORNING TRACKS — FRIDAY, APRIL 21, 2017

BREAKFAST
07:30–08:00: EXHIBIT HALL

PLENARY SESSION: RETHINKING STROKE IMAGING IN LIGHT OF RECENT EVIDENCE

Dr. Mayank Goyal
08:00–08:40
Salle de bal ouest

This presentation will be 30 minutes, followed by a 10-minute interactive question period.

PRESENTATION SUMMARY: Multiple recent, randomized, controlled trials led to changes in treatment guidelines for acute ischemic stroke due to large vessel occlusion. In addition, there is an ever-increasing amount of data showing the importance of time and efficiency. Imaging is critical to decision making. This includes not only timely interpretation but also short and timely acquisition of data and contemporaneous post-processing. Data related to various imaging options will be presented and the pros and cons of various imaging techniques will be discussed. Future challenges and opportunities will also be discussed.

LEARNING OBJECTIVES: At the end of this presentation, participants will be able to:

1. Review the background evidence regarding acute stroke treatment.
2. Appraise the need for speed.
3. Analyze the pros and cons of different imaging techniques.

WELCOMING ADDRESS — FRIDAY, APRIL 21, 2017

Dr. William Miller, President of the Canadian Association of Radiologists
08:40–08:55
Salle de bal ouest

RADIOLOGY CARE: A VALUE-DRIVEN APPROACH (NEURO)

09:00–10:30
Salle de bal ouest
Moderator: Dr. Jai J. Shankar

VALUES NEED CONNECTIONS TO REALITY: THE ROLE OF RESEARCH IN CLINICAL CARE

Dr. Jean Raymond 09:00–09:30

PRESENTATION SUMMARY: Diagnostic imaging is practical. The diagnostician must render a judgment for each case. This exacting task is essential to personalized medical care, but validation of reproducibility is crucial to objectivity. Objectivity in radiology is the identification of a condition ('the same thing') at different times by the same observer, or the recognition of the same condition in the same individual by different radiologists, or in different individuals by different radiologists. How imaging performs in consistently answering clinical questions should be an important part of radiology research (and education). The clinical value of any medical intervention, including diagnostic imaging studies, should ultimately be measured by effects on patient outcomes using the randomized trial methodology. That methodology still needs to be better adapted to the evaluation of clinical imaging practices—a work in progress.

Multiple research opportunities remain, and should increasingly focus on the reliability of everyday diagnoses. Contemporary methods to store and communicate images have simplified collaboration. Networks of individuals working on explicit diagnostic categories and on precise methodology should increasingly report their work in articles dedicated to agreement and other neglected aspects of clinical imaging research.

LEARNING OBJECTIVES: At the end of this presentation, participants will be able to:

1. Differentiate good outcomes from good intentions.
2. Identify which area of their practice would benefit from clinical research.
3. Integrate clinical research methods in their clinical practice.

ADVANCED IMAGING OF CEREBRAL AND SPINAL VASCULAR MALFORMATIONS

Dr. Frédéric Clarençon 09:30–10:00

PRESENTATION SUMMARY: Intra-cranial and spinal cord vascular malformations may be responsible for bleeding or for neurological deficits, potentially leading to severe sequelae. Their angio-architecture is often difficult to understand with regular imaging techniques (CT angiography, MR angiography, or even 2D DSA).

New MRI acquisitions such as the SWAN, time-resolved MRA or ASL perfusion acquisitions may help to accurately depict intra-cranial vascular malformations. 4D CTA as well as time-resolved MRA may also be helpful for the imaging work-up of spinal cord vascular malformations.

New algorithms applied on 3D rotational angiography such as segmentation or anamorphosis algorithms may help to improve the understanding of the brain AVMs' angio-architecture.

These new imaging techniques may help to select the vascular malformations that require aggressive treatment, to plan the treatment if required, and to reduce the complication rate.

LEARNING OBJECTIVES: At the end of this presentation, participants will be able to:

1. Assess the new imaging techniques to depict intra-cranial vascular malformations.
2. Appraise advanced imaging techniques to plan the treatment of intra-cranial vascular malformations.
3. Detect the advanced imaging techniques that may help to understand the angio-architecture of spinal cord vascular malformations.

IMAGING IN BRAIN DEATH

Dr. Jai J. Shankar 10:00–10:30

PRESENTATION SUMMARY: Brain death confirmation with ancillary testing is highly variable depending on the institution, region, and country of practice. The common denominator that must be established with all ancillary tests for confirmation of brain death is a lack of whole brain cerebral blood flow. Computed tomography perfusion (CTP) is a relatively recent ancillary test that is capable of deriving functional data regarding small vessel perfusion of the whole brain as well as that specific to the brainstem. Clinically, the operational definition of death now includes permanent loss of brainstem function. The purpose of this research was to demonstrate the utility of CTP and its capability in potentially diagnosing brain death compared with other ancillary tests.

LEARNING OBJECTIVES: At the end of this presentation, participants will be able to:

1. Discuss the definition of brain death.
2. Identify the current guidelines for ancillary imaging test for brain death.
3. Discuss the recent development in ancillary imaging test for brain death–role of CT perfusion.

DEPARTMENTAL CLINICAL AUDIT PROJECTS CONTEST

09:00–10:30
Salon Jarry & Joyce, Level A
Moderator: Dr. Bruno Morin
Judges: Dr. Sukhvinder Dhillon, Dr. Najia Fasih, Dr. Reza Forghani

The following abstracts will be presented orally. Refer to the Abstracts section on page 81 for the full abstracts.

Les abrégés suivants seront présentés oralement. Veuillez consulter la section des résumés d'expositions à la page 81 pour en faire la lecture complète.

Each presentation will be 8 minutes, followed by a 2-minute interactive question period.

09:00 – AP001
Pre-MRI Patient Questionnaire: Clinical Audit – *Navdeep Sahota*

09:10 – AP002
Quality Initiative Project Assessing the Impact of TIRADS on Net Number of Thyroid Biopsies and Adherence of TIRADS-Reporting by Radiologists – *Tetyana Maniuk*

09:20 – AP003
Pulmonary Computed Tomography Angiography in the Diagnosis of Acute Pulmonary Embolism: An Assessment of Prevalence and Use – *Zhongyi Chen*

09:30 – AP004
CT Pulmonary Angiography Audit – *Ibraheem Afzal*

09:40 – AP005
Hepatic Artery Pseudoaneurysm Embolization – *Patrick Kennedy*

09:50 – AP006
Reduced Inter-patient Variability in Hepatic Enhancement at Abdominal CT Using Lean Body Weight for Intravenous Contrast Dosing – *Kris A. Peet*

10:00 – AP007
Getting to Zero: A Quality Assessment of Multiple Interventions Aimed to Reduce Cancellation Rates in an Ultrasound-Guided Biopsy Program – *Stephanie Kenny*

10:10 – AP008
Compliance with Recommended Follow-up for Incidental Pulmonary Nodules Found on CT Chest Studies – *Ankur Goel*

10:20 – AP009
PICA and Pericallosal Artery Origin Inclusion in Magnetic Resonance Angiography with Time-of-Flight Technique for Aneurysm Screening and Surveillance – *Mitchell P. Wilson*

EMPLOYMENT AND RETIREMENT

09:00–10:30
Salle de bal est
Moderator: Dr. Edward Lyons

The three presentations from 9:00 a.m. to 9:50 a.m. will be followed by a 10-minute interactive question period.

THE RADIOLOGIST WAS ONCE AN INTEGRAL MEMBER OF THE HEALTH CARE TEAM

Dr. Edward Lyons 09:00–09:15

PRESENTATION SUMMARY: Digital imaging was introduced in the mid-1990s, and with it came Picture Archive and Communications System (PACS) archiving, communication and storage, and the end of film use in America. This also heralded the beginning of the end for the radiologist as an integral member of the health care team.

Before PACS, film was the ONLY record of the imaging exam, and the radiologist had the films. Every day the clinicians came with their patient list to their radiologist/resident to discuss the results of the study in light of the current clinical situation. They agreed on any additional imaging to aid in patient care. The radiologist's advice was sought and respected. The radiologist WAS a member of the team.

Today clinicians review images on PACS anywhere and often do not know which radiologist to consult or where to find them. Reports are generated within hours from anywhere. The focus is too often on productivity at the expense of accessibility.

Computer-based pattern recognition and artificial intelligence integration can seem to put the radiologist at risk. The risk exists if their only role—real or perceived—is to provide image interpretation.

The challenge is for the radiologist to once again re-establish his/her role as a consultant and a true and integral "member of the health care team."

The message is "Pick a team and become an integral member."
Make a difference.

LEARNING OBJECTIVES: At the end of this presentation, participants will be able to:

1. Assess their current and potential individual role as a member of the health care team.
2. Analyze their current and potential direct impact on patient care.
3. Instil a commitment to changing the role of the radiologist from passive to active.

A RADIOLOGIST'S VIEW OF RETIREMENT

Dr. David Vickar 09:15–09:30

PRESENTATION SUMMARY: The decision of how and when to retire is not as simple as one might believe. Advanced planning for the individual radiologist and the group practice is essential to the future well-being of both parties. The human resource landscape is constantly changing along with general societal considerations, and what was considered the norm for previous generations does not necessarily apply to the present. These issues will be discussed to consider transition from the full-time workforce to life beyond those years.

LEARNING OBJECTIVES: At the end of this presentation, the participants will be able to:

1. Consider the need for advanced preparation for retirement.
2. Accept that "it is not all about finances."
3. Identify the radiologist human resources status as of 2016.
4. Consider and value the benefit of the radiologist nearing retirement to the group practice and the greater medical community.

BUILDING THE RIGHT RETIREMENT PLAN FOR YOU

Danny Caccavelli 09:30–09:50

PRESENTATION SUMMARY: Many physicians wonder how to plan for retirement and what the retirement phases will look like. In this moving environment and with all the changes physicians face in the health system, they don't need uncertainty and insecurity around their retirement plan. A good place to start is by establishing objectives, developing a plan and monitoring it. In this session, you will learn more about these steps and how to adapt them to your situation.

LEARNING OBJECTIVES: At the end of this presentation, participants will be able to:

1. Identify and prioritize retirement goals.
2. Analyze one's current situation.
3. Develop, implement, monitor and review a retirement plan.

EMPLOYMENT AND RETIREMENT (CONTINUED)

09:00–10:30
Salle de bal est
Moderator: Dr. Edward Lyons

SPEAKING OUT OR BEING OUTSPOKEN: THE DIFFERENCE BETWEEN RESPONSIBLE AND DISRUPTIVE BEHAVIOUR IN RADIOLOGY

Dr. Tino Piscione 10:00–10:30

PRESENTATION SUMMARY: Disruptive behaviour generally refers to inappropriate conduct, whether in actions or in words, that interferes with or has the potential to interfere with quality health care delivery. However, not all instances of behaviour that may initially seem inappropriate are actually disruptive. An important distinction can be made between speaking out professionally to advocate for safe and reliable patient care or for just distribution of resources and being outspoken and unprofessional in behaviour and tone. In this session, the impact of unprofessional physician behaviour and communication on reliable health care delivery will be highlighted. Clinical scenarios relevant to radiologists and based on actual CMPA case files will be used to illustrate the difference between disruptive conduct and quality health care advocacy. Skills and strategies for voicing concerns about patient safety and reliable medical care both effectively and professionally will be presented for consideration.

LEARNING OBJECTIVES: At the end of this presentation, the participants will be able to:

1. Discuss the impact of unprofessional physician behaviour and communication on delivering quality clinical care.
2. Identify skills required for professional communication between radiologists and other consulting physicians.
3. Describe three approaches to effectively voice concerns about patient safety and/or appropriate use of resources.

RADIOLOGY CARE: A VALUE-DRIVEN APPROACH (THORACIC)

10:50–12:20
Salle de bal ouest
Moderator: Dr. Carole Dennie

PRE-OPERATIVE CT-GUIDED MICROCOIL LUNG NODULE LOCALIZATION: OUR ADDED VALUE

Dr. Elsie Nguyen 10:50–11:20

PRESENTATION SUMMARY: This presentation will provide an overview of pre-operative lung nodule localization techniques and describe the advantages and limitations of the microcoil technique. The modification of the original technique where the visceral pleura is not marked by the microcoil will be described with its advantages of reduced procedure and CT fluoroscopy time. With microcoil lung nodule localizations, the radiologist can help reduce operating room time, patient complications and hospital length of stay as compared to open lobectomy.

LEARNING OBJECTIVES: At the end of this presentation, participants will be able to:

1. Describe the CT-guided microcoil technique.
2. List five other options for pre-operative lung nodule localization.
3. Describe how the radiologist can help improve patient care by shortening operating room time, reducing complications and hospital length of stay compared to open lobectomy.

THE RADIOLOGIST: ART CRITIC OR CONSULTANT IN PATIENT CARE?

Dr. Erika Mann 11:20–11:50

PRESENTATION SUMMARY: All too often practice assessments are based on volume, throughput and revenues, with no metrics other than occasional patient satisfaction surveys to assess the "softer" side of medicine. The culture of radiology in many practices marginalizes the patient. A paradigm shift is gaining traction in making sure that along the way we refocus on the patient as our priority, even in the somewhat invisible specialties such as radiology. We can foster an environment of patient-centred care in many ways, and at many intervals along the patient's radiology experience. These opportunities arise by educating and counselling referring clinicians about the right test to answer the question, booking and registration, patient information of the exam and expectations and synthesis of results with discussions—not only the mandated critical results documentation. As physicians, we are part of the care pathway and we should take time to put the 'care' back in health care by identifying value to the stakeholders and making sure that we strive to deliver that value in our practices.

LEARNING OBJECTIVES: At the end of this presentation, participants will be able to:

1. Define value as it pertains to a radiology practice.
2. Assess a radiology practice model with respect to fostering patient-centred care and value.
3. Explore tactics for improved communication as a key role in delivering value in radiology practice.

TRANSFORMING LUNG CANCER REFERRALS: ENSURING A VALUE-ADDED SERVICE

Dr. Carole Dennie 11:50–12:20

PRESENTATION SUMMARY: Improving access to timely cancer diagnosis requires more than just increasing the volume of patients processed through the system. This lecture describes a systems approach to the redesign of care in a way that enabled timely access of patients suspected of lung cancer to a centralized specialty service and the valued role that radiologists played.

Although siloed performance-improvement initiatives had been undertaken, these did not take into account the cumulative wait and multiple care hand-offs that were occurring throughout the patient's journey. Diagnostic service delivery was optimized by engaging all stakeholders, including radiologists, and with patient participation. The lung cancer diagnostic process was transformed to optimize a single regional intake point and timely multidisciplinary review to standardized diagnostic care pathways for specific subset disease pathologies. Part of this redesign included a daily joint review of imaging by a thoracic radiologist and surgeon followed by standardized orders sets co-developed by the team. This was followed by a single "navigation day" providing access to multiple essential procedures as well as education and support in a single visit as part of the continuum of care. Standardized triage pathways were defined for referral to treatment providers, and access to consults and treatment was improved. The improvements resulted in a significant increase—more than 48%—in patients receiving a timely diagnosis and a reduction in the duration of the patient journey from referral to treatment, now sustained for over two years.

LEARNING OBJECTIVES: At the end of this presentation, participants will be able to:

1. List the steps taken to streamline the intake and diagnostic work-up of patients presenting with possible lung cancer (CanMEDS: Leader and Health Advocate).
2. Describe the critical role the radiologist plays in the multidisciplinary approach to the patient with possible lung cancer (CanMEDS: Leader, Collaborator, and Health Advocate).
3. Enumerate the ongoing efforts radiologists can make to provide more value to the care of lung cancer patients (CanMEDS: Leader, Collaborator, and Health Advocate).

THE CHALLENGES AND OPPORTUNITIES IN UNDERGRADUATE MEDICAL EDUCATION

10:50–12:20
Salle de bal est
Moderator: Dr. David Barnes

These four presentations will be followed by a 10-minute interactive question period.

COLLABORATING WITH ANATOMISTS: THE FUTURE OF PRE-CLINICAL RADIOLOGY

Dr. Bruce Forster 10:50–11:10

PRESENTATION SUMMARY: Radiologists have a broad understanding of clinical anatomy, which makes them uniquely suited to teach pre-clinical anatomy to medical students. This session reviews the benefits of having a radiologist participate in pre-clinical teaching, and some easy practical ideas for getting involved. Novel teaching methods will be introduced.

LEARNING OBJECTIVES: At the end of this presentation, participants will be able to:

1. Review the importance of having radiology be a visible specialty in the pre-clinical curriculum.
2. Describe practical ways in which radiologists can get involved with pre-clinical anatomy teaching.
3. Explore the benefits of curricular innovations.

ULTRASOUND IN UNDERGRADUATE MEDICAL EDUCATION: A TALE OF TWO PROGRAMS

Dr. Heather Curtis and Dr. Petter Tonseth 11:10–11:30

PRESENTATION SUMMARY: This presentation is intended for any radiologist working in a setting affiliated with an undergraduate medical program who has an interest in how ultrasound is being incorporated and used in undergraduate teaching.

We will discuss the development of an ultrasound curriculum for undergraduate medical learners through a comparison of the process undertaken at both Dalhousie University and the University of British Columbia with a focus on rationale and pertinent 'pearls' that can be applied in any setting.

We will provide an account of current experience as well as our vision for the future with a focus on the role of the radiologist in undergraduate education specifically related to ultrasound.

LEARNING OBJECTIVES: At the end of this presentation, participants will be able to:

1. Discuss the reasoning behind the development of an undergraduate ultrasound curriculum for medical students and why it is important to be involved.
2. Compare and contrast the challenges of initiating such a program using the University of British Columbia and Dalhousie University experiences as examples.
3. Outline key components for successful development and initiation of an ultrasound curriculum at the undergraduate level.

RADIOLOGY ELECTIVES: STRATEGIES TO IMPROVE THE STUDENT EXPERIENCE

Dr. Ning Su 11:30–11:50

PRESENTATION SUMMARY: Undergraduate elective in radiology is a unique experience every medical student interested in radiology must undergo. Compared to electives in other clinical disciplines, an undergraduate radiology elective is commonly structured as a clinical observership, during which time the student sits with one faculty member or resident over a period of time, as they work through the day. In a discipline about which many medical students have little or no prior knowledge, listening to dictation in radiology jargon can be frustrating. At the same time, teaching medical students while working through a busy list can be just as challenging for any practicing radiologist or resident.

Speaking from personal experience, the radiology electives experienced as a medical student and as a resident will be shared, followed by suggestions and strategies to enhance the undergraduate elective experiences, not only for future medical students but also for faculty members and fellow residents.

LEARNING OBJECTIVES: At the end of this presentation, participants will be able to:

1. Recognize the limitations of current observership-based undergraduate radiology elective.
2. Describe strategies to enhance radiology elective experiences.
3. Evaluate and determine if these can be implemented to daily practices to enhance student learning while minimizing work interruption.

NATIONAL RADIOLOGY CURRICULUM FOR UNDERGRADUATE MEDICINE

Dr. Elsie Nguyen 11:50–12:10

PRESENTATION SUMMARY: This presentation will describe the background need for a national curriculum and how this curriculum must be practical and achievable for most Canadian medical schools. The presentation will briefly compare our national curriculum with other suggested curricula available online. The steps taken to achieve this national curriculum will be described as well as future goals to achieve national acceptance and adoption of this curriculum.

LEARNING OBJECTIVES: At the end of this presentation, participants will be able to:

1. Describe the rationale for a national medical imaging curriculum.
2. List the steps that were taken to write the national medical imaging curriculum.
3. Outline what still needs to be done to achieve national acceptance of the national curriculum.

RADIOLOGY CARE: A VALUE-DRIVEN APPROACH (GU/GI)

13:30–15:00
Salle de bal ouest
Moderator: Dr. Iain Kirkpatrick

BOTTOMS UP! PITFALLS AND PEARLS IN RECTAL MRI: WHAT THE RADIOLOGIST NEEDS TO KNOW IN 2017

Dr. Zahra Kassam 13:30–14:00

PRESENTATION SUMMARY: Over the last five to ten years, MRI has become an essential tool in the management of patients with rectal carcinoma.

When performed with optimal technique, rectal MRI has high accuracy in diagnosis and staging of rectal carcinoma. Although knowledge of the imaging staging criteria is essential, the radiologist must also be aware of the information that surgical and medical colleagues require to make appropriate treatment decisions.

This presentation will review the following using illustrative cases: Optimal MRI technique for primary staging of rectal cancer; Pitfalls and pearls in primary staging; Primer on surgical approaches and interventions; Navigating the Rectal Cancer tumour board.

LEARNING OBJECTIVES: At the end of this presentation, participants will be able to:

1. Describe and implement optimized MRI technique and sequences when evaluating patients with rectal cancer.
2. Report rectal cancer MRI using established reporting standards (synoptic report).
3. Identify and describe the key imaging features surgeons and oncologists want to know, and integrate them into radiology reports.
4. Recognize the impact of MRI staging on patient management and outcome.
5. Approach rectal cancer cases from an interdisciplinary perspective.
6. Troubleshoot challenging cases using pitfalls and pearls.
7. (CanMEDS: Medical Expert and Scholar).

PI-RADS V2: WHAT YOU NEED TO KNOW

Dr. Iain Kirkpatrick 14:00–14:30

PRESENTATION SUMMARY: Despite a long history, prostate MRI has struggled for widespread adoption amongst radiologists and urologists outside of large academic institutions. The release of PI-RADS V2 in 2015 is arguably the single greatest step so far in driving the adoption of prostate MRI, as it brings an intuitive standardized reporting system and localization methodology that facilitates communication between radiologists and clinicians, and adds considerable value to our reports.

This presentation will outline the major features of the PI-RADS V2 reporting standard. Time will be spent discussing protocol optimization to meet the current standard-of-care, with particular attention to diffusion-weighted imaging technique. If you are new to prostate MRI, have tried it in the past and came away disillusioned, or are considering starting up a program, this presentation is for you.

LEARNING OBJECTIVES: At the end of this presentation, participants will be able to:

1. Describe the benefits of adopting the PI-RADS V2 standardized reporting system for prostate MRI, particularly for clinicians.
2. Identify the technical requirements for standard-of-care prostate MRI under PI-RADS V2 guidelines.
3. Outline the basic components of the PI-RADS V2 reporting system.

LIVER IMAGING REPORTING AND DATA SYSTEM (LI-RADS): WHAT YOU NEED TO KNOW

Dr. Chris Lindquist 14:30–15:00

PRESENTATION SUMMARY: The liver imaging reporting and data system was developed in an attempt to standardize the reporting of liver imaging for hepatocellular carcinoma using both CT and MRI, particularly in cirrhotic patients. This scale attempts to assign categories from LI-RADS 1 to LI-RADS 5, reflecting an increased probability of hepatocellular carcinoma. The technical requirements of CT and MRI protocols necessary to apply this reporting system will be summarized. This presentation will review the different LI-RADS categories and the features that will assist the radiologist in assigning a LI RADS category to liver CT and MRI cases. The terminology utilized for this system will be described in detail. This presentation will also review the ancillary features and tie-breaking rules described by LI RADS that assist in applying a category to indeterminate cases. Finally, management recommendations for each LI-RADS category will be summarized.

LEARNING OBJECTIVES: At the end of this presentation, participants will be able to:

1. Describe the LI-RADS reporting system.
2. Identify imaging features which are important in assigning LI-RADS categories.
3. Apply the LI-RADS lexicon and criteria to clinical cases.

AFTERNOON TRACKS — FRIDAY, APRIL 21, 2017

CAR RADIOLOGISTS-IN-TRAINING CONTEST

13:30–15:00 / 15:30–17:00
Salon Jarry & Joyce, Level A
Moderator: Dr. Gilles Bouchard
Judges: Dr. Marco Essig, Dr. Faisal Khosa, Dr. Mark Levental

The following abstracts will be presented orally. Refer to the Abstracts section on page 86 for the full abstracts.

Les abrégés suivants seront présentés oralement. Veuillez consulter la section des résumés d'expositions à la page 86 pour en faire la lecture complète.

Each presentation will be 8 minutes, followed by a 2-minute interactive question period.

13:30 – RT001
Vacuum-Assisted Complete Excision of Solid Intraductal/Intracystic Masses and Complex Cysts: Is Follow-up Necessary? – *Vanessa Quinn-Laurin*

13:40 – RT002
Intestinal Pneumatosis : Worrisome Clinical and CT Sign
– *Christophe Cloutier Lambert*

13:50 – RT003
Leadership in Healthcare: A Bibliometric Analysis of 100 Publications
– *Timothy L. Miao*

14:00 – RT004
Imaging Workup for Pulmonary Embolus: Can We Avoid Exposing Patients to Radiation by Using Magnetic Resonance Angiography as an Alternative Imaging Modality? – *Kevin Toporowicz*

14:10 – RT005
The Relevance of Abdominal Radiographs in the Evaluation of Children with Coin Ingestion – *Naoya Shatani*

14:20 – RT006
Reducing Wait-Time for Lung Cancer Diagnosis and Treatment: Impact of a Multidisciplinary, Centralized Referral Program – *Jessica L. Common*

14:30 – RT007
Reporting of Imaging Diagnostic Accuracy Studies: Adherence to STARD 2015
– *Patrick J. Hong*

15:30 – RT008
Over-interpretation of Research Findings: Evidence of 'Spin' in Systematic Reviews of Diagnostic Accuracy Studies – *Trevor A. McGrath*

15:40 – RT009
Utilizing Pre-procedural CT Scans to Identify Patients at Risk for Suboptimal External Ventricular Drain Placement with the Freehand Insertion Technique
– *Mitchell P. Wilson*

15:50 – RT010
Automating Medical Imaging Protocol Selection: A Feasibility Study of Machine Learning in Quality and Safety – *Andrew D. Brown*

16:00 – RT013
Imaging of Non-Lesional Epilepsy Using Hybrid PET/MRI: Comparison of MR Attenuation Correction (MRAC) and CT Attenuation Correction (CTAC)
– *Benjamin Y. Kwan*

16:10 – RT014
Determining the Necessity of Oral Contrast for Abdominal/Pelvic Computed Tomography Scans: An Approach Using Bioelectric Impedance Analysis and Body-Mass Index – *Yuhao Wu*

16:20 – RT015
A Needs Assessment of Senior Medical Student Radiology Electives: Where Are the Gaps and What Can We Improve? – *Natasha Larocque*

16:30 – RT016
Route-to-Diagnosis of Lung Cancer in Nova Scotia – *Aamir Suhail*

MSK: SPORTS INJURIES

13:30–15:00
Salle de bal est
Moderator: Dr. Robert Bleakney

SPORTS MRI OF THE HIP AND GROIN

Dr. Robert Bleakney 13:30–14:00

PRESENTATION SUMMARY: This presentation will discuss the various MRI protocols used in imaging of an athlete with hip/groin pain. In particular, typical protocols for non-specific hip pain, athletic pubalgia and labral tears will be explained. The aetiology and MR imaging appearances of femoro-acetabular impingement and athletic pubalgia will be clarified.

LEARNING OBJECTIVES: At the end of this presentation, participants will be able to:

1. Select appropriate protocols for imaging of the pelvis, hips and groin in an athlete.
2. Recognize the aetiology of athletic pubalgia and femoro-acetabular impingement.
3. Identify and discuss important MR imaging features of femoro-acetabular impingement and athletic pubalgia.

CURRENT CONCEPTS: IMAGING THE SHOULDER AND ELBOW IN ATHLETES

Dr. Tom Powell 14:00–14:30

PRESENTATION SUMMARY: Current concepts related to causes of impingement and of instability, causing impairment of function, in the shoulder and elbow in athletes will be discussed. Associated anatomy and biomechanics of injuries will be reviewed. The appropriateness and value of use of different imaging modalities in the assessment of the shoulder and elbow in the athlete will be discussed. What the referring clinician needs from the radiology report will be emphasized.

LEARNING OBJECTIVES: At the end of this presentation, participants will be able to:

1. Integrate current concepts in anatomy and biomechanics related to injury of the shoulder and elbow in athletes into their imaging practice.
2. Differentiate between various causes of impingement in the shoulder and elbow causing impairment of function in the athlete.
3. Differentiate between various causes of instability in the shoulder and elbow causing impairment of function in the athlete.

NOT UNCOMMON FOOT AND ANKLE DIAGNOSES FOR THE GENERAL RADIOLOGIST

Dr. Thomas Mammen 14:30–15:00

PRESENTATION SUMMARY: A short period will be spent on reviewing foot and ankle anatomy. The remainder of the presentation will primarily focus on imaging findings of relatively common foot and ankle pathologies. Specifically, the radiological appearances of extra-articular hindfoot impingement, Bassett's ligament and Mueller-Weiss syndrome will be addressed. A brief explanation on the utility of SPECT-CT imaging on foot/ankle diagnoses will also be discussed.

LEARNING OBJECTIVES: At the end of this presentation, participants will be able to:

1. Review foot and ankle anatomy.
2. Explain the pathophysiology and imaging of extra-articular hindfoot impingement.
3. Illustrate the utility of SPECT-CT imaging in foot/ankle diagnoses.
4. Report the diagnosis of Bassett's ligament.

RADIOLOGY CARE: A VALUE-DRIVEN APPROACH (EMERGENCY RADIOLOGY)

15:30–17:00
Salle de bal ouest
Moderator: Dr. Adnan Sheikh

ROLE OF THE ER SECTION IN A RADIOLOGY DEPARTMENT

Dr. Savvas Nicolaou 15:30–16:00

PRESENTATION SUMMARY: Emergency radiology is a rapidly growing subspecialty field with increasing demand for acute care imaging. Numerous fellowships, societies, and resources are available within the field, and are substantially growing with great innovations occurring. Although challenges such as outsourcing, radiation dose concerns, and decreased financial support have arisen, radiologists have the potential to address these obstacles and should address them now.

LEARNING OBJECTIVES: At the end of this presentation, participants will be able to:

1. Appraise the history of emergency radiology.
2. Discuss the current presence of ED radiology and its impact on patient care, and role in polytrauma imaging.
3. Describe the potential future opportunities, innovations, and challenges involved in emergency radiology.

POLYTRAUMA: IS IT ALWAYS WHOLE-BODY CT?

Dr. Ferco H. Berger 16:00–16:30

PRESENTATION SUMMARY: In the Western world, polytrauma is the major cause of mortality in people under 45 years of age. Furthermore, it is a major contributor to loss of quality of life and ability to work. To decrease morbidity and mortality, time is everything. To reach the best treatment strategy for the patient as quickly, as accurately and as safely possible is the goal.

In this update on imaging of polytrauma patients, the focus will be on the role of CT to achieve this goal. With the progress in CT scanner development, different protocol options arise: Which CT protocols are being used and which factors do they depend upon? In addition, there is a widespread increase in use of whole-body CT internationally; is this a good thing or should we be more selective? What is the current evidence to select patients for targeted CT examinations in polytrauma? Many of these questions have not been definitively resolved. This presentation aims to provide an update of the current insights into the use of CT for trauma care, with the goal of choosing wisely how to investigate the polytrauma patient in a timely and meaningful fashion.

LEARNING OBJECTIVES: At the end of this presentation, participants will be able to:

1. Recognize current world-wide accepted protocols in polytrauma CT imaging.
2. Identify clinical conditions requiring whole-body CT.
3. List the selection of trauma patients for targeted CT examinations.

DIFFERENTIATION OF BOWEL ISCHEMIA

Dr. Timothy O'Connell 16:30–17:00

PRESENTATION SUMMARY: This presentation will review the published literature on the use of evaluating bowel ischemia with dual-energy CT, and will review experiences with this new technique over the past few years at Vancouver General Hospital, specifically discussing the benefits and limitations of DECT and how it fits into workflow.

LEARNING OBJECTIVES: At the end of this presentation, participants will be able to:

1. Appraise the current literature on DECT for bowel ischemia.
2. Analyze the experience of a centre with real-world multi-year experience with this new technique.
3. Extrapolate how this can fit into a centre's workflow and how it can be used to benefit patients and clinical teams.

AFTERNOON TRACKS — FRIDAY, APRIL 21, 2017

DEVELOPMENT OF ACADEMIC LIFE

15:30–17:00
Salle de bal est
Moderator: Dr. An Tang

A PRIMER ON EFFECTIVE ABSTRACT WRITING

Dr. Peter L. Munk 15:30–16:00

PRESENTATION SUMMARY: The abstract is the most read portion of a paper apart from the title, and may be the only section read by the reader. Abstracts submitted for selection in meeting presentations are the only thing seen by reviewers. To better understand how to write high impact abstracts, this lecture will review the structure of the abstract and how to most effectively write it so that the message is clearly conveyed and the attention of the reader is engaged.

LEARNING OBJECTIVES: At the end of this presentation, participants will be able to:

1. Discuss the importance of effectively-written abstracts.
2. Describe the structure of an abstract.
3. Develop strategies for writing useful and noteworthy abstracts. (CanMEDS: Communicator)

HOW TO OPTIMIZE RESEARCH PUBLICATION PROBABILITY!

Dr. Matthew D. McInnes 16:00–16:30

PRESENTATION SUMMARY: This session will outline multiple strategies to increase probability of publication of imaging research. These include identifying optimal journals for submission, using reporting checklists to improve completeness of reporting and implementing best-practices during the study-design phase to increase the "impact" of research.

LEARNING OBJECTIVES: At the end of this presentation, participants will be able to:

1. Identify the most relevant journals to which they should submit their work.
2. Optimize their manuscript prior to submission by using reporting guidelines.
3. Implement strategies to increase the "impact" of their research.

TIPS TO OBTAIN A FIRST PEER-REVIEW RESEARCH GRANT

Dr. An Tang 16:30–17:00

PRESENTATION SUMMARY: This presentation will discuss the difference between operating grants, infrastructure grants and research awards. The focus will be on operating grants, which provide funding for the execution of research awards. We will discuss eligible expenses such as salaries, stipends, data post-processing, statistical analyses and travel expenses. We will highlight the importance of developing a funding track record and explain why residents and junior faculty who intend to pursue a research track should consider applying for operating grants early in their career.

We will discuss sources of funding, including internal sources within radiology departments or universities, and extra-mural sources such as foundations and public funding agencies. We will list some provincial, national and international sources of funding. We will discuss the calendar of operating grant competitions and key features of successful grant applications.

LEARNING OBJECTIVES: At the end of this presentation, participants will be able to:

1. Differentiate between operating grants, infrastructure grants and research awards.
2. Identify grant competitions appropriate for their level.
3. Plan a strategy for a first grant application.
4. Recognize some key features of a successful grant application.

80th ANNIVERSARY CELEBRATION COCKTAIL

Come join the celebration as the CAR marks its 80th anniversary!
From its humble beginnings in 1937 as a grassroot gathering of Canadian radiologists, to its current pan-Canadian role as the voice of radiologists; come walk through our retrospective of the history of medical imaging in Canada and the CAR itself, and test your knowledge of our Association's past.

Note: due to a conflicting engagement with the Awards Ceremony on Saturday, the CAR will be presenting Dr. Karel ter Brugge with his CAR Distinguished Career Achievement Award during this event.

Friday, April 21
5:00 p.m. – 6:00 p.m.
Salle de bal est, Level 4

SOIRÉE COCKTAIL DU 80e ANNIVERSAIRE

Joignez-vous aux célébrations marquant le 80e anniversaire de la CAR!
Depuis ses modestes débuts en 1937 en tant que simple regroupement de radiologistes canadiens, la CAR est devenue une association pancanadienne agissant comme porte-parole des radiologistes. Venez explorer une rétrospective de l'imagerie médicale au Canada et de la CAR, en plus de mettre à l'épreuve vos connaissances sur l'histoire de l'association.

Remarque : En raison d'un conflit d'horaire avec la cérémonie de remise de prix du samedi, la CAR présentera le Prix d'excellence de la CAR pour une éminente carrière au Dr Karel ter Brugge au cours de cette soirée.

Vendredi 21 avril
De 17 h à 18 h
Salle de bal est, niveau 4

NEW TIME 07:00– 08:00
SALON DRUMMOND, LEVEL 3

CAR AND CRF ANNUAL GENERAL MEETINGS BREAKFAST

PLENARY SESSION: RADIOLOGIC-PATHOLOGIC CORRELATION OF POLYCYSTIC KIDNEY DISEASE AND OTHER CILIOPATHIES

Dr. Ellen M. Chung
08:00–08:40
Salle de bal ouest

This presentation will be 30 minutes, followed by a 10-minute interactive question period.

PRESENTATION SUMMARY: Genetic defects in primary or sensory cilia result in a wide range of phenotypes affecting a variety of organs, including the kidneys, liver, central nervous system, retina, and skeleton. Renal involvement is the most common manifestation including abnormal renal tubular development in autosomal recessive polycystic kidney disease (ARPKD) and abnormal tubular maintenance in autosomal dominant polycystic kidney disease (ADPKD). In both ARPKD and ADPKD, the liver is also involved. Other ciliopathies include medullary cystic disease and nephronophthisis, Joubert syndrome, Meckel–Gruber syndrome, and a number of skeletal dysplasias. The recently recognized unifying molecular basis of this group of disorders explains the overlap of abnormalities affecting a variety of organ systems. It is important for radiologists to recognize the multisystem manifestations of these conditions, as imaging plays an important role in surveillance, diagnosis, and follow-up.

LEARNING OBJECTIVES: At the end of this presentation, participants will be able to:

1. Define the term “ciliopathy” and explain how inherited cystic renal diseases are related in the role of the medical expert.
2. Distinguish between different types of cystic renal diseases on imaging.
3. Apply these principles and features to properly diagnose cases of renal ciliopathies and mimics.

ADVANCED TECHNOLOGIES: CT

08:45–10:15
Salle de bal ouest
Moderator: Dr. Khashayar Rafatzand

RECENT ADVANCEMENT IN CARDIAC CT

Dr. Karl Sayegh 08:45–09:15

PRESENTATION SUMMARY: The presentation will discuss the advancements introduced to cardiac CT that have enabled improved image quality, diagnostic accuracy, and lower radiation exposure. New post-processing algorithms allowing both plaque segmentation and adjudication of lesion-specific ischemia will also be discussed.

LEARNING OBJECTIVES: At the end of this presentation, participants will be able to:

1. Review the current data for the role of cardiac CT in stable angina.
2. Highlight the recent advancements in cardiac CT that have enabled dose reduction, improved accuracy, and ischemia delineation.
3. Discuss what the future may hold for cardiac CT in the coming years.

DUAL ENERGY CT: PRINCIPLES, TECHNOLOGY, AND CLINICAL APPLICATIONS

Dr. Rajiv Gupta 09:15–09:45

PRESENTATION SUMMARY: This presentation will review the physical principles of dual-energy material decomposition and its current implementation. Clinical applications of dual-energy material decomposition, including differentiation of calcification from hemorrhage and iodinated contrast from hemorrhage, will be described and illustrated with examples.

LEARNING OBJECTIVES: At the end of this presentation, participants will be able to:

1. Describe the physics behind the dual-energy CT.
2. Describe the various technological implementations of this imaging modality.
3. Discuss the main pros and cons of different DECT implementations.
4. Illustrate key clinical applications of DECT.

LATEST ADVANCEMENTS IN CT SCAN TECHNOLOGY

Dr. Khashayar Rafatzand 09:45–10:15

PRESENTATION SUMMARY: This lecture will present advances in multi-detector, cone beam and dual-energy CT (MDCT, CBCT, DECT), new CT detectors (dual-layer, photon-counting) and iterative reconstruction algorithms leading to improvements in spatial, temporal and contrast resolution as well as decreased radiation exposure. Clinical applications in peripheral and cerebral vascular disease, pediatric abdominal CT and breast CT will be discussed.

LEARNING OBJECTIVES: At the end of this presentation, participants will be able to:

1. Describe the new trends in CT scan technology.
2. Discuss the most common clinical applications of CT scanners.
3. Determine whether the practice/institution would benefit from the acquisition of state-of-the-art CT clinical and research scanners.

HRCT OF THE CHEST: A HANDS-ON PRACTICAL WORKSHOP OF DIFFUSE LUNG DISEASE

08:45–12:15
Simulation Workshop Leaders: Dr. Daria Manos and Dr. Carolina Souza
Moderators: Dr. Ana-Maria Bilawich, Dr. Joy Borgaonkar, Dr. Ashish Gupta, Dr. João Inácio, Dr. Daria Manos, Dr. Anastasia Oikonomou, Dr. Carolina Souza, Dr. Marie-Michèle Thériault

PRESENTATION SUMMARY: This half-day hands-on CT workshop dedicated to diffuse and interstitial lung disease will provide practical problem-solving tools for the general radiologist. Designed for practicing radiologists, the workshop is structured to simulate real-case reporting. Short high-impact didactic reviews will be followed by multiple interpretation sessions where participants can review complete image files under the supervision of expert faculty.

With a faculty-to-participant ratio of five participants to one faculty and plenty of image workstations, participants will benefit from individualized instructor feedback. Instructors will share strategies for the interpretation of difficult imaging patterns, provide tools for navigating the hinterland between normal and abnormal, summarize recent updates in interstitial lung disease and review new recommendations. Instructors are all fellowship-trained thoracic radiologists at academic centres.

LEARNING OBJECTIVES: At the end of the workshop, participants will be able to:

1. Explain high-resolution CT technique and protocols available for imaging of diffuse lung diseases.
2. Apply pattern recognition and distribution of findings in the HRCT diagnosis of diffuse lung diseases.
3. Diagnose the most common cystic, nodular and fibrotic interstitial lung diseases.

WORKSHOP ROOM 1

CYSTIC LUNG DISEASES AND EMPHYSEMA

Moderators: Dr. Ana-Maria Bilawich and Dr. João Inácio

WORKSHOP ROOM 2

DISEASES WITH NODULAR PATTERN

Moderators: Dr. Anastasia Oikonomou and Dr. Marie-Michèle Thériault

WORKSHOP ROOM 3

FIBROTIC INTERSTITIAL LUNG DISEASES

Moderators: Dr. Ashish Gupta and Dr. Carolina Souza

WORKSHOP ROOM 4

DIFFUSE ABNORMALITIES OF LUNG DENSITY

Moderators: Dr. Joy Borgaonkar and Dr. Daria Manos

Pre-registration is required.

POST-RESIDENCY PANEL

08:45–10:15
Salle de bal est
Moderator: Dr. Cameron Hague

Each presentation will be 10 minutes, followed by a 45-minute interactive question period.

PREPARING FOR YOUR FIRST YEAR OUT OF RESIDENCY: TIPS AND TRICKS

Panelists: Dr. Jason Clement, Dr. Mario Kontolemos, Dr. Jonathan Scheske, Dr. Lisa Smyth

PRESENTATION SUMMARY: This panel discussion will provide participants with an overview of the challenges a radiologist faces transitioning from residency/fellowship training into the first years of practice. Insights, tips and tricks will be provided by the panelists in the form of both a brief summary of their own personal experiences and by answering questions from the audience in this interactive session.

LEARNING OBJECTIVES: At the end of this presentation, participants will be able to:

1. Identify the pitfalls, challenges and difficulties faced as a first-year radiology staff member.
2. Identify strategies that a radiology resident can employ during training to ensure residency helps address some of these challenges.
3. Apply knowledge gained in this session to aid in making the transition from radiology trainee to staff member a smoother one.

IMAGING COMPLICATIONS OF ONCOLOGICAL THERAPY AND MR ELASTOGRAPHY

10:45–12:15
Salle de bal ouest
Moderator: Dr. Tanya Chawla

LIVER MAGNETIC RESONANCE ELASTOGRAPHY: CONCEPTS AND APPLICATIONS

Dr. An Tang 10:45–11:15

PRESENTATION SUMMARY: Magnetic resonance elastography (MRE) is an emerging technique for measuring tissue stiffness. This presentation will illustrate the basic physics principles of MRE. This technique works on clinical MR systems and requires hardware to generate mechanical waves, phase-contrast sequences to encode motion, and post-processing software to generate wave images and stiffness maps, also known as elastograms. We will describe how to perform and interpret liver MRE studies. We will discuss current or emerging indications to perform liver MRE and examine their relevance in oncologic imaging: 1) staging of liver fibrosis for identification of patients at risk for hepatocellular carcinoma (HCC), 2) stratification of risk of developing HCC among cirrhotic patients, and 3) characterization of focal liver masses. This lecture will include a selection of teaching cases to highlight the clinical indications of liver MRE. We will summarize the diagnostic performance of this imaging technique, the pitfalls, and briefly discuss future directions.

LEARNING OBJECTIVES: At the end of this presentation, participants will be able to:

1. Describe the basic principles of magnetic resonance elastography (MRE).
2. Illustrate how to perform and interpret a liver MRE examination.
3. Identify relevant indications of liver MRE for oncologic imaging.

ONCOLOGY COMPLICATIONS IN NEURORADIOLOGY

Dr. Jeremy Rempel 11:15–11:45

PRESENTATION SUMMARY: Primary and secondary malignancies of the head, neck and spine are common findings in an active radiology practice. They often present with acute direct complications, such as spinal cord compression from a pathological compression fracture or increased intracranial pressure from a brain neoplasm or associated edema. Indirect complications can also occur with a cancer-induced hypercoagulable state resulting in an ischemic stroke, or the toxic effects of radiation or chemotherapy on the brain and spinal cord. Ultimately, appropriate management is critical whether by a neurosurgeon, a neurologist, a neuro-oncologist or an interventional neuroradiologist.

LEARNING OBJECTIVES: At the end of this presentation, participants will be able to:

1. Identify direct oncological complications involving the spine, head and neck.
2. Identify indirect oncological complications involving the spine, head and neck, such as ischemic stroke, radiation and chemotherapy toxicity, as well as infection.
3. Facilitate appropriate referral for the management of oncologic complications of the spine, head and neck.

IMAGING THE COMPLICATIONS OF ONCOLOGICAL THERAPY IN THE ABDOMEN

Dr. Tanya P. Chawla 11:45–12:15

PRESENTATION SUMMARY: Oncologic patients undergo imaging as part of initial diagnosis, while being assessed for treatment response and for ongoing surveillance of recurrence. There have been considerable advances in non-surgical treatment options including chemotherapeutic regimens and radiation therapy. A spectrum of the most common complications will be discussed, in particular dealing with conventional agents and targeted newer therapies. There can be overlap between disease-related complications and iatrogenic sequelae of such agents. The practicing radiologist needs to be aware of these potential pitfalls and have strategies for discrimination. Comparably, methods and delivery options for radiation to intra-abdominal tumours have also evolved. Both the early and late findings of radiation therapy will be described.

LEARNING OBJECTIVES: At the end of this presentation, participants will be able to:

1. Review a spectrum of complications related to chemotherapy within the abdomen.
2. Discuss tips and pitfalls when discriminating such complications from disease recurrence.
3. Analyze the late and early impact of radiation-related findings in the abdomen.

RESIDENT REVIEW: THORACIC IMAGING, PART 1

10:45–12:15
Salle de bal est
Moderator: Dr. Cameron Hague

The CAR is proud to present the annual case-based resident review session, part 1. This radiology overview is targeted to residents, clinical fellows, as well as practicing radiologists interested in updating their working knowledge of cardiothoracic imaging.

Following these sessions, attendees will be able to appreciate the utility of various imaging modalities used to image the heart and lungs (namely x-ray, CT and MR), accurately describe and provide differential diagnoses for common cardiac and thoracic pathologies, and understand the role the radiologist plays in caring for patients with cardiothoracic disease.

These sessions are planned to be practical, with emphasis placed on what the graduating resident needs to know.

HOW DO I APPROACH CARDIAC MR?

Dr. Elena Peña 10:45–11:15

PRESENTATION SUMMARY: We will demonstrate a stepwise approach to examining the heart on cardiac MR examination. We will review the relevant information that can be extracted from each cardiac MR sequence. We will learn the meaning of myocardial late gadolinium enhancement. Finally, we will introduce a differential diagnosis based on the pattern of gadolinium enhancement through cases.

LEARNING OBJECTIVES: At the end of this presentation, participants will be able to:

1. List the different components of a cardiac MR examination.
2. Describe the meaning of myocardial late gadolinium enhancement.
3. Identify the correct differential diagnosis based on the pattern of myocardial enhancement.

THE CHEST X-RAY: WHAT YOU NEED TO KNOW

Dr. Lisa Smyth 11:15–11:45

PRESENTATION SUMMARY: The purpose of this presentation is to aid in the interpretation of the most common radiograph – the chest x-ray. We will go through basic anatomy, common pathologies and differential diagnoses, as well as normal variants easily identified on a chest x-ray.

LEARNING OBJECTIVES: At the end of this presentation, participants will be able to:

1. Identify normal anatomy on a chest x-ray.
2. Discuss common pathology and differential diagnosis from a chest x-ray.
3. Identify normal variants.

GAME-CHANGING CARDIAC CASES

Dr. Johnathan Scheske 11:45–12:15

PRESENTATION SUMMARY: Following a basic overview for evaluating the heart on cross-sectional imaging, several cases will be presented, each highlighting specific cardiovascular pathology that can be diagnosed by the radiologist and impact clinical management.

LEARNING OBJECTIVES: At the end of this presentation, participants will be able to:

1. Demonstrate the pivotal role of radiology in directing management using specific case examples.
2. Apply cardiovascular-specific knowledge to clinical cases from general practice.
3. Highlight specific cardiovascular pathology that may commonly go unrecognized.

For the afternoon portion of the *Resident Review: Thoracic Imaging, Part 2*, refer to page 56.

ADVANCED TECHNOLOGIES: NOVEL TECHNOLOGIES

13:30–15:00
Salle de bal ouest
Moderator: Dr. Frank Rybicki

DETERMINING RISK OF MYOCARDIAL INFARCTION FROM CARDIAC CT: UNLOCKING THE POWER OF ARTIFICIAL INTELLIGENCE

Dr. William Guest 13:30–14:00

PRESENTATION SUMMARY: This presentation will introduce and broadly discuss the evolving role of artificial intelligence (AI) in diagnostic imaging and medicine. The opportunities and challenges brought to our sector will be highlighted. A number of clinical examples where AI and deep learning have already been integrated into clinical medicine will be examined.

LEARNING OBJECTIVES: At the end of this presentation, participants will be able to:

1. Define current CT-based risk models for myocardial infarction prediction.
2. Describe how deep learning may play a role in medicine.
3. Discuss recent publications exploring big data analytics for risk prediction.

THE ROLE OF THE RADIOLOGIST IN 3D PRINTING

Dr. Frank Rybicki 14:00–14:30

PRESENTATION SUMMARY: "3D printing" refers to the fabrication of a tangible object from a digital file by a 3D printer. Materials are either deposited from a nozzle fusing to form a final object or an energy source is directed at a polymer, metal or plastic to form a solid object in a layered fashion. Additive manufacturing, rapid prototyping, and additive fabrication are all considered synonyms for 3D printing.

While Digital Imaging and Communications in Medicine (DICOM) image files cannot be used directly for 3D printing, there are defined steps to convert CT and MRI DICOM images into models. These include steps familiar to radiologists, such as segmentation and other methods of image post-processing collectively termed "3D visualization". However, 3D printing requires a separate set of steps in computer-aided design (CAD), during which one or more segmented objects are manipulated in the Standard Tessellation Language (STL) format. STL files are the dominant file format recognized by a 3D printer; however, many others, such as VRML (Virtual Reality Modeling Language), are being used and newer formats are being developed. Radiologists and other medical providers will need to learn and master a new set of tools for the conversion of DICOM data sets into 3D printing of DICOM data sets. 3D printing for patient care will cross all subspecialties of surgery and medicine, with radiology at the intersection. Radiologists need to be aware of this emerging technology as it is a direct extension of the images they create. As a leader in radiology education and research, the CAR is poised to embrace 3D printing and its role in the biomedical arena.

LEARNING OBJECTIVES: At the end of this presentation, participants will be able to:

1. Identify skills a radiologist will need to recognize 3D printing.
2. Describe the impact of medical modeling in the evolving biomedical landscape.
3. Recognize the RSNA Special Interest Group for 3D printing as a valuable resource in the field.
4. Recognize the medical and economic impact of 3D printing in Canadian and global health care.

SOFTWARE DEVELOPMENT, IMPLEMENTATION, AND OUTCOMES FOR MEASURING RADIOLOGIST PRODUCTIVITY IN A CANADIAN RADIOLOGY DEPARTMENT

Dr. Cynthia Walsh 14:30–15:00

PRESENTATION SUMMARY: Productivity is challenging to measure in an academic radiology department in which radiologists have a range of academic interests including clinical work, education, administration and research. This presentation will describe our Canadian experience in the development of a productivity measurement system designed to recognize both clinical and academic productivity, and to express that productivity with a simple metric termed the Ottawa Radiologist Activity Reporting (RADAR) score.

The Ottawa RADAR system is a new method to estimate radiologist productivity and can be applied to other radiology organizations or medical practices. RADAR is not based on any pre-existing RVU data. Credit for every procedure was locally vetted with respect to the expected time to complete the study, thus representing local efficiencies and cultures. Should others desire to adopt RADAR, procedure codes could be altered. This system can be easily modified to reflect different department values.

Data from RADAR can be easily analyzed. This can be useful for assessing individual radiologist productivity, how trainees affect productivity, and the efficiency of the department in general. We will also present some data regarding radiologist productivity following the implementation of RADAR.

LEARNING OBJECTIVES: At the end of this presentation, participants will be able to:

1. Assess the importance of recognizing both clinical and non-clinical work when evaluating radiologist productivity.
2. Review the basic parameters on which the Ottawa RADAR Score was based.
3. Appraise how a productivity-measuring system can affect radiologist productivity.

CONTROVERSIES IN RADIOLOGY

13:30–15:00
Salon Drummond, Level 3
Moderators: Dr. Mark Levental, Dr. Michael Patlas

IMAGING OF THE ACUTE ABDOMEN: ORAL CONTRAST A MUST

Dr. Michael Patlas 13:30–14:00

PRESENTATION SUMMARY: A review of the current/evolving imaging and related clinical literature shows that oral contrast elimination did not significantly affect the detection of acute abnormalities in the emergency setting. At the same time, the emerging/current evidence suggests that a no oral contrast APCT protocol leads to improved turnaround time for the final MDCT reports, and accelerates the disposition of ED patients..

LEARNING OBJECTIVES: At the end of this presentation, participants will be able to:

1. Describe current trends and controversies in oral contrast administration. (CanMEDS: Health Advocate)
2. Highlight factors affecting the selection of patients who would and would not benefit from the usage of oral contrast. (CanMEDS: Health Advocate)
3. Discuss the impact of the elimination of oral contrast on ED length of stay. (CanMEDS: Leader and Health Advocate)

CONTROVERSIES AND MYTHS IN BOWEL TRAUMA

Dr. Michael Patlas 14:00–14:30

PRESENTATION SUMMARY: Traumatic bowel injury is an uncommon life-threatening entity with suboptimal prospective detection. The presentation will focus on numerous controversies in imaging and management of patients with bowel injury including high rate of false-negative preoperative MDCTs; role of oral contrast; significance of free intraperitoneal fluid in male patients; proper technique for short-term CT follow up. Relevant surgical and imaging literature will be briefly discussed.

LEARNING OBJECTIVES: At the end of this presentation, participants will be able to:

1. Discuss current concepts and controversies in diagnosis of bowel injury.
2. Describe direct and indirect signs of blunt and penetrating bowel injury on MDCT.
3. Highlight pitfalls in diagnosis of bowel injury.

CONTROVERSIES IN FEMOROACETABULAR IMPINGEMENT

Dr. Kawan S. Rakhra 14:30–15:00

PRESENTATION SUMMARY: The topic of femoroacetabular impingement (FAI) has grown over the last decade, with imaging playing a significant role in its diagnosis. However, there remains uncertainty amongst radiologists regarding the imaging protocols, as well as the quantitative and qualitative information required by orthopaedic surgeons for management of the condition. This session will review the specific radiographic projections and MRI protocol essential in detecting the primary anatomic dysmorphisms and secondary joint derangements that can result. In addition, some of the common concerns and questions of radiologists regarding the alpha angle measurement will be addressed.

LEARNING OBJECTIVES: At the end of this presentation, participants will be able to:

1. Implement the appropriate radiograph and MRI protocols for investigating FAI.
2. Identify the key primary anatomic dysmorphisms of FAI and the secondary joint derangement that ensues.
3. Recognize the significance and limitations of quantitative parameters, namely the alpha angle.

RESIDENT REVIEW: THORACIC IMAGING, PART 2

13:30–15:00
Salle de bal est
Moderator: Dr. Cameron Hague

PRESENTATION SUMMARY: The CAR is proud to present the annual case-based resident review session, part 2. This radiology overview is targeted to residents, clinical fellows, as well as to practicing radiologists interested in updating their working knowledge of cardiothoracic imaging.

Following these sessions, attendees will be able to appreciate the utility of various imaging modalities used to image the heart and lungs (namely x-ray, CT and MR), accurately describe and provide differential diagnoses for common cardiac and thoracic pathologies, and understand the role the radiologist plays in caring for patients with cardiothoracic disease.

These sessions are planned to be practical, with emphasis placed on what the graduating resident needs to know.

CARDIAC CT: BEYOND THE CORONARY ARTERIES

Dr. João R. Inácio 13:30–14:00

PRESENTATION SUMMARY: Following a case-based review format, examples of extra-coronary findings of cardiac CT studies will be reviewed. Common abnormalities of the myocardium, cardiac valves, pericardium and extra-cardiac will be discussed with emphasis on characteristics findings and differential diagnosis.

LEARNING OBJECTIVES: At the end of this presentation, participants will be able to:

1. Review important abnormalities identified on cardiac CT studies, beyond the assessment of the coronary arteries.
2. Emphasize the importance of a structured approach to interpreting cardiac CT studies.
3. Illustrate important diagnoses in cardiac CT studies in patients referred for coronary artery disease assessment.

THE MEDIASTINUM

Dr. Giselle Revah 14:00–14:30

PRESENTATION SUMMARY: This presentation is geared towards residents and aims to assist in optimally evaluating the mediastinum on both radiographs and CT. The intention is to help residents in their clinical practice as well as to give some practical advice for the radiology exam.

LEARNING OBJECTIVES: At the end of this presentation, participants will be able to:

1. Describe mediastinal anatomy.
2. Compartmentalize mediastinal masses using x-ray and CT.

DIFFUSE AIR SPACE DISEASE

Dr. Daria Manos 14:30–15:00

PRESENTATION SUMMARY: This fast-paced, image-rich review of diffuse air space disease will include both chronic and acute pathology with a focus on pattern recognition and key problem-solving tools. We will review all the most important diagnoses and outline a practical step-by-step approach to formulating a narrow and clinically-oriented differential diagnosis. Common errors and commonly missed diagnoses will be highlighted.

LEARNING OBJECTIVES: At the end of this presentation, participants will be able to:

1. Recognize key CT features that allow distinction between various causes of chronic diffuse ground-glass opacity.
2. Highlight the importance and limitations of both clinical context and CT appearance in the differential diagnosis of acute air space disease.
3. Identify imaging features of non-infectious consolidation, including organizing pneumonia, eosinophilic pneumonia, lipoid pneumonia and consolidative malignancies.

CAR HOT TOPICS

15:30–17:00
Salle de bal ouest
Moderator: André Picard

Each of these two presentations will be 25 minutes, followed by a 40-minute interactive question period.

FISCAL PRESSURES ON HEALTHCARE IN QUEBEC

The Honourable Dr. Gaétan Barrette 15:30-15:55

PRESENTATION SUMMARY: Dr. Barrette will speak about the fiscal pressures on healthcare in Quebec and some solutions to managing these pressures in the future. He will also discuss federal and provincial constitutional responsibilities when it comes to financing health care in Canada and in Quebec. His presentation will make use of data related to health care spending in Quebec, along with data and analysis about the role of federal contributions in healthcare spending.

LEARNING OBJECTIVES: At the end of this presentation, participants will be able to:

1. Identify the major elements of Canada's healthcare system.
2. List current health policy issues and trends in Canada and abroad.
3. Summarize the processes by which public policies are formed and implemented.
4. Identify the roles and responsibilities of the federal and provincial governments related to healthcare financing and regulation.

ACCESS TO HEALTHCARE IN CANADA AND HOW CANADA RANKS COMPARED TO THE REST OF THE WORLD

Dr. Brian Day 15:55 – 16:20

PRESENTATION SUMMARY: Dr. Day will speak about access to healthcare in Canada, and how Canada ranks compared to the rest of the world. Dr. Day will discuss possible solutions to help address the perceived shortage of health system resources and rationed access to care. The presentation will examine how the cost and efficiency of Canada's healthcare system compare to international examples, while emphasizing the importance of sustainability. As a leading proponent of alternative, privatized models of Canadian healthcare service delivery, he will also discuss his legal challenge to the province of British Columbia's ban on the purchase of private insurance for medically-necessary services that are already covered by the public system.

LEARNING OBJECTIVES: At the end of the presentation, participants will be able to:

1. Identify the major elements of Canada's healthcare system.
2. List current health policy issues and trends in Canada and abroad.
3. Summarize the processes by which public policies are formed and implemented.
4. Identify the roles and responsibilities of the federal and provincial governments related to healthcare financing and regulation.

BREAST IMAGING

15:30–17:00
Salon Drummond, Level 3
Moderator: Dr. Jean Seely

RADIOACTIVE SEED LOCALIZATION: PRACTICAL TIPS FOR STARTING THE PROGRAM

Dr. Jean M. Seely 15:30–16:00

PRESENTATION SUMMARY: With use of widespread screening mammography, most breast cancers are detected at an early stage. To localize early stage breast tumours for surgery, image-guided localization is usually performed using wire localization, with ultrasound or mammographic guidance. A new method of breast localization, radioactive seed localization, is an innovative way of placing a tiny radioactive seed, embedded with a very low dose of radioactivity, into a breast cancer, allowing the surgeon to localize the tumour at the time of surgery. The seed may be placed into a patient's tumour up to one week prior to surgery. There are many benefits to this technique, including reduced patient complications, improved patient satisfaction, reduced hospital costs, improved operating room efficiency, and improved surgical outcomes. This presentation will cover the technique of performing radioactive seed localization, the benefits of introducing the program in a large Canadian centre, and the steps required to establish this program.

LEARNING OBJECTIVES: At the end of this presentation, participants will be able to:

1. Identify the multidisciplinary approach required to start a radioactive seed localization program.
2. List the steps required to begin the program in your hospital. (CanMEDS: Leader and Health Advocate)
3. Describe the benefits of the program for patients, radiologists, and surgeons using imaging examples. (CanMEDS: Health Advocate)

BREAST TOMOSYNTHESIS IN PRACTICE: EARLY EXPERIENCE WITH SCREENING AND DIAGNOSIS

Dr. Shiela Appavoo 16:00–16:30

PRESENTATION SUMMARY: Digital breast tomosynthesis (DBT) has been approved for practice within Canada for less than two years. During that time, my practice has adopted its use in screening and diagnosis. This presentation will briefly discuss the evidence and practical challenges, and show some illustrative challenging cases encountered within the first months with this new modification to an established modality.

LEARNING OBJECTIVES: At the end of this presentation, participants will be able to:

1. Describe evidence regarding DBT in screening as well as practical obstacles to incorporating DBT into practice.
2. Recognize alterations in everyday practice that may be required when initiating a DBT program. (CanMEDS: Health Advocate and Leader)

BREAST MRI: RECENT ADVANCES

Dr. Lara Richmond 16:30–17:00

PRESENTATION SUMMARY: This presentation will review recent advances in the use of breast MRI in the breast cancer screening setting as well as in the setting of breast disease.

LEARNING OBJECTIVES: At the end of this presentation, participants will be able to:

1. Describe recent advances in breast MRI in the screening setting.
2. Describe recent advances in breast MRI in the setting of breast disease.
3. Apply and share this knowledge as a medical expert to provide enhanced patient-centred care. (CanMEDS: Communicator and Health Advocate)

JUNIOR HOT SEAT SESSION FOR RESIDENTS (PGY-1, 2 AND 3)

15:30–17:00
Salon 4, Level 2
Moderator: Dr. Cameron Hague

JUNIOR HOT SEAT SESSION FOR RESIDENTS (PGY-1, 2 AND 3)

Dr. Angus Hartery and Dr. Marie-Hélène Lévesque

This is a small group session with restricted attendance for radiology residents who have pre-registered.

PRESENTATION SUMMARY: This session will provide participating residents with a foundation for approaching cases in a "hot seat" setting in preparation for various examinations. Cases presented during this session will have focus on cardiothoracic imaging.

The cases will be discussed and feedback will be given to individuals and to the group.

LEARNING OBJECTIVES: At the end of this small group discussion, participants will be able to:

1. Assimilate and apply pertinent differential diagnoses in radiology related to the sample cases.
2. Apply a patterned approach to radiographic disease via a case-based approach.
3. Analyze feedback received from the moderators and use it to improve skills while interpreting cases orally.

SENIOR HOT SEAT SESSION FOR RESIDENTS (PGY-3, 4 AND 5)

15:30 - 17:00
Salon 5, Level 2
Moderator: Dr. Cameron Hague

SENIOR HOT SEAT SESSION FOR RESIDENTS (PGY-3, 4 AND 5)

Dr. Julie Hurteau-Miller and Dr. Johnathan Scheske

This is a small group session with restricted attendance for radiology residents who have pre-registered.

PRESENTATION SUMMARY: This session will provide participating residents with a foundation for approaching cases in a "hot seat" setting in preparation for various examinations. Cases presented during this session will have focus on cardiothoracic imaging.

The cases will be discussed and feedback will be given to individuals and to the group.

LEARNING OBJECTIVES: At the end of this small group discussion, participants will be able to:

1. Assimilate and apply pertinent differential diagnoses in radiology related to the sample cases.
2. Apply a patterned approach to radiographic disease via a case-based approach.
3. Analyze feedback received from the moderators and use it to improve skills while interpreting cases orally.

WINE & CHEESE RECEPTION AND AWARDS CEREMONY

New this year, the CAR invites **all of its meeting delegates** to join us in celebrating this year's distinguished award winners and this year's successful CAR contest winners at the **CAR Wine & Cheese Reception and Awards Ceremony**. This is a complimentary social event as part of the ASM registration.

CAR Gold Medal Award – Dr. Raquel Z. delCarpio-O'Donovan

CAR Distinguished Career Achievement Award – Dr. Karel ter Brugge (award to be presented in person on Friday at the 80th Anniversary Celebration Cocktail)

CAR Young Investigator Award – Dr. Nicola Schieda

We will also be honouring our many volunteers for their invaluable contributions to the CAR. The CAR exists because of the work they do in the name of radiology in Canada.

Saturday, April 22
5:30 p.m. – 7:15 p.m.
Salle de bal est, Level 4

SOIRÉE VINS ET FROMAGES ET REMISE DES PRIX DE LA CAR

Pour la première fois cette année, la CAR convie **tous les délégués du Congrès scientifique annuel à la Soirée vins et fromages et remise des prix de la CAR** organisée en l'honneur des lauréats des prix remis cette année et des gagnants des concours de la CAR. Cette activité sociale est offerte gracieusement avec l'inscription au Congrès.

Prix de la Médaille d'or de la CAR – Dre Raquel Z. delCarpio-O'Donovan

Prix d'excellence de la CAR pour une éminente carrière – Dr Karel ter Brugge (prix remis en personne lors de la soirée cocktail du 80e anniversaire)

Prix du jeune chercheur de la CAR – Dr Nicola Schieda

Nous soulignerons également la précieuse contribution des nombreux bénévoles de la CAR. L'association doit son existence au travail qu'ils accomplissent pour la radiologie au Canada.

Samedi 22 avril
De 17 h 30 à 19 h 15
Salle de bal est, niveau 4

MORNING TRACKS — SUNDAY, APRIL 23, 2017

PLENARY SESSION: CMPA — MOBILE DEVICE USE IN CLINICAL PRACTICE: OPPORTUNITIES AND REALITIES

Dr. Tino D. Piscione
08:00–8:40
Salle de bal ouest

This presentation will be 30 minutes, followed by a 10-minute interactive question period.

PRESENTATION SUMMARY: Increasingly, physicians are leveraging the reach and practical convenience of personal mobile devices to facilitate communication related to their clinical work, network with other physicians, and engage in just-in-time education. While the use of personal mobile devices in clinical practice offers opportunities for expeditiously sharing information related to patient care with other health care providers, as well as with patients, physicians must recognize the risks associated with personal mobile device usage for communicating confidential, and sometimes highly sensitive, patient-related information. In this session, the pitfalls of using personal mobile devices in clinical work will be highlighted. Also, legal and professional obligations relevant to physicians regarding electronic information security and privacy (e-privacy) will be outlined. Finally, the risks and benefits of engaging in social media for professional purposes will be discussed.

LEARNING OBJECTIVES: At the end of this presentation, participants will be able to:

1. List four medical-legal pitfalls of using personal mobile devices in clinical work.
2. Discuss regulations that govern "e-privacy".
3. Describe the do's and don'ts for physicians considering or actively engaging in social media for professional purposes.

MISTAKES WE ALL MAKE

08:45–12:15
Salle de bal ouest
Moderator: Dr. Caitlin McGregor

NEURORADIOLOGY

Dr. Carlos Torres 08:45–09:15

PRESENTATION SUMMARY: Early in diagnosis, radiologists rely on pattern recognition when assessing the features of an imaging finding. If the condition is recognized, automatic "type 1" processes will rapidly and effortlessly make the diagnosis and nothing further may be required. If not recognized, linear, analytical and effortful "type 2" processes are engaged instead. These cognitive processes could also be impacted by internal (fatigue, stress) and external (lighting) factors [1].

This presentation illustrates cognitive errors including anchoring bias, framing bias, availability bias, premature closure and satisfaction of search. We will also discuss system issues that lead to visual and mental fatigue. Finally, we will review potential solutions to minimize diagnostic errors. (Ref: 1. Lee C, Nagy PG, Weaver SJ et al. Cognitive and System Factors Contributing to Diagnostic Errors in Radiology. AJR 2013; 201: 611—17.)

LEARNING OBJECTIVES: At the end of this presentation, participants will be able to:

1. Describe cognitive and system-based errors in neuroradiology, using a case-based format.
2. Review the sources of errors and discuss potential solutions.

EMERGENCY RADIOLOGY

Dr. Faisal Khosa 09:15–09:45

PRESENTATION SUMMARY: This presentation will illustrate errors in the acute care setting, which is unique because of high volume, complexity of cases and timeliness of interpretation.

LEARNING OBJECTIVES: At the end of this presentation, participants will be able to:

1. Describe the benefits of adopting the PI-RADS V2 standardized reporting system for prostate MR, particularly for clinicians.
2. Identify the technical requirements for standard-of-care prostate MRI under PI-RADS V2 guidelines.
3. Outline the basic components of the PI-RADS V2 reporting system.

MISTAKES WE ALL MAKE (CONTINUED)

08:45–12:15
Salle de bal ouest
Moderator: Dr. Caitlin McGregor

IMPROVING MSK INTERPRETATION PROWESS

Dr. Dean Bruce 09:45–10:15

PRESENTATION SUMMARY: As radiologists, we should always strive to improve our detection methods and interpretation of imaging studies. Musculoskeletal pathology can be overlooked, but with certain analysis techniques we can reduce the amount of clinically important misses. Relaying the significance of image-detected pathology through proper reporting is also vital, and a few examples will be shown in this regard.

LEARNING OBJECTIVES: At the end of this presentation, participants will be able to:

1. Recognize more accurately musculoskeletal pathology through individual cases.
2. Apply imaging interpretation techniques to help reduce misses.
3. Improve detection of important but uncommon musculoskeletal pathology.

ABDOMINAL IMAGING

Dr. Angus Hartery 10:45–11:15

PRESENTATION SUMMARY: Unknown cases will be presented with an audience response system. Audience participation is encouraged with the use of a smartphone/tablet/laptop. A variety of systems and modalities will be presented with discussion. A review of types of interpretative errors will also be performed.

LEARNING OBJECTIVES: At the end of this presentation, participants will be able to:

1. Present examples of common errors that occur when interpreting abdominal imaging studies.
2. List the types of errors that can occur in image interpretation.
3. Develop strategies to minimize misinterpretations.

MAKING THE BLACK BOX OF THE HEART MORE TRANSPARENT

Dr. Elena Peña 11:15–11:45

PRESENTATION SUMMARY: We will demonstrate a stepwise approach to examine the heart on non-gated CT chest examinations. Additionally, we will highlight clinically significant, cardiac imaging findings, through real-life cases. Finally, we will explain the importance of reporting coronary artery calcification in the lung cancer screening era.

LEARNING OBJECTIVES: At the end of this presentation, participants will be able to:

1. Apply a stepwise approach to examine the heart on chest CT.
2. Diagnose common clinically-significant, reportable cardiac findings.
3. Discuss the importance of reporting coronary artery calcifications on non-gated CT chest examinations.

VASCULAR IMAGING AND INTERVENTION

Dr. Jason Clement 11:45–12:15

PRESENTATION SUMMARY: There are a small number of common themes that account for the majority of common mistakes made in vascular imaging and intervention. These common sources of errors and complications will be discussed and illustrated with particular examples. Strategies to minimize these common errors will be discussed.

LEARNING OBJECTIVES: At the end of this presentation, participants will be able to:

1. Identify the common mistakes that are made in diagnostic vascular imaging and vascular intervention.
2. Describe strategies for minimizing the most common vascular imaging mistakes.
3. Describe strategies for minimizing the most common vascular intervention mistakes.

CAR CONTESTS – ABSTRACTS
CONCOURS DE LA CAR – RÉSUMÉS

All the Educational Exhibits are in digital format and are available for viewing in the foyer of the Salle de bal, 4th floor.
THURSDAY, APRIL 20, 2017 – SUNDAY, APRIL 23, 2017
Prizes for this contest are funded by the Canadian Radiological Foundation (CRF) and will be awarded during the Wine and Cheese Reception and Awards Ceremony on Saturday, April 22, 2017.

Toutes les expositions éducatives sont en format numérique et peuvent être visionnées dans le foyer de la Salle de bal au 4e étage.
JEUDI LE 20 AVRIL 2017 – DIMANCHE LE 23 AVRIL 2017
Les prix pour ce concours sont financés par la Fondation radiologique canadienne (FRC) et seront remis samedi, le 22 avril, lors de la Soirée vins et fromages et remise des prix.

JUDGES / JUGES : Dr. Andreu Costa, Dr. Derek Emery, Dr. Valerie Keough

EE001

MISSED ACUTE APPENDICITIS ON MDCT AND MRI: LEGAL RAMIFICATIONS, CHALLENGES, AND AVOIDANCE STRATEGIES

Authors: Michael N. Patlas, Victoria Chernyak, Abraham H. Dachman, Douglas S. Katz

LEARNING OBJECTIVES:

1. To discuss the legal ramifications of the missed or incorrect imaging diagnosis of acute appendicitis (AA) by radiologists.
2. To review legal and radiological literature.
3. To illustrate common misinterpretations in the diagnosis of AA on MDCT and MRI examinations, based on lessons learned from Morbidity & Mortality Rounds.

BACKGROUND: The failure to diagnose AA is the third most common incorrect GI diagnosis resulting in medical malpractice allegations. The medical-legal aspects of missed and/or delayed diagnosis of AA will be reviewed. The misinterpretation of imaging examinations in patients with suspected appendicitis may be caused by suboptimal technique, failure to review a portion of the examination, satisfaction of search error, and the misinterpretation of imaging findings. This exhibit will review optimised MDCT and MRI protocols for the detection of AA.

CONCLUSION: This exhibit offers an opportunity to review common mistakes in diagnosis of the AA on MDCT and MRI, to review the imaging, clinical, and legal literature on this specific topic, and also suggests strategies to avoid potential misinterpretations.

EE002

BENIGN AND MALIGNANT PERIPHERAL NERVE SHEATH TUMORS: REVIEW OF PERIPHERAL NERVE ANATOMY AND IMAGING CHARACTERISTICS

Authors: Fateme Salehi, Stephany Pritchett

LEARNING OBJECTIVES:

1. To review upper and lower limb peripheral nerve anatomy commonly associated with peripheral nerve sheath tumors.
2. To provide detailed overview of both benign (schwannoma and neurofibroma) and malignant peripheral nerve sheath tumors in regards to pathology, demographics, natural history, and imaging features, including findings on MRI, CT and ultrasound.
3. To review the differential diagnosis for each tumor, and highlight the distinguishing features.
4. To outline and review the features associated with malignant versus benign tumors.

BACKGROUND: Schwannomas and neurofibromas comprise the two major groups of solitary benign peripheral nerve sheath tumors (PNSTs). Both are associated with Schwann cells and can arise almost anywhere along the course of peripheral nerves. Therefore, an intimate knowledge of peripheral nerve anatomy is required to assist in diagnosis of peripheral nerve sheath tumors. Although distinguishing between the different types of PNSTs is often difficult, certain imaging features can assist the radiologist to differentiate between PNSTs and other soft tissue tumors.

CONCLUSION: Knowledge of peripheral nerve anatomy along with unique imaging characteristics of PNST tumors on different imaging modalities enable the radiologist to narrow down the differential diagnosis of soft tissue tumors, and aid with appropriate management. We highlight the pertinent distinguishing imaging findings and provide a detailed overview of upper and lower extremity peripheral nerve anatomy, with representative images including MRI, CT, and Ultrasound of benign and malignant PNST subtypes.

EE003

CARDIOMYOPATHY: A REVIEW OF ADVANCED CARDIAC MR IMAGING FEATURES

Authors: Stacey L. Speer, Ian Ross

LEARNING OBJECTIVES: At the end of this educational exhibit, the participant will be able to:

1. Identify the role of cardiac MRI in the assessment of cardiomyopathy.
2. Identify the imaging features of ischemic cardiomyopathy and a variety of non-ischemic cardiomyopathy etiologies.
3. Differentiate between the MRI enhancement patterns post gadolinium in both ischemic and non-ischemic cardiomyopathy.

BACKGROUND: Cardiomyopathies are a heterogenous group of diseases affecting the myocardium with associated mechanical and/or electrical cardiac dysfunction. They are classified as primary or secondary cardiomyopathy and may include: dilated cardiomyopathy, hypertrophic cardiomyopathy, restrictive cardiomyopathy, and arrhythmogenic right ventricular cardiomyopathy. Cardiac MRI has become a fundamental imaging modality for the diagnosis and follow-up of cardiomyopathies as it allows for high-resolution morphologic assessment, evaluation of cardiac function and trans-valvular flow, and assessment of delayed gadolinium enhancement of the myocardium.

CONCLUSION: The radiologic assessment of cardiomyopathy is a common request for advanced cardiac MRI imaging. Knowledge of the multitude of etiologies, the clinical presentation and the cardiac MRI features is essential for both academic and community radiologists alike. This educational exhibit demonstrates the critical role of cardiac MRI assessment in cardiomyopathy, provides a review of ischemic and non-ischemic cardiomyopathy etiologies and demonstrates the importance of post gadolinium enhancement in making the diagnosis.

EE004

DIAGNOSIS AND IMAGING OF PANCREATIC AND DUODENAL INJURIES

Authors: Yuhao Wu, Ismail Ali, Sheldon Clark, Faisal Khosa, Patrick McLaughlin, Omar Metwally, Savvas Nicolaou

LEARNING OBJECTIVES:

1. Review the mechanisms of injury, clinical manifestations, and the AAST grading schemes of pancreatic and duodenal injuries.
2. Discuss the different imaging modalities for imaging pancreatic and duodenal injuries, with an emphasis on multi-detector computed tomography (MDCT) as the modality of choice in acute situations.
3. Demonstrate the spectrum of imaging findings on MDCT and magnetic resonance imaging with cholangiopancreatogram (MRCP).
4. Describe how imaging findings guide the clinical management of pancreatic and duodenal injuries.

BACKGROUND: Pancreatic and duodenal trauma results after blunt injury to the upper abdomen. Despite their rare occurrences, pancreatic and duodenal injuries are life-threatening conditions. The majority of early deaths are due to coexisting injuries or hemorrhages, while deaths form late injuries are attributed to complications resulting from the injuries. Imaging plays an essential role in the assessment and management of these patients.

CONCLUSION: Multi-detector computed tomography (MDCT) plays an important role in the assessment of acute pancreatic and duodenal injuries. Becoming aware of the injury patterns is important for identifying the subtle radiological signs to guide prompt interventions, which reduces mortality and morbidity.

EE005

EDUCATING PATIENTS AND MEDICAL STUDENTS ABOUT INTERVENTIONAL RADIOLOGY WITH THE USE OF 3D PRINTED MODELS

Authors: Jason Kinnin, Ravindra Gullipalli

LEARNING OBJECTIVES: After viewing this exhibit, participants should be able to:

1. Understand that 3D printing can be used to create life-like models using data from CT and MRI scans.
2. Recognize the educational value of using 3D models to explain interventional radiology procedures to students and patients.
3. Explain this project to colleagues at their home institutions and, if desired, develop their own applications for 3D printed models in diagnostic and interventional radiology.

BACKGROUND: 3D Printing is quickly becoming a widely used modality for tasks such as making parts for manufacturing, printing biologic materials, and even personal home use. It has many applications in the field of medicine, one of which is the ability to create 3D models of patients' anatomy for visualization and preparation before surgeries. These models can be used to educate patients, medical students, and residents so they can learn about internal anatomy and surgical procedures by visualizing physical 3D models.

CONCLUSION: In conclusion, this education exhibit will explain how digital CT and MRI scans can be usd to create life like 3D printed models. These models can be used to then educate patients and students in the field of interventional radiology by printing models of human vasculature which can help them visualize the internal anatomy and get a better understanding of how procedures are performed. Both students and patients report increased satisfaction of their care and improvement in their knowledge from education using these 3D models.

EE006

FLUOROSCOPY GUIDED STERNOPLASTY: INSTITUTIONAL EXPERIENCE AND REVIEW OF LITERATURE

Authors: S M N. Sakib, Yair B. Levy, Naudare M. Shabandi, Suken Shah

LEARNING OBJECTIVES:

1. Review the anatomy and imaging characteristics of sternal fractures.
2. Compare the conventional treatments of sternal fractures and their risks.
3. Describe the mechanism, benefits and risks of sternoplasty.

BACKGROUND: Sternal fractures occur in 3-6% of cases involving motor vehicle collisions. Prognosis is excellent for isolated sternal fractures. The overall mortality of sternal fractures is 0.7%. Computed Tomography (CT) is the imaging modality of choice in the diagnosis. Usually the fracture is transverse and is non-displaced. Associated injuries include aortic, myocardial contusions, retrosternal and mediastinal hematomas. Although most heal spontaneously, it can be very painful which limits respiration, predisposing to atelectasis and pneumonia, especially in patients with underlying lung disease.

CONCLUSION: Operative fixation may be indicated for displaced or unstable fractures, which cause debilitating chest pain or associated with flail chest. Localized injections or indwelling catheters for pain control are other options. However all these have their own inherent risks. Sternoplasty is minimally invasive and has potential for immediate and long term pain relieve and is a viable alternative to open surgery, indwelling catheters or injections. However, with limited cases, more studies are needed to establish clinical efficacy.

EE007

TRIGEMINAL NEURALGIA-PICTORIAL ESSAY

Authors: Rafael Glikstein, Nadav Berkovitz, Jorge Davila, Carlos Torres

LEARNING OBJECTIVES:

1. To review the anatomy of the trigeminal nerve.
2. To review different pathologies causing trigeminal neuralgia.
3. To review clinical diagnosis of trigeminal neuralgia.

BACKGROUND: Trigeminal neuralgia is a pathology that may affect one or the tree branches of division of the trigeminal nerve. The prevalence is variable, between 0.01 and 0.3% of the population, more common in women, generally appears at the age of 40. It is classically divided in typical or atypical, the first one characterized by spontaneous acute burning pain on the trigeminal nerve (V CN) distribution which may last few seconds up to few minutes, and the atypical type which is a constant stabbing pain. MRI is the elective method for diagnosis of this entity.

CONCLUSION: MRI studies including high resolution T2 imaging centered on the intracisternal segment of the trigeminal nerve proved to be extremely sensitive to evaluate the anatomy of the trigeminal nerve, identify small lesions, mass effect or atrophy of the trigeminal nerve, and should be included on the protocol of exploration. Thin slice post Gd T1 following the trigeminal nerve and branches of division is required to reassure the presence or absence of pathology, in coronal plane, preferably fat sat.

EE008

MAY-THURNER SYNDROME: AN UNDERRECOGNIZED CAUSE OF LEFT ILIOFEMORAL DEEP VENOUS THROMBOSIS

Authors: Sean A. Kennedy, Edwin Zhang

LEARNING OBJECTIVES:

1. To review the anatomy and pathophysiology of May-Thurner Syndrome.
2. To review the clinical evaluation and imaging findings associated with May-Thurner Syndrome.
3. To review therapeutic options available for May-Thurner Syndrome using illustrative case presentations.

BACKGROUND: May-Thurner Syndrome results from venous outflow obstruction of the left lower limb secondary to compression of the left common iliac vein by the right common iliac artery. Often underrecognized, May-Thurner Syndrome can lead to multiple complications including recurrent deep venous thrombosis, post-thrombotic syndrome and phlegmasia cerulean dolens. Treatment options include medical, endovascular, and surgical options. We hope to provide a concise evidence-based overview of the diagnosis and management of May-Thurner Syndrome using illustrative cases.

CONCLUSION: May-Thurner Syndrome places patients at high risk for thrombosis-related complications in the left lower limb. It is important to think of this diagnosis when presented with a patient with left lower extremity DVT. Endovascular treatment has become the mainstay management option for these patients.

EE009

THE CLINICAL AND MULTI-MODAL IMAGING FEATURES OF STRUMA OVARII WITH PATHOLOGIC CORRELATION AND MANAGEMENT GUIDELINES

Authors: Ashley Leckie, Joseph Barfett, Kirsteen R. Burton, Vlachou (Laurie) Paraskevi

LEARNING OBJECTIVES: By the end of this session, participants will be able to:

1. Describe the basic pathophysiology and clinical features of struma ovarii.
2. Distinguish struma ovarii from other ovarian tumours by the multi-modal imaging features presented.
3. Summarize the current management guidelines for struma ovarii.

BACKGROUND: Struma ovarii are rare ovarian teratomas, which account for approximately 3% of all ovarian teratomas and 0.3% of all ovarian tumours. Composed primarily of thyroid tissue (>50%), women may present with unexplained thyrotoxicosis (approximately 5-8%); however, more commonly women present with a palpable pelvic mass, nonspecific abdominal pain or ascites. Specific imaging investigations help to diagnose struma ovarii. We present a case of a 33-year old female with symptoms suspicious for struma ovarii.

CONCLUSION: While rare, struma ovarii is an important diagnostic consideration in women presenting with unexplained hyperthyroidism. Ultrasound, magnetic resonance imaging and nuclear imaging play key roles in the detection and diagnosis of this treatable neoplasm.

In conclusion, within this session we will:

1. Present the clinical features and describe the pathophysiology of struma ovarii.
2. Introduce the key imaging modalities and features commonly used to distinguish struma ovarii from other ovarian tumours.
3. Summarize the current management guidelines for struma ovarii, including fertility preserving approaches.

EE010

THE CANADIAN MEDICAL IMAGING INVENTORY (CMII): BENEFITS FOR DECISION MAKERS

Authors: Andra Morrison, Lesley Dunfield, Kasia Kaluzny, Lisa Pyke, Teo Quay, Alison Sinclair, Paul Ting

LEARNING OBJECTIVES:

1. To understand the main benefits of the Canadian Medical Imaging Inventory (CMII) for decision-makers.

BACKGROUND: This information captured by the CMII helps to guide planning and other decisions and helps identify gaps in service. As well, the data captured in the report enables CADTH to work with health care leaders, professional and clinical societies, and other stakeholders to identify and address critical barriers to the effective use of medical imaging.

CONCLUSION: The Canadian Medical Imaging Inventory (CMII): Benefits for decision makers.

USAGE DATA

Usage data may help decision-makers to understand future demand for medical imaging equipment by understanding aspects of current capacity:

- Location of hospitals providing 24 hour and weekend services.
- Range of potential life expectancy of equipment based on use.
- Whether existing equipment can be used more optimally.
- Options for managing wait time targets, by diverting patients to underused sites.

EQUIPMENT DATA

The CMII also collects data on the age, location and technical characteristics of equipment. This may help guide Canadian projections for future imaging equipment needs, such as:

- When equipment might be replaced, upgraded, or refurbished in accordance with CAR guidance
- Where equipment might be needed
- Mobile equipment and its deployment
- Equipment that tracks radiation dosage

Information on equipment characteristics can be exchanged between hospitals for purposes of information sharing, best practice, and for guidance on implementing new equipment. As well, the CMII provides Canadian data for OECD comparisons for CT and MRI.

EE011

SUBTLE PULMONARY NODULES ON CHEST RADIOGRAPHY: AN INTERACTIVE DETECTION SKILLS QUIZ

Authors: Laura A. Fitzpatrick, Daria Manos

LEARNING OBJECTIVES: At the end of this presentation, participants will be able to:

1. Identify subtle solitary pulmonary nodules on a series of chest radiographs and compare with correlative computed tomography (CT) images.
2. Identify factors that may contribute to poor detection of nodules on chest radiographs.
3. Recognize the medicolegal consequences of a missed pulmonary nodule.
4. Develop a personalized strategy to improve detection skills.

BACKGROUND: There has been a decline in chest radiograph interpretation skills and comfort level among radiology trainees since the introduction of more advanced imaging modalities. However, chest radiography remains a valuable diagnostic tool and many patients will not receive imaging with CT unless an abnormality is detected by radiograph. In addition to adverse outcomes in patient care, there are significant legal implications associated with missed findings. Up to 90% of lawsuits resulting from missed lung cancer involve errors in radiograph interpretation.

CONCLUSION: Chest radiography continues to be the primary modality used for the detection of solitary pulmonary nodules in both the inpatient and outpatient setting. In addition to the medicolegal consequences, a missed lung nodule is associated with increased patient morbidity and mortality. Practices that can improve detection skills include maximizing reporting volumes in residency, using a systematic approach with particular attention to blind spots, comparing with prior studies and retrospectively reviewing the corresponding radiographs when reporting all CTs of the chest.

EE012

BREAST SIDE STORY: SECRETS TOLD BY MAMMOGRAPHY

Authors: Klaudia Jumaa, Ilanit Ben Nachum, Anat Kornecki, Giulio Muscedere, Olga Shmuilovich

LEARNING OBJECTIVES: At the end of this session, participants will be able to:

1. Recognize non-breast-cancer manifestations of disease in the breast.
2. Identify imaging features which distinguish non-breast-cancer diseases from primary breast malignancy.
3. Interpret breast findings in the context of systemic disease.
4. Integrate multi-modality imaging findings with clinical history.
5. Establish a diagnosis, recommend appropriate follow-up when needed, and confidently avoid unnecessary intervention and call-backs.

BACKGROUND: It's not uncommon for non-breast cancer conditions to manifest abnormalities on mammography. Now and again, benign findings offer a unique window into the patient's medical history, social history, or personal habits. Rarely, these findings can be the first presentation of a systemic disease or critical illness. Occasionally, they may mimic malignancy and result in unnecessary call-backs and interventions. These findings are common although largely unrecognized as mammography is mainly interpreted in the context of breast cancer screening or work-up.

CONCLUSION: Cases will be presented in quiz format. Key findings that help differentiate abnormalities from malignancy will be highlighted. Abnormalities associated with pathologies requiring further workup will be reviewed. Categories include:

- Breast parenchyma: hormonal/drug-induced, metastasis, weight changes
- Trabecular thickening: CHF, lymphangitic spread, venous obstruction
- Lymph nodes: lymphoma, multiple myeloma, amyloidosis
- Skin: lymphoma, NF 1
- Chest wall: sarcoma, developmental abnormalities
- Calcifications: vascular (diabetes), dermatomyositis
- Post-trauma: fat necrosis, burns, air injection

After completion of this exhibit, the reader will be able to identify abnormal findings, differentiate non-malignant disease from breast malignancy, and determine whether follow-up, referral, or further intervention is required.

EE014

MULTIPLE CEREBRAL MICROHEMORRHAGES – COMMON AND INFREQUENT ETIOLOGIES AND MIMICS

Authors: Vered P. Tsehmaister-Abitbul, Carlos Torres, Nader Zakhari

LEARNING OBJECTIVES: To review the differential diagnosis of cerebral microhemorrhages on MRI.

BACKGROUND: With recent advances in MRI technology, the increasing wide spread use of higher magnetic field strength (3 Tesla) and the inclusion of susceptibility-weighted imaging(SWI) in the standard brain MRI protocols, cerebral microhemorrhages have become an increasingly common neuroimaging finding. Although previously considered clinically silent, their important clinical relevance is now recognised, particularly, in the context of ageing, cerebrovascular disease and dementia. This pictorial essay will discuss the common, infrequent and rare etiologies of multiple cerebral microhemorrhages and their potential mimics.

CONCLUSION: As neuroradiologists, we should be familiar with the many possible causes of multiple microhemorrhages in order to suggest the most appropriate diagnosis and guide patient management. In this pictorial essay, we address the common, the infrequent and the rare causes of cerebral microbleeds based on the GRE or SWI sequences and we discuss the potential mimics.

EE015

ISCHEMIC STROKE: CURRENT EVIDENCE FOR ENDOVASCULAR MANAGEMENT

Authors: Sean A. Kennedy, Mark O. Baerlocher

LEARNING OBJECTIVES:

1. To review current endovascular therapies available in the treatment of acute ischemic stroke.
2. To review the current evidence and indications for the endovascular management of acute ischemic stroke.
3. To review the imaging selection strategies for the endovascular therapy of acute ischemic stroke.

BACKGROUND: Novel endovascular interventions have recently been shown to provide significant functional outcome benefits for acute ischemic stroke patients. Different endovascular therapies and strategies currently exist for treatment. Careful imaging selection is critical to obtain optimal benefit in these patients. We hope to provide a concise overview of the appropriate use of endovascular therapy for the treatment of acute ischemic stroke.

CONCLUSION: Endovascular therapy can provide significant functional outcome benefits for patients with acute ischemic stroke. Careful imaging selection is critical to achieving these positive outcomes.

EE016

THE LUMBOSACRAL DURAL SAC: IMAGING ANATOMY AND PATHOLOGY

Authors: Fahad Essbaiheen, Glikstein Rafael, Carlos H. Torres

LEARNING OBJECTIVES:

1. Emphasize the normal radiological anatomy of the lumbosacral dural sac.
2. Describe the imaging techniques for its assessment.
3. Highlight the common and unusual pathologies that can be seen within the thecal sac or that can compress it.

BACKGROUND:

NORMAL ANATOMY,

IMAGING TECHNIQUES: (MRI, CT, myelogram),

EXTRADURAL PATHOLOGIES COMPRESSING THE SAC: Degenerative spine disease (protruded disc, synovial cyst), spine neoplasia (metastasis, myeloma, GCT, hemangioma), epidural pathologies (hematoma, abscess, lipomatosis, extramedullry hematopoiesis) and normal variants (congenital short pedicles).

INTRADURAL PATHOLOGIES OR PATHOLOGIES THAT EXPAND THE SAC: Dural ectasia (Marfan's syndrome, Neurofibromatosis), neoplasia (drop metastasis, PNET, lymphoma) , infectious (TB, abscess) and hemorrhage (SAH).

PATHOLOGIES OF THE SAC CONTENTS: Sac (CSF leak, siderosis) Filum terminale (Tight filum, Fatty filum, myxopapillary ependymoma), Cauda equina (focal: schwannomas, paragangliomas, metastasis) and (diffuse: GBS, Arachnoiditis, lymphoma, Sarcoid, TB).

CONCLUSION: In this educational exhibit we describe the normal anatomy, imaging techniques and pathologies of the lumbosacral dural sac.

EE017

SUBMASSIVE AND MASSIVE PULMONARY EMBOLISM: CURRENT EVIDENCE FOR ENDOVASCULAR MANAGEMENT

Authors: Sean A. Kennedy, Mark O. Baerlocher, Robert Beecroft

LEARNING OBJECTIVES:

1. To review the classification of submassive and massive pulmonary emboli (PE).
2. To review current endovascular therapies available for the management of PE.
3. To review the evidence base behind endovascular PE therapies.
4. To review the concept of multidisciplinary PE Response Teams (PERTs).

BACKGROUND: Submassive and massive pulmonary emboli (PE) represent conditions with high morbidity and mortality. A variety of novel endovascular approaches show promise in the treatment of these patients. In a growing number of centres, multidisciplinary PE Response Teams, or 'PERTs', have been formed to optimize patient selection and treatment approach. We hope to provide a concise overview of the appropriate use of endovascular therapy in the management of PE, its supporting evidence, and a review of the concept of the PERT.

CONCLUSION: Submassive and massive PE are complex clinical conditions with poor outcomes. Novel endovascular approaches and PERTs represent possible means to improve these outcomes.

EE018

TRAUMATIC ACETABULAR FRACTURES: CLASSIFICATION MADE EASY!

Author: Matthew Wu

LEARNING OBJECTIVES: At the end of this educational exhibit, participants will be able to:

1. Identify the key anatomical landmarks of the innominate bone and establish their correlate on Radiographs and Computed Tomography (CT).
2. Diagnose and differentiate between the most common types of traumatic acetabular fractures using a systematic and practical approach.
3. Categorize the most common types of traumatic acetabular fractures into the Judet-Letournel Classification System.
4. Identify additional features that are not included in the Judet-Letournel classification system but are nevertheless important to include in reports as they have the potential to alter patient management.

BACKGROUND: Characterization of acetabular fractures is challenging:

1. The innominate bone is complex due to its curved and off-axis alignment. Mentally reconstructing on CT and plain film is difficult particularly when the anatomy is distorted by trauma.
2. The nomenclature and classification system is confusing. There are many types of acetabular fractures, however, up to 90% of acetabular fractures can be classified into just 5 categories.
3. Additional features not included in the classification can impact management and must be reported.

CONCLUSION: The participant will be able to identify the key pelvic anatomical landmarks and be able to classify traumatic acetabular fractures into the Judet-Letournel system. The participant will also be able identify key features not included in the classification system but are important for the surgeons to know.

EE019

INCIDENTALOMA MANAGEMENT: SUPPORTING PRIMARY CARE

Authors: Cindy A. Ochieng, Stefanie Lee

LEARNING OBJECTIVES:

1. Identify family medicine guidelines for management of common incidental findings.
2. Identify radiology guidelines for management of common incidental findings.
3. Compare family medicine and radiology management of common incidental findings.
4. Discuss how radiology can support family medicine's management of incidentalomas.

BACKGROUND: Incidentaloma management is not without potential harm. Patient and primary care provider anxiety, further testing and radiation exposure are some of the risks that may follow. Family physicians are often the ones to manage incidental findings, and may find management challenging. How can radiology add value to family medicine's care of patients with incidentalomas? This presentation aims to explore primary care incidentaloma management and how radiology can support an optimized experience for primary care providers and patients.

CONCLUSION: Understand family medicine guidelines for incidentaloma management.

Understand how radiology can support a value driven approach to primary care incidentaloma management.

EE020

FLIPPING THE CLASSROOM: AN ALTERNATIVE APPROACH TO RADIOLOGY RESIDENT EDUCATION

Authors: Madeleine Sertic, Laila Alshafai, Luis Guimaraes, Nasir Jaffer, Linda Probyn

LEARNING OBJECTIVES:

1. Revisit traditional teaching rounds.
2. Define the new concept of learning: Flipped Classroom.
3. Learn how Flipped Classroom pedagogy can be applied to formal rounds to increase active learning and improve retention.

BACKGROUND: Historically, radiology resident education relied on passive teaching methods. Traditional rounds involve selected resident taking cases while others observe. Adult learning strategies stress the importance of active learning. "Flipped Classroom" is an active pedagogy, which inverts traditional rounds. Using a thematic approach, cases are distributed prior to rounds, residents submit their findings, and multiple cases are discussed during 1-hour conferences.

CONCLUSION: Flipped Classroom has been discussed in various iterations since the 1970's. However, it has not been widely adopted over the traditional format.

Our experience demonstrates multiple benefits to Flipped Classroom, which correlates with the literature. In traditional rounds, residents taking cases receive the most benefit. In Flipped Classroom, every resident takes every case, eliminating the passive "audience member" effect. More cases can be covered during one conference. Decreased pressure on individual residents results in a more positive learning environment, which correlates with higher rates of information retention. Forcing residents to commit to diagnoses also improves retention. Response submission allows for recognition of gaps in detection and knowledge. Rounds can then be modified to focus on these weaknesses. Afterwards, the presentation (PDF format), which contains additional details, images, and references for each case, can be distributed to residents. Preparation time is not longer than traditional rounds or didactic lectures, and presentations can be re-used with different groups of residents.

EE021

PERSONALIZED IMAGING REPORTS- A NOVEL METHOD OF IMAGE REPORTING

Authors: Jamil Addas, Luís Guimarães, Nasir Jaffer

LEARNING OBJECTIVES:

1. Discuss the different ways used to structure radiology reports.
2. Demonstrate the importance of structured synoptic reporting as a way to improve the quality of delivered reports for clinical use.
3. To present a novel method of structuring personalized imaging reports tailored according to the clinical scenario.
4. To present 5 templates that can be used in daily clinical practice.

BACKGROUND: Radiology reports remain the major means of communicating the professional opinion on imaging studies. The commonly used layouts are traditional prose, and recently introduced itemized synoptic structured reports (SR), the latter improving communication in a clinically oriented manner. The proposed Personalized Imaging Report (PIR) method combines prose and synoptic reporting methods targeted to patient's clinically relevant question and or diagnosis. We will illustrate PIRs in several commonly encountered scenarios.

CONCLUSION: The use of prose report is declining due to inconsistencies, frequent lack of pertinent information and incompleteness. Alternatively, SR was introduced to ensure consistency among Radiologists. Rectal cancer MRI SR is a good example, it improved the quality of the delivered information and the communication among radiologists and clinicians. The proposed PIR method allows for imaging information to be structured with specific details of the targeted organ(s) and its associated findings. The PIR template for right colon cancer, for instance, would have the lesional description and associated lymph nodal groups by their anatomical location, unlike SR, where nodes are described separately. PIR templates ensure consistent and accurate image reports for patient's specific diagnosis in the new environment of personalized medicine.

EE022

RECIPE FOR A SUCCESSFUL HYBRID ACADEMIC-COMMUNITY RADIOLOGY PRACTICE: CANADIAN EXPERIENCE

Authors: Michael N. Patlas, Nataly Farshait, Douglas S. Katz, Ania Kielar

LEARNING OBJECTIVES:

1. To discuss the challenges of running successful hybrid academic-community practice.
2. To highlight the unique advantages of academic subspecialty radiology group in providing quality service for the community.
3. To propose solutions for the successful integration of a joint academic and community practice.

BACKGROUND: Different skill sets are required for the coverage of the academic and community departments. Academic subspecialty trained radiologists may require retraining to cover a wider spectrum of modalities expected from the community imager. Similarly, community-based generalists can struggle to find a proper niche in a tertiary center. Hybrid practice (HP) is challenged to maintain good working relationships with the leadership of the medical school and teaching hospitals, and to strive to avoid the perception of the conflict of interest.

CONCLUSION: This exhibit will reflect on authors' leadership experience in a large academic-community HP. The presentation reviews common challenges in the management of the combined practice and proposes practical solutions.

EE023

CAPITAL EQUIPMENT PROCUREMENT PROCESS AT A QUATERNARY ACADEMIC CENTER: A RESIDENT'S PERSPECTIVE

Authors: Kushal R. Parikh

LEARNING OBJECTIVES:

1. Understand the role of the capital equipment purchasing team at a quaternary care center.
2. Become familiar with the different entities involved in the procurement process.
3. Understand the typical capital equipment procurement process as it pertains to radiology.

BACKGROUND:

- There is little or no education on procuring capital equipment in today's clinical training programs.
- Physicians in private practices are routinely expected to participate in procurement decision-making processes.
- Radiology, in particular, requires a strong understanding of these processes due to the large fixed costs and clinical dependence on acquiring "good" equipment.
- Here we illustrate a typical radiology-related capital equipment procurement process at a quaternary center.

CONCLUSION:

- Capital equipment procurement process is a multi-step, intricate process involving multiple stakeholders and decision-makers.
- Having even a rudimentary knowledge of the process can help the radiologist make more informed decisions.
- A thorough understanding of different types of contracts and purchasing options is essential in creating an efficient, patient-centered practice.

EE024

MEDICAL INTERVENTIONS AND DIABETIC FOOT ULCERS: KNOWLEDGE AND ATTITUDES OF NEWFOUNDLAND AND LABRADOR FAMILY PHYSICIANS

Author: Michelle Anderson

LEARNING OBJECTIVES:

1. Summarize the prevalence of diabetes in Newfoundland and Labrador (NL).
2. Describe various interventions used in the management of diabetic foot ulcers.
3. Identify the current approach of family physicians in NL in the management of diabetic foot ulcers.
4. Assess the self-reported knowledge of these family physicians with respect to the use of endovascular techniques used in the treatment of diabetic foot ulcers.
5. Analyze family physician's preferred method of receiving information to bridge knowledge gaps surrounding endovascular techniques in the treatment of diabetic foot ulcers.

BACKGROUND: The 548 family physicians registered with the Newfoundland and Labrador Medical Association (NLMA) were contacted via e-mail requesting completion of a 10-item survey. This survey was completed by 40 family physicians and obtained information on physician's attributes, their use of diabetic management screening tools and self-reported knowledge of endovascular interventions used in diabetic foot ulcer management.

CONCLUSION:

- Early intervention correlates with positive outcomes for diabetic foot ulcers and reduces the number of foot amputations. Improving health care and reducing the amputation rate begins with addressing gaps in awareness or understanding of foot care management techniques.
- Family physicians in Newfoundland and Labrador do not have a thorough understanding of the use of endovascular interventions in the treatment of diabetic foot ulcers.
- There is a need to develop a communication strategy that can disseminate information to physicians on the success of endovascular interventions in the management of diabetic foot ulcers. Physicians have indicated that a seminar/meeting is their preferred format for receiving this information.

EE025

PRIMER ON DUAL-ENERGY COMPUTED TOMOGRAPHY ON IMAGING THE ACUTE ABDOMEN

Authors: Yuhao Wu, Ismail Ali, Sheldon Clark, Faisal Khosa, Patrick McLaughlin, Omar Metwally, Savvas Nicolaou

LEARNING OBJECTIVES:

1. Summarize the clinical manifestations, pathophysiology, and differential diagnosis of acute abdomen.
2. Review the conventional imaging modalities for assessment of acute abdomen, including conventional radiography, ultrasonography, and computed tomography.
3. Describe the concept of dual-energy computed tomography (DECT).
4. Identify the utility of using DECT and its advantages over using conventional CT, including its ability to generate virtual non-enhanced images and to assess perfusion using iodine maps.
5. Showcase DECT imaging findings in the acute abdomen, including uroliathisis, acute bowel ischemia, and acute pancreatitis.

BACKGROUND: Acute abdomen is a common presentation to the emergency department (ED), accounting for approximately 4-5% of ED visits. Because the clinical manifestations of acute abdomen can be complex, imaging plays an important role in diagnosis and clinical management of these patients. Dual energy computed tomography, which allows for simultaneous image acquisition at two different energy levels, provides more accurate diagnoses with less radiation exposure.

CONCLUSION: Acute abdomen is a common but complex clinical presentation that often requires the use of imaging to establish diagnosis. DECT, with its ability to distinguish two materials of similar radiodensity on conventional CT, has emerged as an image modality that allows for more rapid and accurate diagnosis at lower cost and radiation exposure.

EE026

WHY DO WE STRUGGLE TO DETECT URETERAL INJURIES ON MULTIMODALITY IMAGING?

Authors: Michael N. Patlas, Sanjeev Bhalla, David Dreizin, Douglas S. Katz, Christine O. Menias

LEARNING OBJECTIVES:

1. To illustrate critical imaging findings in blunt and penetrating traumatic and iatrogenic ureteral injuries.
2. To discuss the advantages and disadvantages of different imaging modalities for the diagnosis of ureteral injuries.
3. To review the clinical and imaging literature on ureteral injuries, with an emphasis on potential pitfalls, and missed injuries.

BACKGROUND: Traumatic ureteral injuries are rare and can be easily overlooked by the radiologist due to multiple concomitant injuries. The majority of non-iatrogenic cases are caused by gunshot wounds. Blunt ureteral injuries are very uncommon, but can be encountered in severe multitrauma patients. Iatrogenic injuries can occur during gynecologic, bowel and vascular surgery. The role of MDCT, IVP and retrograde pyelography will be explored and demonstrated. Potential pitfalls in imaging evaluation, including specific features of incomplete ureteral transection, will be highlighted.

CONCLUSION: This exhibit offers an opportunity to review the imaging appearance of traumatic and iatrogenic ureteral injuries and emphasizes the role of radiologist in the detection and management of these life-threatening entities.

EE027

WHAT IS WRONG WITH THE DURA? SPECTRUM OF COMMON AND UNUSUAL DURAL PATHOLOGIES IN THE SPINE

Authors: Carlos H. Torres, Nader Zakhari

LEARNING OBJECTIVES:

1. Review anatomy of spinal meninges.
2. Review the imaging findings of common and unusual dural pathology.
3. Highlight the secondary imaging findings that suggest underlying dural pathology.

BACKGROUND: The spinal dura is an under-recognized primary location of pathology in many disease entities. Some of the dural pathologies are directly visualized on MRI. However, in other instances the secondary effects can be the clue for underlying dural disease e.g intracranial hypotension and superficial siderosis.

CONCLUSION: The purpose of this presentation is to review the imaging findings of common and unusual dural pathology. We also highlight the secondary imaging findings that suggest dural pathology.

TABLE OF CONTENTS

1. Review anatomy of spinal meninges
2. Secondary imaging findings requiring assessment for dural pathology
   a) Intracranial hypotension
   b) Intraspinal fluid collection
   c) Superficial siderosis
   d) Asymmetric spinal cord atrophy and signal abnormality
3 Discussion of multiple dural pathologies through cases:
   a) IgG4-related Hypertrophic Pachymeningitis
   b) Dural tear with intracranial hypotension
   c) Dural tear with intracranial and spinal cord superficial siderosis
   d) Spinal cord herniation
   e) Hirayama disease
   f) Meningioma
   g) Subdural empyema
   h) Other

All the Scientific Exhibits are in digital format and are available for viewing in the foyer of the Salle de bal, 4th floor.
THURSDAY, APRIL 20, 2017 – SUNDAY, APRIL 23, 2017
Prizes for this contest are funded by the Canadian Radiological Foundation (CRF) and will be awarded during the Wine and Cheese Reception and Awards Ceremony on Saturday, April 22, 2017.

Toutes les expositions scientifiques sont en format numérique et peuvent être visionnées dans le foyer de la Salle de bal au 4e étage.
JEUDI LE 20 AVRIL 2017 – DIMANCHE LE 23 AVRIL 2017
Les prix pour ce concours sont financés par la Fondation radiologique canadienne (FRC) et seront remis samedi, le 22 avril, lors de la Soirée vins et fromages et remise des prix.

JUDGES / JUGES : Dr. Emily Pang, Dr. Francesca Proulx, Dr. Vivek Virmani

SE001

A MACHINE LEARNING MODEL BASED ON THE NATIONAL LUNG CANCER SCREENING TRIAL TO AID IMAGE QUALITY ANALYSIS: A FEASIBILITY STUDY

Authors: Andrew D. Brown, Djeven P. Deva

OBJECTIVE: The presence of imaging artifacts is one criterion used in the American College of Radiology (ACR) CT accreditation program to evaluate the quality of medical imaging facilities. This study evaluated the performance of a novel computer model for motion artifact assessment in CT chest examinations. It performed well when compared to the image quality assessments of expert readers in the National Lung Screening Trial (NLST).

METHODS: We used the image quality assessments recorded by radiologists during NLST as our reference standard to determine the presence of motion artifacts. We then used sharpness estimation techniques to analyze each image in both no-motion and motion-degraded CT examinations. Each examination was represented by a distribution of sharpness scores. We then used the summary statistics of these distributions as inputs to train our model to assess the presence of motion artifacts.

RESULTS / DISCUSSION: Our model outperformed the baseline model on every measure of model performance for predicting motion degradation. The baseline model achieved an accuracy of 65% while the accuracy of our model was 94%. The use of this type of approach has the potential to improve the CT accreditation process by allowing for the analysis of more images, while improving the speed, reliability and cost of the accreditation process. Our model paves the way for novel quality metrics capable of providing more representative measures of a provider's image quality.

CONCLUSION: Our model was able to effectively discriminate between motion-degraded and non-motion degraded low-dose CT chest examinations with a high degree of accuracy, outperforming the baseline model.

SE002

PREDICTIVE VALUE OF SELECTIVE ULTRASOUND SCREENING FOR DEVELOPMENTAL DYSPLASIA OF THE HIP PERFORMED AT A SINGLE INSTITUTION

Authors: Tracee Wee, Heather Bray, Kishore Mulpuri, Jim Potts, Emily Schaeffer

OBJECTIVE: Hip Ultrasound (US) is recommended as a screening examination in infants with identified risk factors for Developmental Dysplasia of the Hip (DDH). The purpose of this study was to evaluate the predictive value of screening US for DDH requiring treatment in infants with risk factors and to evaluate efficacy of individual components of the screening exam.

METHODS: We reviewed hip US studies of all infants with DDH risk factors performed at our institution between January 2013 and June 2014. Patients with positive physical findings of DDH were excluded. Alpha angle and femoral head coverage were measured on static coronal images. Hip stability was assessed with dynamic transverse imaging. Clinical data to September 2016 were reviewed for all screened infants referred to our institution's orthopaedic clinic.

RESULTS / DISCUSSION: 631 patients were screened at a median age of 55 days; 62% were female. Although 7% of patients had abnormal hip US, only 5% (29 patients) required immobilization and <1% (3 patients) had surgical treatment for DDH (Table 1). No patient with normal static images and hip instability elicited on dynamic imaging required treatment. US had 88% sensitivity and 96% specificity for DDH requiring treatment and positive and negative predictive values of 53% and 99%, respectively.

CONCLUSION: US is an effective screening tool with high negative predictive value for DDH in infants with risk factors. Our cohort shows an incidence of DDH similar to other reported cohorts. Dynamic instability in otherwise normal hips is not a predictor of treatment and can be excluded from the examination.

SE003

CREATION OF ANATOMICALLY COHERENT VASCULAR ANGIOGRAPHIC PHANTOMS USING CT ANGIOGRAMS, 3D COMPUTER MODELING, AND 3D PRINTING

Authors: Killian Newman, Alexandre Menard, Rahul Sarkar

OBJECTIVE: Use 3D modeling and printing technology to produce patient-specific vascular phantoms with accurate anatomy and pathology. These models can be used for training purposes or testing patient-specific interventions.

METHODS: 3D vascular data from a carotid CT-angiogram was exported to a Vitrea 3D station to produce a STL file of the vessels of interest. STL files were imported into Autodesk 123D Design and functioned as a scaffold to construct a 123D vessel model replica. The 123D model was fitted with drainage vessels and subtracted from a containing cylinder. Models were printed with polylactic acid filament using an Ultimaker 2 3D printer. Hose connectors, tubing and a pump were attached to produce physiologic flow. Selective digital subtraction angiograms were performed using standard cerebral angiographic techniques.

RESULTS / DISCUSSION: Phantom development progressed from rudimentary constructions to complex patient-specific models with pathology. A Circle of Willis model spanning from the aortic arch to the branches of the cerebral arteries successfully completed DSA simulation. Attenuation due to the plastic was negligible and vessels were clearly delineated. Anatomical configuration and tactile feedback sensed by the interventionist were similar to clinical practice. Production of phantoms with variant anatomy or pathology was facilitated by computer modeling.

CONCLUSION: A workflow pipeline using a standard post-processing workstation and freely available design software can create accurate, adjustable patient-specific vascular phantoms.

SE004

IDENTIFYING THE CHALLENGES WITH RADIOLOGY ELECTIVES: STUDENT AND FACULTY EXPERIENCES AT A LARGE DISTRIBUTED MEDICAL SCHOOL

Authors: Rebecca Spouge, Sheldon Clark, Kathryn Darras, Bruce B. Forster, Savvas Nicolaou, Kathryn Scurfield

OBJECTIVE: To determine the attitudes of medical students and radiology faculty towards the Year 4 radiology electives at a large distributed medical school and to identify areas for improvement.

METHODS: Both students and faculty who participated in an elective during the 2015-2016 academic year were surveyed anonymously using the online One45 survey tool. Data was analyzed both qualitatively and quantitatively. Following this, a focus group of students, residents and faculty convened to develop solutions to improve the elective experience.

RESULTS / DISCUSSION: The response rate was 82% for students (95/116) and 20% (32/159) for faculty. 90% (82/91) of students and 75% (24/32) of faculty rated their overall elective experience as 'good', 'very good', or 'excellent'. Students identified the main weaknesses were a lack of autonomy and formal teaching. Faculty identified the main weakness was a lack of standardized objectives. Only 52% of faculty reported a clear understanding of what to expect of a Year 4 student and only 52% of faculty reported adequate access to the resources needed to plan and teach the elective effectively. The focus group proposed low cost, practical solutions for improving these weaknesses.

CONCLUSION: Although participants were overall satisfied with radiology elective experience, this study highlights the challenges of developing and administrating radiology electives. The practical tips provided to improve student and faculty engagement in electives will be of interest to all educators. It is important for electives to provide students with a rich and engaging experience in order to attract excellent candidates to our specialty.

SE005

ANATOMY AS A CORE COMPETENCY: A PRELIMINARY STUDY ON THE EDUCATIONAL VALUE OF A PGY-1 ANATOMY COMPETENCY-BASED ROTATION

Authors: Rebecca Spouge, Silvia Chang, Kathryn Darras, Bruce B. Forster, Cameron Hague, Colin Mar

OBJECTIVE: As undergraduate medical programs reduce the hours of anatomy teaching, residents interested in anatomy-intensive residency programs, like radiology, must independently acquire the anatomy knowledge they need to achieve competency as early as possible in their training. The purpose of this educational initiative was to establish anatomy objectives for junior residents and to introduce a 4-week competency-base self-directed anatomy rotation for junior residents.

METHODS: 7 PGY-1 radiology residents completed a 4-week radiological anatomy rotation which consisted of competency-based self directed modules. The course objectives were developed from standards, senior residents and expert opinion. Similar pre-course and post-course tests were administered to residents and test scores were compared using an unpaired t test. In addition, PGY-1 residents completed a post-course survey regarding their anatomy knowledge and exposure to radiological anatomy prior to the course.

RESULTS / DISCUSSION: Out of the 25 points available, the average pre-test score was 10.79 ± 2.78 (range 8-16.5) and the average post-test score was 21.64 ± 2.23 (range 18.5-25). This difference was statistically significant ($p < 0.0001$). On average, the PGY-1 residents reported receiving < 10% of dedicated radiological anatomy teaching in medical school and felt unprepared for the anatomy required in residency. Overall, residents reported increased confidence in looking at images after completing the radiological anatomy course.

CONCLUSION: This study demonstrates the need for dedicated radiology training for radiology residents beyond what is offered in medical school. In addition, this study reveals how it is possible to create a simple self-directed course for radiology residents that significantly improves their anatomy knowledge.

SE006

UTILIZATION OF PRE-OPERATIVE IMAGING FOR COLON CANCER: A POPULATION-BASED STUDY

Authors: Matthew D. McInnes, Christopher M. Booth, Jennifer A. Flemming, David B. Macdonald, William J. Mackillop, Sulaiman Nanji, Nicola Schieda

OBJECTIVE: To assess the use of pre-operative imaging for colon cancer and to identify factors associated with utilization in routine clinical practice.

METHODS: This population-based, retrospective cohort study used a random sample of 25% of colon cancer patients treated with surgery in the province of Ontario (2002-2008). Pre-operative imaging (<16 weeks from surgery) of the chest, abdomen-pelvis was identified. Modified poisson regression was used to analyze factors associated with practice patterns.

RESULTS / DISCUSSION: Of the 7,249 included patients, 48% had pre-operative imaging (CT abdomen and imaging of the chest) in keeping with guideline recommendations. The rate of guideline concordant pre-operative imaging increased over time: 64% in the most recent study period (2006-2008) vs. 31% (2002-2004); $p<0.001$.

Variables associated with use of chest imaging: age, co-morbidity, surgeon volume and geographic region; no association with gender, hospital volume or socioeconomic status. Variables associated with use of abdomen imaging: hospital volume and geographic region; no association with age, gender, comorbidity, socioeconomic status, or surgeon volume.

CONCLUSION: In clinical practice, the majority of patients were not receiving pre-operative imaging that was in line with clinical practice guidelines; however, use increased over time indicating a possible association with dissemination of clinical practice guidelines.

SE007

A DAY IN MR: EXAM VARIATION AND APPROPRIATENESS OF MRI EXAMS IN CANADA

Authors: Andreea Badea, Paul Babyn, Neil Kalra, Juan-Nicolas Pena-Sanchez, Sonia Vanderby

OBJECTIVE: This study aimed to determine the volumes and types of magnetic resonance imaging exams being performed across Canada, common indications for the exams, and exam appropriateness using multiple evaluation tools.

METHODS: 13 academic medical institutions across Canada participated. Data, including patient demographics, exam priority, type by anatomic region and indication for imaging, were obtained relating to a single common day, October 1, 2015. Each exam was assessed for appropriateness via the Canadian Association of Radiology Referral Guidelines and the American College of Radiology Appropriateness Criteria. The Alberta and Saskatchewan spine screening forms and the Alberta knee screening form were used where applicable. The proportion of exams that were unscorable (due to illegibility or lack of applicable guidelines), appropriate and inappropriate was determined.

RESULTS / DISCUSSION: Data were obtained for 1087 relevant exams. 54% of patients were female; 3% of requisitions did not indicate the patient's sex. Brain exams were the most common, comprising 32.5% of the sample. Cancer was the most common indication. Most exams were given priority levels 2 or 3; 10.2% of the exams were Priority 1. Overall, 87.0% to 87.4% of the scoreable MR exams were appropriate; 6.6% to 12.6% were inappropriate, based on the two main evaluation tools. Results differed by anatomic region; spine exams had the highest proportion with nearly one-third of exams deemed inappropriate. Unscoreable exams differed by evaluation tool, ranging from 23% to 27%.

CONCLUSION: Variations by anatomic region indicate that focused exam request evaluation or screening methods could substantially reduce inappropriate imaging.

SE008

THE MRI FLIPPED CLASSROOM: TWO-YEAR EXPERIENCE AT A UNIVERSITY RADIOLOGY RESIDENCY PROGRAM

Authors: Khashayar Rafatzand, Caroline Reinhold, Max Rosen

OBJECTIVE:

- To demonstrate feasibility and effectiveness of flipped classroom model in radiology residency core curriculum.
- To guide development of similar curricula in other institutions.

METHODS: At our ACGME accredited university radiology residency program, there was a perceived need for dedicated MRI teaching given its increasing incorporation into ABR certification examination. Program director and department chair approved the course.

Course proctor was a body MRI radiologist with 2 years of MRI physics teaching experience. Two curricula were formed using online lectures from ISMRM annual meetings: MRI physics & Body MRI. ISMRM membership was purchased for residents (N=28), respecting copyright. After reviewing the content ahead of time, residents explained content & concepts of individual slides, answering proctor's questions, taking turns. The proctor confirmed, corrected or elaborated on residents' explanations. Sessions ended after Q&A period. Individual session and overall course evaluations were collected.

RESULTS / DISCUSSION: Recurring annually (2014-2015), 12 physics and 8 clinical sessions (25 hours) were held, teleconferenced to a second site. Proctor preparation time was 80 & 18 hours in 2014 and 2015. Sessions were >75% interactive.

23/28 (89.2%) reported:

- positive 2-year overall self-assessment of learning (Chart1)
- achievement of course objective: improved MRI education.

CONCLUSION: Flipped classroom delivers expert-generated content on challenging subjects of MRI physics & Body MRI with high audience interactivity and favourable subjective learning outcomes.

Authors advocate for and discuss implications of more widespread incorporation of flipped classroom in radiology residency programs.

This curriculum was later adopted by another university based program, and can be shared with interested institutions.

SE009

NON-CONTRAST MDCT FOR URETERAL CALCULI AND ALTERNATIVE DIAGNOSES: YIELD IN ADULT WOMEN VERSUS IN ADULT MEN

Authors: Michael N. Patlas, Parisa Fani, Douglas S. Katz

OBJECTIVE: To determine the yield of non-contrast CT (NCCT) for the diagnosis of ureteral calculi and alternative diagnoses in men versus women presenting with suspected renal colic (RC) to the ED of a teaching hospital.

METHODS: IRB-approved retrospective review of NCCT performed on adult patients presenting to ED with acute flank pain. Patients with known obstructive ureteral calculi, or with known UTI, malignancy, or trauma, were excluded. We compared the prevalence of ureteral calculi and alternative diagnoses between the men and the women, based on review of the images. P values and Confidence Intervals (CI) were determined using the chi-square test.

RESULTS / DISCUSSION: One attending radiologist and one radiology resident randomly selected (using a number generator) and reviewed 400 scans from a total of 1097 NCCT examinations performed from 10/1/2011 to 10/30/2013. The mean patient age was 55.2 years. This included 170 women (mean age 56.8 years), and 230 men (mean age 54.2 years). Ureteral calculi were observed in 42.5% of all patients, including in 111 men (48%) and 59 women (34.7%). The prevalence of ureteral calculi in men was significantly higher than in women ($p<0.01$, Confidence Level of 95%, and CI of 13.3). Alternative diagnoses were demonstrated on NCCT in 12.5% of patients, including 23 in men (5.7%) and 27 in women (6.7%). There was no statistically significant difference in the prevalence of alternative diagnoses between men and women ($p>0.2$).

CONCLUSION: The likelihood of a ureteral calculus being present on NCCT performed for suspected RC was significantly higher in men compared with in women.

SE010

HALLMARK OF SUCCESS: TOP 50 CLASSICS IN ORAL AND MAXILLOFACIAL COMPUTED TOMOGRAPHY

Authors: Yuhao Wu, Bo Gong, Faisal Khosa, Haaris Tiwana, Sabeen Tiwana

OBJECTIVE: To identify the top 50-cited articles on the use of computed tomography (CT) for oral and maxillofacial applications. This knowledge will help the academic community identify trends of most impactful research and allocate healthcare research funding appropriately.

METHODS: A database was generated by combining the search results from Thomson Reuters Web of Science and Elsevier's Scopus to ensure that all top-cited publications were included. To generate the database of top cited articles, we used three search fields: computed tomography, oral and maxillofacial pathology, and oral and maxillofacial anatomical structures. Publications were then ranked by citation counts and reviewed by two independent reviewers.

RESULTS / DISCUSSION: A total of 50 top publications were included in the study with their citation counts ranging from 43 to 170 with a median of 55.5. Five publications were cited more than 100 times. All except for one paper was published after 2000. The most well published journal is the *American Journal of Orthodontics and Dentofacial Orthopedics* (n=12). Majority of the studies (n=27) imaged teeth pathologies, but there are also significant amount of articles that discussed imaging of bone grafts or dental implants (n=7), upper airways (n= 5), skull (n=4), and other maxillofacial structures (n=7).

CONCLUSION: Our study summarizes the characteristics of top 50 publications in the field of oral and maxillofacial computed tomography. It can provide valuable information for journal editors in selecting and evaluating scientific studies for publications and for academic dentists to gain valuable insight regarding the trends that are steering the field of oral and maxillofacial CT.

SE011

NOVEL CT PREDICTORS OF TYPE A AORTIC DISSECTION

Authors: Michael N. Patlas, Ali Alsagheir, Forough Farrokhyar, Nigel Munce, Dominic Parry

OBJECTIVE: To retrospectively evaluate the clinical relevance of novel MDCT parameters in patients with type A aortic dissection (TAAD) when compared to a control group having MDCT for the evaluation of thoracic aorta.

METHODS: An IRB-approved retrospective review of patients presenting with TAAD was conducted from 1/1/2008 to 1/1/2016. MDCT parameters measured were: length of the ascending aorta(AA), maximal AA diameter, aortic root diameter, the left ventricular outflow tract(LVOT) angle and the cardiac apex(CA) angle(the angle between an imaginary line drawn from left ventricular apex to the mid point of the aortic valve and a second line representing the transverse plane). Similar measurements were performed in an age and gender matched control group. Statistical comparison were made with Student's t-tests.

RESULTS / DISCUSSION: 51 cases of TAAD (mean age= 61; M:F= 35:16). Control group: 76 cases without significant acute aortic pathology or prior thoracic aortic intervention. The mean length of the ascending aorta in the TAAD population versus control group was 12.00 vs 9.27 cm ($p < .0001$). The maximal aortic diameter was 4.97 vs 3.15 cm($p < .0001$); and aortic root diameter was 4.35 vs 2.89 cm ($p<.001$).The LVOT and CA angles were both significantly less in the type A dissection group measuring 31.70 vs 44.13 degrees($p< .0001$) and 20.44 vs 30.34 degrees($p <.0001$), respectively.

CONCLUSION: There is a statistically significant increase in the length of the ascending aorta in patients with TAAD as compared to control group. We also demonstrate that there is a decrease in the angle of the LVOT and CA angle.

SE012

ACCURACY OF STANDARDIZED CINE CLIPS IN THE SONOGRAPHIC ASSESSMENT OF THE SUPRASPINATUS TENDON

Authors: Marcos L. Sampaio, Fabricio Cyrineu, Zaid Jibri

OBJECTIVE: Determine the accuracy of standardized cine clips for the diagnosis of supraspinatus tendon pathologies, having as reference standard the usual shoulder ultrasound protocol that includes static images and non-standardized cine clips.

METHODS: Ethical board approval was obtained for this prospective study. 140 consecutive patients had diagnostic shoulder ultrasounds. Documentation included static images, non-standardized cine clips and additional standardized cine clips of the supraspinatus tendon. The standardized cine clips of the supraspinatus tendon were reviewed by a radiologist blinded to clinical information and ultrasound report. Calcific tendinopathy, moderate or severe tendinopathy, partial-thickness tears, full-thickness tears and complete tears were assesed. Incomplete and non-diagnostic studies were excluded. Sensitivity, specificity, accuracy, positive and negative predictive values were calculated having final reports as reference standard. A second musculoskeletal radiologist reviewed independently 51 cine clips for assessment of inter-observer agreement.

RESULTS / DISCUSSION: 114 patients (ages 21-93, mean 57, 56 females) were left after application of exclusion criteria. Table 1 demonstrates the results. Inter-observer agreement (Kappa score) was respectively 0.42; 0.47; 0.21; 0.95 and 0.56 for calcific tendinopathy, tendinopathy, partial thickness tear, full thickness tear and complete tear.

CONCLUSION: Standarized cine clips are a reliable tool for the evaluation of patients with high pre-test probability of full-thickness or complete supraspinatus tear.

SE014

ULTRASOUND IN THE DIAGNOSIS OF CARPAL TUNNEL SYNDROME: A PRACTICAL APPROACH

Authors: Amar Suchak, Kent Hecker, Jon Lee, Alan Lin

OBJECTIVE: The many studies in the literature that use utrasound to diagnose carpal tunnel syndrome (CTS) result in a myriad of protocols and values that make application into the clinical setting difficult. This study investigates a practical sonographic technique to determine if its results can diagnose CTS in the clinic setting.

METHODS: Thirty-six patient wrists with a history, physical examination, nerve conduction study and confirmatory post-operative diagnosis of CTS underwent ultrasound of the median nerve size prior to surgical intervention. The pisiform (PS) and pronator quadratus (PQ) landmarks, and their difference value (MNΔ), were recorded. Secondary measurements, such as nerve motion with finger motion, hyperemia, and a sonographic positive Tinel's sign, were obtained. The reliability of the clinical sonologist's technique and forty-six control subjects were additionally investigated.

RESULTS / DISCUSSION: The average PS, PQ and MNΔ values in patients were each statistically significantly different than control subjects. However, the MNΔ value alone could not routinely differentiate patients from controls. A sensitivity of 94% for PS values $\leq 9mm^2$ and a specificity of 100% for PS values of $\geq 10mm^2$ for CTS were identified; an intermediate PS range of $9\text{-}10mm^2$ could not be resolved with any of the other variables investigated.

CONCLUSION: Clinical sonologists can reliably assess the carpal tunnel with this practical approach; however, the variability in MNΔ in both patients and controls means this solitary value cannot differentiate disease from normalcy. Based on the results of this study, an algorithm is proposed to improve the accuracy of the diagnosis of CTS.

SE015

DETERMINANTS OF 'TRUTH' IN IMAGING RESEARCH: THE QUEST FOR THE HOLY GRAIL?

Authors: Robert Frank, Patrick Bossuyt, Julie Jesurum, Herbert Kressel, Deborah Levine, Trevor McGrath, Matthew McInnes, William Petrcich

OBJECTIVE: The variables associated with 'truth' (minimal bias) in imaging research are poorly understood. While absolute truth is elusive, pooled summary estimates from quality meta-analyses represent a convenient proxy. Our objective is to determine if journal- and study-level variables are associated with the proximity of primary study results to summary estimates from meta-analyses (i.e., 'truth').

METHODS: Medline was searched for diagnostic accuracy meta-analyses published in imaging journals between January 2005 and April 2016. Data were extracted for each meta-analysis and its included primary studies (study demographics, impact factor, STARD endorsement, sample size, citation rate, publication timing, sensitivity and specificity). For each variable assessed, primary studies were divided into 2 groups and the mean of differences ('delta, Δ') between their diagnostic accuracy results (sensitivity or specificity) and the corresponding pooled estimates from their meta-analyses were calculated for each group. The resultant mean delta values were compared between groups, using a mixed statistical model, to determine whether any variables were associated with proximity of a primary study result to the pooled summary estimate ('truth') from its respective meta-analysis.

RESULTS / DISCUSSION: Ninety-eight (98) meta-analyses containing 1458 primary studies met inclusion criteria. Although several variables demonstrated significant associations with proximity of primary study estimates to meta-analysis pooled estimates for either sensitivity or specificity, no variable was associated with both (Table 1).

CONCLUSION: Many of the variables considered important by readers in selecting diagnostic accuracy literature to guide clinical decision-making are not necessarily associated with results that are more reflective of the truth.

SE016

RETROPERITONEAL FASCIITIS: 16-YEAR RETROSPECTIVE CASE REVIEW

Authors: David C. Wang, Phyllis Glanc, Pawel Stefanski

OBJECTIVE: To determine the clinical features, imaging presentation, and outcomes of patients with retroperitoneal fasciitis (RPF) over a 16-year period.

METHODS: A single-centre 16-year retrospective review of patients with pathology-proven RPF was performed. Medical and surgical records, pathology, and imaging databases were used in data collection. Thirty-four possible cases were obtained from the computed search and 12 cases of pathology-proven RPF were included for analysis.

RESULTS / DISCUSSION: The average age was 52.3 years (range: 23 to 74). Causative factors of RPF included Fournier's gangrene, trauma, superficial necrotizing fasciitis, septic arthritis, spondylodiscitis, colonic perforation, and post-surgical complication. Necrotizing RPF was present in 83% (10/12) of patients. The most common computed tomography (CT) findings were asymmetrical fascial thickening and fat stranding. Tracking fascial gas was observed in 33% (4/12) patients, with necrotizing infection being documented in all of these patients. Microbiology revealed polymicrobial infection in 50% (6/12) patients. Surgical debridement was undertaken in 75% (9/12) patients with a mean delay from presentation to surgery of 1.6 days. The overall survival rate was 67% (8/12) and 78% (7/9) in the surgery group.

CONCLUSION: Clinical diagnosis of RPF is a challenge given the non-specific signs and symptoms and rapid progression of disease. Familiarity with the CT signs of RPF and a high index of suspicion may be life-saving in these rare and potentially life-threatening cases. Aggressive surgical intervention, including multiple planned debridements in combination with medical therapy, is vital for improving disease survival.

SE017

TRENDS IN GOUT IMAGING: A BIBLIOMETRIC ANALYSIS

Authors: Bo Gong, Kathryn E. Darras, Faisal Khosa, Mohammed F. Mohammed, Savvas Nicolaou

OBJECTIVE: Imaging plays an important role in the diagnosis and management of gout. Our study aims to reveal trends of gout imaging by a bibliometric analysis of research literature on imaging modalities, including conventional radiography (CR), ultrasound (US), computed tomography (CT), magnetic resonance imaging (MRI), and dual energy CT (DECT).

METHODS: Web of Science All Databases were searched without year or language restriction using a phrase combining variants of both "gout" and imaging modalities. Original research articles studying imaging in the diagnosis and management of gout were selected for analysis.

RESULTS / DISCUSSION: A total of 155 articles were identified. The first original research article on CR was published in 1968, US in 1982, CT in 1994, MRI in 1994, and DECT in 2009, with a recent rapid increase of US and DECT articles. A list of top-40 highly cited articles (ranked by average yearly citation) was also generated. In both lists, the three most studied modalities were US, DECT, and CR. The journal *Annals of the Rheumatic Diseases* published the majority of top-40 articles (12 articles), followed by *Rheumatology* (5 articles), and *Clinical and Experimental Rheumatology* (4 articles). Eight major research clusters were identified by author analysis, with the first being at Vancouver General Hospital focusing on DECT. The countries producing the most top-40 articles were New Zealand and the USA (each 8 articles).

CONCLUSION: Our results offer important insights into the role of imaging in the diagnosis and management of gout, and could help guide future research in this important field.

SE018

ANTERIOR SURGICAL FIXATION FOR CERVICAL SPINE FLEXION-DISTRACTION INJURIES

Authors: Mitchell P. Wilson, Godwin Choy, Richard Fox, Andrew S. Jack, Andrew Nataraj

OBJECTIVE: Optimal surgical management for flexion-distraction cervical spine injuries remains controversial with current guidelines recommending anterior, posterior, and circumferential approaches. Here, we determined the incidence of and examined risk factors for clinical and radiographic failure in patients with one segment cervical distraction injuries having undergone anterior surgical fixation.

METHODS: A retrospective review of 57 consecutive patients undergoing anterior fixation for subaxial flexion-distraction cervical injuries between 2008-2012 at our institution was performed. The primary outcome was the number of patients requiring additional surgical stabilization and/or radiographic failure. Data collected inlcuded age, gender, mechanism and level of injury, facet pattern injury, and vertebral endplate fracture.

RESULTS / DISCUSSION: A total of six patients failed clinically and/or radiographically (11%). Four patients (7%) required additional posterior fixation. Although two other patients identified met radiographic failure criteria, at follow-up they had fused radiographically, were stable clinically, and no further treatment was pursued. Progressive kyphosis and translation were found to be significantly correlated with need for revision ($p<0.05$ and $p=0.02$, respectively). No differences were identified for all other clinical and radiological factors assessed, including unilateral or bilateral facet injury, facet fracture, and endplate fracture.

CONCLUSION: This study supports anterior fixation alone for flexion-distraction injuries. Findings suggest that current measurements of radiographic failure including segmental translation and kyphosis may predict radiographic failure and need for further surgical stabilization in some patients, and should be commented on in radiology reports. Future follow-up studies assessing for independent risk factors for anterior approach failure with a validated predictive scoring model should be considered.

SE019

UTILIZATION TRENDS OF DUAL ENERGY / SPECTRAL CT, A NOVEL IMAGING TECHNIQUE FOR DIAGNOSIS AND MANAGEMENT OF GOUT: EXPERIENCE AT VANCOUVER GENERAL HOSPITAL 2007–2016

Authors: Bo Gong, Faisal Khosa, Savvas Nicolaou

OBJECTIVE: Dual energy / spectral CT (DECT) is a novel imaging tool in the diagnosis and management of gout, by aiding in detection of urate deposition, monitoring urate lowering therapy, and differentiation from other crystal or inflammatory arthritides. The Radiology Department at the Vancouver General Hospital started to offer DECT gout scans since July 2007. Our study aims to analyze the utilization trends of DECT for gout.

METHODS: This retrospective study received institutional ethics board approval. DECT gout scans between July 2007 and December 2016 were identified. The website of College of Physicians and Surgeons of British Columbia was used to determine referring physicians' specialty and location.

RESULTS / DISCUSSION: The number of DECT gout scans increased more than fivefold in the past decade (2007 partial year: 37; 2008: 72; 2016: 389; total: 1890). Requests were received from many specialties, with the most requests from Rheumatology (1171 scans, 62%), Emergency Medicine (285 scans, 15%), and Family Medicine (177 scans, 9%). Family Medicine had the largest number of referring physicians (29%), followed by Medical Specialties (excluding Rheumatology) (23%), Emergency Medicine (17%), and Rheumatology (15%). Emergency Medicine and Family Medicine saw the fastest recent increase in referring physicians. Two percent of DECT scans (39) were referred by physicians located outside the Greater Vancouver Area, as far as from Nelson, BC, 650 km from Vancouver.

CONCLUSION: Our results showed a rapid increase in the utilization of DECT gout imaging, and a steady expansion of the referral base, indicating a trend towards the clinical value of this novel diagnostic tool.

SE020

TOP 50 LANDMARKS IN SENTINEL LYMPH NODE IMAGING: A BIBLIOMETRIC ANALYSIS

Authors: Yuhao Wu, Bo Gong, Mohammad Khan, Faisal Khosa, Mohammed Mohammed

OBJECTIVE: Bibliometric analysis can be utilized to identify the most influential literature and track the trajectory of the research development in a given area. The purpose of this study is to summarize the top 50 most-cited landmarks and to examine the recent advances in the field of sentinel lymph node imaging.

METHODS: Web of Science (WOS) was searched to create a database of all English language scientific journals. This search was then cross-referenced with a similar search term query of Scopus® to identify articles that may have been missed on the initial search. Articles were ranked by citation counts and screened by two independent reviewers.

RESULTS / DISCUSSION: Citations for the top 50 papers ranged from 2725 to 163 with a median of 240. 10 papers were cited more than 500 times. The articles were published between 1993 – 2009 across 23 journals. Most of the conventional sentinel lymph node methods was performed under the guidance of radioactive dye (ie technetium 99m sulfur colloid), methylene blue dye, or fluorescence methods. However, two recent advancements in the field are: 1) fusion imaging, which combines molecular and anatomical information, using single-photon emission computed tomography and computed tomography, known as SPECT/CT, and 2) Near-infrared fluorescence.

CONCLUSION: Our study identifies SLNI as a rapidly expanding field with increasing clinical importance for the role it plays in cancer diagnosis and staging. This provides researchers with insight into common factors of success and may enable us to predict for future trends of research in this area.

DEPARTMENTAL CLINICAL AUDIT PROJECTS CONTEST | CONCOURS DES PROJETS DE VÉRIFICATION CLINIQUE AU SEIN DES SERVICES

FRIDAY, APRIL 21, 2017
Departmental Clinical Audit Projects Contest – Oral Presentations – Salon Jarry / Joyce (Level A)
Prizes for this contest are funded by the Canadian Radiological Foundation (CRF) and will be awarded during the Wine and Cheese Reception and Awards Ceremony on Saturday, April 22, 2017.

VENDREDI LE 21 AVRIL 2017
Concours des projets de vérification clinique au sein des services – Présentations orales – Salon Jarry / Joyce (Niveau A)
Les prix pour ce concours sont financés par la Fondation radiologique canadienne (FRC) et seront remis samedi, le 22 avril, lors de la Soirée vins et fromages et remise des prix.

JUDGES / JUGES : Dr. Sukhvinder Dhillon, Dr. Najla Fasih, Dr. Reza Forghani

MODERATOR / MODÉRATEUR : Dr. Bruno Morin

09:00 – AP001

PRE-MRI PATIENT QUESTIONNAIRE: CLINICAL AUDIT

Authors: Navdeep Sahota, Haron Obaid

PRINCIPAL LOCATION OF AUDIT: University-based practice.

BACKGROUND AND AIM: MRI requisition forms from physicians provide variable clinical information. At our institution, pre-MRI patient questionnaires are used for routine joint MSK MRI exams as a substitute. These questionnaires provide clinical information that help in the interpretation of the MRI exam. However, they are inconsistently completed and/or scanned into PACS with the patient's images. Our aim is to assess the compliance of the pre-MRI patient questionnaires.

AUDIT TARGET: The questionnaire should be completed and scanned into PACS for 99% of cases.

METHODS: The resident retrospectively reviewed the questionnaires for all routine joint MRI exams over a consecutive three month period (arthograms were included). Exams with non-routine MRI protocols were excluded.

RESULTS: On the first audit cycle, the questionnaire was included in 93% of exams (400/430). When the questionnaire was present, the front page was included in 100% of exams (400/400) and completed in 99% of exams (396/400), but the back page was only included in 90% of exams (359/400) and completed in 73% of exams where it was included (263/359). The target was not achieved.

INTERVENTIONS / ACTION PLAN: Results were disseminated in the department and discussed at a provincially broadcast PQI presentation. Input was obtained from relevant stakeholders, including MSK radiologists, MRI technicians and MRI front staff. A new questionnaire was implemented.

DISCUSSION / CONCLUSIONS: A second audit cycle completed shortly afterwards showed significant improvement. A third audit cycle performed a full year later showed further incremental improvement.

09:10 – AP002

QUALITY INITIATIVE PROJECT ASSESSING THE IMPACT OF TIRADS ON NET NUMBER OF THYROID BIOPSIES AND ADHERENCE OF TIRADS-REPORTING BY RADIOLOGISTS

Authors: Tetyana Maniuk, Ania Kielar

PRINCIPAL LOCATION OF AUDIT: University-based hospital.

BACKGROUND AND AIM: Incidence of thyroid nodules is high but only 5-15% are malignant. Fine-needle aspiration (FNA) is done for suspicious nodules; however, determining which nodules require FNA is challenging.

The aim of this quality assurance project was to implement a standardized thyroid imaging system (a modified version of TIRADS = Thyroid image reporting and data system). We hypothesize that consistent application of evidence-based guidelines to stratify risk of malignancy in thyroid nodules may reduce the number of FNA's.

AUDIT TARGET: 100% adherence to TIRADS. A significant reduction in the number of thyroid FNA's.

METHODS: Radiologists were encouraged to use TIRADS template reporting in early 2016 during divisional meetings, grand rounds and intra-hospital conferences. A short audit was performed 3 months after starting TIRADS and feedback provided to each radiologist about adherence and discrepant interpretations. Their reports were reviewed before and after this intervention. An educational atlas was created and distributed for educational purposes.

RESULTS: Radiologists adhered to TIRADS reporting within a few weeks of intervention (11% adherence in January 2016 versus 72% in April 2016). Feedback from the mini-audit regarding accuracy of classification was well received. Feedback from clinicians and surgeons at Community of Practice meetings was excellent.

INTERVENTIONS / ACTION PLAN: Information about 1063 thyroid biopsies was collected from January – August 2015 (prior to use of TIRADS reporting) and January – August 2016 (after implementation).

DISCUSSION / CONCLUSIONS: After implementation of TIRADS, the average number of biopsies per month significantly reduced to 60 in 2016, from 74 in 2015. In August 2016, adherence to TIRADS was at 86%.

09:20 – AP003

PULMONARY COMPUTED TOMOGRAPHY ANGIOGRAPHY IN THE DIAGNOSIS OF ACUTE PULMONARY EMBOLISM: AN ASSESSMENT OF PREVALENCE AND USE

Authors: Zhongyi Chen, Irina Boldeanu, Jean Chalaoui, Carl Chartrand-Lefebvre, Simon Deblois, Marie-Odile Francoeur, Luigi Lepanto, Éric Thérasse, Kevin Toporowicz

PRINCIPAL LOCATION OF AUDIT: University hospital center.

BACKGROUND AND AIM: Pulmonary embolism (PE) is a frequent and potentially lethal disease. Its diagnosis is often difficult and involves the use of clinical and paraclinical data and medical imagery. Pulmonary CT angiography (PCTA) is the most commonly used imaging method used. Its prevalence is increasing, but without significant improvement in mortality rate associated with PE, suggesting overuse. The main objective is to evaluate the positive yield rate of PCTA at the CHUM.

AUDIT TARGET: No current consensus on target positive yield rate of PCTA

METHODS: Data were retrospectively gathered from the CHUM's electronic medical records system. All patients having undergone D-dimer testing, ventilation-perfusion scintigraphy or PCTA between January 1st and January 31st 2015 were included.

RESULTS: A total of 1331 PCTAs were requested (mean age 60.2 ± 16.6 yrs, 575 [43.2%] males, 23.9% to 25.1% of patients investigated for PE). Rate of PE with PCTA was 15.9% (95%CI [13.93–17.87]), which is greater than in other studies (<10%). It was positively associated with age (OR = 1.011, $p = 0.019$) and was higher when requested by medical internists (OR = 2.201, $p = 0.019$) and with patients from ICU (OR = 4.210, $p = 0.003$).

INTERVENTIONS / ACTION PLAN: Results were discussed in an intradepartmental reunion. Funding of a prospective study was considered.

DISCUSSION / CONCLUSIONS: Rate of positive diagnosis of PE with at the CHUM is higher than in other studies. A prospective study could be done to specify clinical and paraclinical data associated with PE in a context of utilization evaluation, as well as to assess cost-efficiency.

09:30 – AP004

CT PULMONARY ANGIOGRAPHY AUDIT

Authors: Ibraheem Afzal, Michael Colapinto, Ehsan Haider

PRINCIPAL LOCATION OF AUDIT: Three university-based hospitals in one city.

BACKGROUND AND AIM: Published theoretical minimum attenuation of blood required to identify all acute and chronic PE is 211HU. Prior research also suggests up to 10.8% of all CT PAs may be suboptimal due to multiple causes, with motion artifact and bolus enhancement being the most frequent cited reasons. Goal: determine how the three hospitals compare to the standards.

AUDIT TARGET: No more than 10.8% CT PAs have less than 211 HU enhancement of main pulmonary outflow tract.

METHODS: All CT PA were identified at the three hospitals by their respective title searches over a 20-day period. Variable collected:

- Patient Demographics
- Main pulmonary outflow tract (MPOT) enhancement. A circular region of interest was measured in the largest axial image of the main pulmonary artery with a diameter of approximately 50% of the vessel.
- Result: +/- for PE.
- Motion artifact, body habitus, opacification of distal vessels, timing of contrast
- CT protocols

RESULTS: The percentage of indeterminate studies at hospital 1, 2, and 3 were 1.5%, 12.3%, and 9.5% respectively.

INTERVENTIONS / ACTION PLAN: For hospital 2:

1. Encourage minimal inspiration
2. Consider increase in kVP for large patients
3. Improve distal opacification by increasing the initial contrast bolus from 30ml to 40ml

DISCUSSION / CONCLUSIONS: Hospital 2 was subpar in meeting the published criteria for inadequate studies by 1.5%. The studies that did not meet the criteria of 211HU enhancement of the MPOT were analyzed for other variables such as breathing, habitus, etc. Areas of improvements are suggested and future audit is recommended.

09:40 – AP005

HEPATIC ARTERY PSEUDOANEURYSM EMBOLIZATION

Authors: Patrick Kennedy, George Markose

PRINCIPAL LOCATION OF AUDIT: University-affiliated urban hospital.

BACKGROUND AND AIM: With the increasing frequency of percutaneous biliary interventions and liver transplantations, hepatic artery pseudoaneurysm (HAPA) is now the most commonly reported visceral artery aneurysm. Due to the high mortality rates associated with open surgical ligation, transcatheter embolization is being used increasingly for the treatment of HAPAs. The purpose of this audit is to determine the technical success and mortality rates of HAPA embolization at our institution and compare these findings to results in the literature.

AUDIT TARGET: Technical success should be achieved in 100% of cases. The 30-day mortality rate should be less than or equal to 11%.

METHODS: All cases of HAPA embolization from 2012 to 2016 were isolated using PACS. Clinical notes, previous imaging, and procedural reports were also reviewed. The date of the procedure, 30-day mortality, aneurysm size, aneurysm location, and demographic information were also recorded.

RESULTS: Eleven patients underwent HAPA embolization at our institution within the five-year period, with technical success achieved in 100% of cases. Mortality rate at 30 days was 9.1%. Both targets were achieved.

INTERVENTIONS / ACTION PLAN: Departmental education sessions will be arranged based on ongoing development of novel embolization techniques. A need for consensus guidelines may be proposed to the Society of Interventional Radiology.

DISCUSSION / CONCLUSIONS: Although comparable data in the literature is limited, our results suggest that HAPA embolization is being performed safely and effectively at our institution. Regular audits are necessary to ensure quality of care for patients undergoing urgent embolization procedures.

09:50 – AP006

REDUCED INTER-PATIENT VARIABILITY IN HEPATIC ENHANCEMENT AT ABDOMINAL CT USING LEAN BODY WEIGHT FOR INTRAVENOUS CONTRAST DOSING

Authors: Kris A. Peet, Andreu Costa

PRINCIPAL LOCATION OF AUDIT: University hospital.

BACKGROUND AND AIM: Recent studies show reduced inter-patient variability in solid organ enhancement at abdominal CT by dosing intravenous contrast according to lean body weight (LBW). The purpose of this audit was to assess the inter-patient variability in hepatic enhancement with our routine contrast dosing scheme (1.3cc/kg, maximum 150cc) as compared to a modified dosing protocol (1.9cc/kg of LBW, maximum 150cc).

AUDIT TARGET: 100% of cases

METHODS: Pre- and post- contrast liver attenuation was measured by drawing 3 regions of interest on 1) a single axial "scout" image of the liver acquired prior to administering contrast, and 2) the same corresponding location in the liver on the post-contrast portal venous phase. We analyzed CTs from July–December 2016 (routine dosing, n=100, 57 women), and January 2017-ongoing (modified dosing, n=25, 15 women to date).

RESULTS: First Cycle/Routine Protocol: The mean HAD was 56±12 (range, 35-101) HU and the CV was 22%.

Second Cycle/Modified Protocol: The mean HAD was 66±10 (range, 51-83) HU and the CV was 14%.

INTERVENTIONS / ACTION PLAN: Future cycles will focus on correcting for change in HAD according to peak kilovoltage, and tailoring the dose for a mean HAD as close to 50 HU as possible. Results will be disseminated through a departmental grand rounds presentation and the district clinical affairs committee.

DISCUSSION / CONCLUSIONS: Preliminary results show improved inter-patient variability in HAD by dosing intravenous contrast according to LBW.

10:00 – AP007

GETTING TO ZERO: A QUALITY ASSESSMENT OF MULTIPLE INTERVENTIONS AIMED TO REDUCE CANCELLATION RATES IN AN ULTRASOUND-GUIDED BIOPSY PROGRAM

Authors: Stephanie Kenny, Ania Kielar

PRINCIPAL LOCATION OF AUDIT: Academic hospital.

BACKGROUND AND AIM: We noticed same-day cancellations of ultrasound-guided biopsies resulting in wasted resources and inefficient workflow.

AUDIT TARGET: The purpose of our clinical audit was to reduce biopsy cancellation rates.

METHODS: A database of every biopsy performed in our ultrasound department was prospectively recorded from November 2012. Cancellation was defined where a biopsy either could not be attempted or was aborted.

Multiple interventions aimed at reducing cancellations were instituted at different time points, including: creation of a protocol decision support email group; formalized pre-booking anticoagulation guidelines; and a dedicated paracentesis program including nursing and recovery space.

For each intervention, the cancellation rates 6 months pre- and post-intervention were tested for statistical significance using Fisher's exact test.

RESULTS: 4954 biopsies were scheduled during the study period from November 2012-2015. Types of biopsies included paracentesis, liver, kidney, spleen, pancreas, thyroid, lymph node and omentum.

The cancellation rate increased from 28/749 = 3.7% to 32/707 = 4.5% after our protocol decision support intervention ($p = 0.510$). The cancellation rate prior to instituting anticoagulation guidelines was 79/909 = 8.7%, which decreased post-intervention to 71/976 = 7.3% ($p = 0.269$). There was a significant decrease in cancellations from 78/962 = 8.1% to 51/916 = 5.6% after the dedicated paracentesis program ($p = 0.035$).

INTERVENTIONS / ACTION PLAN: Implementation of a dedicated paracentesis program significantly decreased biopsy cancellations at our institution. Other interventions were less effective.

DISCUSSION / CONCLUSIONS: Overall growth in number and complexity of cases over the studied period confounds audit results. Next steps will build on principles of success to improve dedicated nursing support.

10:10 – AP008

COMPLIANCE WITH RECOMMENDED FOLLOW-UP FOR INCIDENTAL PULMONARY NODULES FOUND ON CT CHEST STUDIES

Authors: Ankur Goel, Jonathan Abele, Sukhvinder Dhillon, Amy Folk, Gerrit Van Der Merwe

PRINCIPAL LOCATION OF AUDIT: Multiple university affiliated hospital sites.

BACKGROUND AND AIM: Up to 51% of smokers aged 50 years or older have incidental pulmonary nodules on CT chest studies. Although many of these incidental nodules are benign, follow-up of these nodules is recommended, commonly using guidelines published by the Fleischner Society, especially with nodules greater than 4 mm in size and in higher risk populations such as smokers. The aim of this audit project is to determine if follow-up studies are being performed for incidental pulmonary nodules as recommended.

AUDIT TARGET: Follow-up studies for incidental pulmonary nodules should be performed within +/- 1 month as recommended on the initial CT chest study in 100% of the cases.

METHODS: 52 CT chest studies for pulmonary embolus with incidental pulmonary nodules performed between May 2014 and July 2014 were reviewed. The patient's follow-up imaging record was then reviewed to determine whether or not a follow-up study had been performed.

RESULTS: Follow-up studies were performed in 32/52 (62%) of cases over a period of 2 to 18 months. Of these, 24/52 cases were performed within +/- 1 month of the recommended timeline (46%). The target was not achieved.

INTERVENTIONS / ACTION PLAN: Since March 2016, radiologists at our institution have been requested to insert a large font bold paragraph at the start of the impression portion of their report that highlights the need for action/follow-up.

DISCUSSION / CONCLUSIONS: A re-audit will be performed to assess for any change in follow-up rates. Results from the second cycle of data collection will be presented at the annual scientific meeting.

10:20 – AP009

PICA AND PERICALLOSAL ARTERY ORIGIN INCLUSION IN MAGNETIC RESONANCE ANGIOGRAPHY WITH TIME-OF-FLIGHT TECHNIQUE FOR ANEURYSM SCREENING AND SURVEILLANCE

Authors: Mitchell P. Wilson, Jonathan Hung, Sandeep Naik

PRINCIPAL LOCATION OF AUDIT: Three MRI capable hospitals in Edmonton which perform screening and surveillance time-of-flight magnetic resonance angiography (TOF MRA) for intracranial aneurysms.

BACKGROUND AND AIM: MRA with TOF has a high sensitivity for identifying intracranial aneurysms. A small percentage of intracranial aneurysms arise from the posterior inferior cerebellar artery (PICA) and pericallosal artery origins. Including these artery origins is important for a complete screening/surveillance study.

AUDIT TARGET: No known benchmark targets exist. We established a target of 95% to allow for a small degree of error related to technical and/or patient specific factors.

METHODS: We retrospectively analyzed 35 screening and surveillance TOF MRA studies performed on adult patients at three hospitals (105 total). Study accession numbers, gender, presence of the vertebral artery trans-dural passage (V4 origins), presence of the PICA origins, and presence of the pericallosal artery origin was collected from the picture archiving and communication system (PACS) at each hospital. Thirty-five screening and surveillance TOF MRAs from each institution are again evaluated post-intervention.

RESULTS: Twenty-six studies (25%) did not include either the PICA or pericallosal origins, and 16 (15%) did not include either the V4 or pericallosal artery origins.

INTERVENTIONS / ACTION PLAN: We modified our existing protocol, angling the TOF reconstruction by 5-10 degrees from the hard palate. Technicians at each site were educated of the protocol change with emails, meeting updates, and signage in the MR departments.

DISCUSSION / CONCLUSIONS: As of December 2016, 58 studies have been performed post-intervention. Only one (2%) is inadequate thus far. Finalized data collection and analysis will be completed prior to the CAR ASM 2017.

RADIOLOGISTS-IN-TRAINING CONTEST | CONCOURS POUR LES RADIOLOGISTES EN FORMATION POSTDOCTORALE

FRIDAY, APRIL 21, 2017
Radiologists-in-Training Contest – Oral Presentations – Salon Jarry / Joyce (Level A)
Prizes for this contest are funded by the Canadian Radiological Foundation (CRF) and will be awarded during the Wine and Cheese Reception and Awards Ceremony on Saturday, April 22, 2017.

VENDREDI LE 21 AVRIL 2017
Concours pour les radiologistes en formation postdoctorale – Présentations orales – Salon Jarry / Joyce (Niveau A)
Les prix pour ce concours sont financés par la Fondation radiologique canadienne (FRC) et seront remis samedi, le 22 avril, lors de la Soirée vins et fromages et remise des prix.

JUDGES / JUGES : Dr. Marco Essig, Dr. Faisal Khosa, Dr. Mark Levental

MODERATOR / MODÉRATEUR : Dr. Gilles Bouchard

13:30 – RT001

VACUUM-ASSISTED COMPLETE EXCISION OF SOLID INTRADUCTAL/INTRACYSTIC MASSES AND COMPLEX CYSTS: IS FOLLOW-UP NECESSARY?

Authors: Vanessa Quinn-Laurin, Nathalie Duchesne, Jean-Charles Hogue, Sylvie Pinault

OBJECTIVE: Management of complex cysts and benign intraductal/intracystic masses (CC) is controversial. The aim of this study was to determine if the complete removal of the CC image with ultrasound-guided vacuum-assisted excision (US-VAE) is sufficient for their safe management when the histological diagnosis obtained is benign.

METHODS: This is a single institution retrospective study performed on patients who underwent breast biopsy between April 2007 and September 2013. Patients with complete removal of CC image by US-VAE and with a benign diagnosis were included. Size, morphology, histological diagnosis, and surgical or imaging follow-up of the lesions were analyzed.

RESULTS / DISCUSSION: Three hundred and one lesions were biopsied with US-VAB during the study period and 131 met the inclusion criteria. Benign papilloma represented 32% (42/131) of the lesions; the remaining lesions had various benign diagnoses. Mean size of the solid mass or the cysts' thickest septum was 7 mm (range, 2-24). Mean imaging follow-up was 34.9 months (24-99 months). No recurrence or malignancy in the post-biopsy bed were observed during follow-up. Eleven lesions (8.4%) underwent surgery as follow-up: no cancer was found, but two lesions demonstrated atypia.

CONCLUSION: Complete excision of CC image with US-VAE with benign histology does not require further imaging follow-up or surgery and a return to routine screening can be safely recommended. In a world where global health care delivery and accessibility is important, elimination of unnecessary follow-ups is pertinent given its lower cost and lesser social impact.

13:40 – RT002

INTESTINAL PNEUMATOSIS: WORRISOME CLINICAL AND CT SIGN

Authors: Christophe Cloutier Lambert, Myriam Bambonye, Patrick-Olivier Décarie, Alexandre Dugas, Julie Lafrance, Charles-Étienne Martel-Pelletier

OBJECTIVE: Intestinal pneumatosis, usually found on computed tomography (CT) examination, is classically associated with bowel ischemia. However, it has many aetiologies, with a wide range of outcome, varying from benign to life-threatening. In the presence of intestinal pneumatosis, is would therefore be pertinent to identify additional findings (clinical and radiological) that are associated with a worst prognosis.

METHODS: We conducted a retrospective study including all cases of pneumatosis intestinalis found on abdominal CT examination at our institution from January 1st 2011 to January 1st 2016. Each of the 136 CT were reanalyse looking for the presence of several radiological and paraclinical factors we believed could be associated with a worst clinical outcome. Each factor were then individually assessed using Odd Ratio (OR) for bad outcome (surgery or intensive care treatment) and mortality.

RESULTS / DISCUSSION: Overall, 44/136 patients died, and another 25 needed surgery or intensive care treatment. Several CT signs were significantly associated with increased mortality including portal venous gas (OR 4.69), involvement of 2 or more bowel segments (OR 31.14), and classic signs of ischemia (localized fat stranding (OR 17.83), bowel wall hypo-enhancement (OR 8.15) and arterial thrombus (OR 7.00)). Age over 65 (OR 1.06), elevated serum lactate (OR 4.15) and white blood cell count (OR 6.95) were also significantly associated with increased mortality. Pneumatosis involving only the colon was significantly associated with decreased mortality (OR 0.12)

CONCLUSION: Intestinal pneumatosis is associated with a worst clinical outcome when at CT examination there are additionnal signs of ischemia, portal venous gas or multisegment involvment.

13:50 – RT003

LEADERSHIP IN HEALTHCARE: A BIBLIOMETRIC ANALYSIS OF 100 PUBLICATIONS

Authors: Timothy L. Miao, Nizar Bhulani, Faisal Khosa, Savvas Nicolaou, Alexander Norbash, Hugue Ouellette

OBJECTIVE: Although leadership is fundamental in delivering effective healthcare, career progression in healthcare typically focuses on academic and technical ability rather than on formal leadership education. We analyzed the 100 most-cited articles on leadership in healthcare via a bibliometric analysis to better understand categories and topics in leadership science and their relationship to healthcare.

METHODS: Using Elsevier's Scopus, a bibliometric analysis was performed to identify the 100 most cited articles on leadership in healthcare. Articles were ranked by citation count and three independent reviewers screened the abstracts for inclusion. Articles were included if they (1) examined leadership in the context of healthcare and (2) leadership was the primary focus of the article.

RESULTS / DISCUSSION: Citations for the 100 most-cited articles ranged from 53 to 487. Articles were published across 50 journals, most commonly *Journal of Nursing Management* (13%), *Academic Medicine* (10%) and *Journal of Nursing Administration* (10%). The majority of articles were published in the 2000s (81%). The articles focused on 6 specific leadership subjects with team building (33%), quality improvement (23%) and healthcare delivery (15%) being the most common. The articles were directed to or concerning any of 9 healthcare provider groups, most commonly nursing (40%), academic medicine (14%) and critical care medicine (14%).

CONCLUSION: Bibliometric analysis suggests a relatively higher level of leadership awareness and/or demand where team building and quality improvement concepts are concerned. Our analysis provides an opportunity to more effectively identify areas of both interest and demand for organized leadership education and training.

14:00 – RT004

IMAGING WORKUP FOR PULMONARY EMBOLUS: CAN WE AVOID EXPOSING PATIENTS TO RADIATION BY USING MAGNETIC RESONANCE ANGIOGRAPHY AS AN ALTERNATIVE IMAGING MODALITY?

Authors: Kevin Toporowicz, Jean-Marc Chauny, J. Paul Finn, Yassin Irislimane, Jean Lambert, Jeffrey Maki, Konstantin Papas, Josephine Pressacco

OBJECTIVE: Computed tomography pulmonary angiography (CTPA) is considered the "modern gold standard" imaging modality for Pulmonary embolus (PE). As many as 90% of tests for PE detection are negative. The main drawback of CTPA is ionizing radiation. This study evaluated the possibility of replacing CTPA by magnetic resonance angiography (MRA) in the diagnostic workup of the emergency department (ED) patient with suspected PE.

METHODS: Patients admitted to the ED and underwent clinically indicated CT for PE plus or minus lower limb ultrasound (US) were recruited for this study. Contrast-enhanced MRA on a 3.0 Tesla system was performed as an additional study for research to evaluate for PE and for deep venous thrombosis above the knee (DVT).

RESULTS / DISCUSSION: MRA exam success was greater than 90%. The sensitivity and specificity for the detection and exclusion of PE by MRA was 100% and 97%, respectively, for identifying thrombi in the main, lobar and segmental pulmonary arteries. The MRA protocol developed was rapid; performed within 15 min. The sensitivity and specificity for detection of DVT were 100%.

CONCLUSION: MRA was sensitive and specific compared to CTPA in the workup of PE. MRA appeared inferior to CTPA for the visualization of thrombus in the subsegmental pulmonary arterial branches. The MRA protocol developed was rapid and the simultaneous workup for above knee DVT was feasible. Further large-scale multicenter studies are needed to determine whether and under what circumstances MRA could replace CTPA for the workup of PE in the emergency department and beyond.

14:10 – RT005

THE RELEVANCE OF ABDOMINAL RADIOGRAPHS IN THE EVALUATION OF CHILDREN WITH COIN INGESTION

Authors: Naoya Shatani, Sara K. AlShaibani, Heather J. Bray, Bruce Phillips, Jim Potts

OBJECTIVE: Common practice following coin ingestion in pediatric patients is to localize the coin by performing radiographs from nares to anus. The purpose of our study is to determine the relevance of abdominal radiograph findings to the treatment of children presumed or reported to have swallowed a coin, as intervention is generally reserved for esophageal coins. We hypothesize that abdominal radiographs do not change management in coin ingestion patients.

METHODS: We reviewed the clinical history of 544 emergency patients of a single institution who underwent foreign body ingestion surveys between January 2012 and June 2016. We included only patients whose requisition stated a presumed or reported coin ingestion. Patients with inadequate clinical records were excluded from the study. The imaging findings (coin location, additional radiopaque foreign bodies) and clinical data (symptomatology, intervention) of 134 patients were recorded.

RESULTS / DISCUSSION: A coin was identified in 109 of 134 pediatric emergency studies reviewed. Non-coin radio-opaque foreign bodies were present in 3 patients. Of 42 patients with a coin identified in the esophagus, 35 were symptomatic, 7 were asymptomatic and 40 went on to endoscopic removal of the coin. Of 67 patients with a coin identified beyond the esophagus, 19 were symptomatic, 48 were asymptomatic and 2 went on to endoscopic removal (1 symptomatic, 1 asymptomatic).

CONCLUSION: Findings on abdominal radiographs rarely lead to surgical or endoscopic intervention in children presumed to have swallowed a coin, and their relevance should be reconsidered, particularly in asymptomatic patients.

14:20 – RT006

REDUCING WAIT-TIME FOR LUNG CANCER DIAGNOSIS AND TREATMENT: IMPACT OF A MULTIDISCIPLINARY, CENTRALIZED REFERRAL PROGRAM

Authors: Jessica L. Common, Rick Bhatia, Suzanne C. Byrne, Hensley H. Mariathas

OBJECTIVE: A multidisciplinary, centralized referral program was established at our institution in late 2014 to reduce the perceived delays in lung cancer diagnosis and treatment following diagnostic imaging observed with the traditional, individual practitioner-led referral process. The main objectives of this study were to determine if referral to the Thoracic Triage Panel (1) expedites lung cancer (a) diagnosis and (b) treatment initiation and (2) leads to more appropriate specialist consultation.

METHODS: Patients with a diagnosis of lung cancer and initial diagnostic imaging between March 1, 2015 and February 29, 2016 were identified and grouped according to whether they were referred to the Thoracic Triage Panel or managed through a traditional referral process. Wait-times (in days) from first abnormal imaging to biopsy, specialist consultation, and treatment initiation (including surgery, chemotherapy, and radiation) were recorded. Statistical analysis was performed using the Wilcoxon rank-sum test.

RESULTS / DISCUSSION: 133 patients who met inclusion criteria were identified. 79 patients were referred to the Thoracic Triage Panel and 54 were managed by traditional means. There was a statistically significant reduction in median wait-times for patients referred to the Panel. Wait-time from first abnormal imaging to biopsy decreased from 61.5 to 36.0 days ($p<0.0001$). Wait-time from first abnormal imaging to treatment initiation decreased from 118.0 to 80.0 days ($p<0.001$). The percentage of specialist consultations that led to treatment was also greater for patients referred to the Panel.

CONCLUSION: A collaborative, centralized intake and referral process helps to reduce wait-time and ensure appropriate specialist consultation in the diagnosis and treatment of lung cancer.

14:30 – RT007

REPORTING OF IMAGING DIAGNOSTIC ACCURACY STUDIES: ADHERENCE TO STARD 2015

Authors: Patrick J. Hong, Mostafa Alabousi, Patrick Bossuyt, Robert Frank, Daniel Korevaar, Trevor McGrath, Matthew McInnes, Hedyeh Ziai

OBJECTIVE: Published diagnostic accuracy studies are often not well reported. The level of adherence of diagnostic accuracy imaging research to STARD 2015 is not known.

1. To evaluate the adherence to STARD 2015 of diagnostic accuracy studies recently published in imaging journals
2. To provide a baseline for subsequent evaluations in reporting and inform an extension of STARD 2015 specific to imaging

METHODS: MEDLINE was searched for diagnostic accuracy studies published in imaging journals in 2016. Data extraction done in duplicate evaluated adherence of the included studies to the 30-item STARD 2015 checklist including many imaging specific sub-items. ANOVA tested for association between adherence and country, impact factor, modality, study design, STARD adoption by journal and subspecialty area.

RESULTS / DISCUSSION: 142 articles were included. The overall mean STARD score was 16.6 (SD=2.21). Although results are variable between studies, there are several areas of significant deficiency in reporting. These items deal with recruitment, blinding, flow diagrams, patient identification, sample size, and handling missing/indeterminate data. Details of the index test and reference standard were well reported to allow for replication while adverse events arising from these imaging tests were poorly reported.

ANOVA identified an association between adherence and impact factor ($p=0.001$) and STARD adoption by journals ($p=0.027$). Higher impact factor has been associated with increased STARD score. No associations were found for other variables.

CONCLUSION: Many essential items are not reported the majority of the time; this makes assessment of study quality challenging. This ultimately reduces the generalizability of the study and hinders its application in clinical practice.

15:30 – RT008

OVERINTERPRETATION OF RESEARCH FINDINGS: EVIDENCE OF 'SPIN' IN SYSTEMATIC REVIEWS OF DIAGNOSTIC ACCURACY STUDIES

Authors: Trevor A. McGrath, Patrick M. Bossuyt, Daniël A. Korevaar, Mariska M. Leeflang, Matthew D. McInnes, Nick van ES

OBJECTIVE: To assess the frequency of overinterpretation in systematic reviews of diagnostic accuracy studies.

METHODS: MEDLINE was searched through PubMed from December 2015 to January 2016. Systematic reviews of diagnostic accuracy studies in English were included if they reported one or more meta-analyses of accuracy estimates. We built and piloted a list of 10 items that represent actual overinterpretation in the abstract and/or full-text conclusion, and a list of 9 items that represent potential overinterpretation. Two investigators independently used the items to score each included systematic review, with disagreements resolved by consensus.

RESULTS / DISCUSSION: We included 112 systematic reviews. The majority had a positive conclusion regarding the accuracy or clinical usefulness of the investigated test in the abstract (n=83; 74%) and full-text (n=83; 74%). Of the 112 reviews, 81 (72%) contained at least one actual form of overinterpretation in the abstract, and 77 (69%) in the full-text. This was most often: a 'positive conclusion, not reflecting the reported summary accuracy estimates', in 55 (49%) abstracts and 56 (50%) full-texts and a 'positive conclusion, not taking high risk of bias and/or applicability concerns into account', in 47 abstracts (42%) and 26 full-texts (23%). Of these 112 reviews, 107 (96%) contained a form of potential overinterpretation, most frequently 'non-recommended statistical methods for meta-analysis performed' (n=57; 51%).

CONCLUSION: Most recent systematic reviews of diagnostic accuracy studies present positive conclusions and a majority contain a form of overinterpretation. This may lead to unjustified optimism about test performance and erroneous clinical decisions and recommendations.

15:40 – RT009

UTILIZING PRE-PROCEDURAL CT SCANS TO IDENTIFY PATIENTS AT RISK FOR SUBOPTIMAL EXTERNAL VENTRICULAR DRAIN PLACEMENT WITH THE FREEHAND INSERTION TECHNIQUE

Authors: Mitchell P. Wilson, Jeremy Rempel

OBJECTIVE: Freehand insertion remains the mainstay of external ventricular drain (EVD) placement, even though alternative techniques have shown decreased rates of malpositioning. Limitations in available alternatives when compared to freehand insertion necessitates stratification of patients likely to benefit from an alternative placement technique. The purpose of this study was to retrospectively evaluate which features of the pre-procedural CT scan predict malpositioning of EVDs when using the freehand insertion technique.

METHODS: We retrospectively evaluated 193 EVD insertions performed with the freehand technique through a burr hole between January 1, 2014 – December 31, 2015 at a level 1 trauma center in Edmonton, Alberta. Several features of the pre-insertion CT scan were evaluated for risk of malpositioning outside the ipsilateral frontal horn or third ventricle.

RESULTS / DISCUSSION: Fifty-two EVD insertions (27%) were suboptimally positioned, with 15 (8%) placed into eloquent cortex or non-target CSF spaces. Admitting diagnosis, head height-to-width ratio in axial plane, and side of predominant feature were found to be significantly associated with suboptimal placement ($p = 0.006$, 0.012, and 0.019 respectively). A decreased height-to-width ratio was also associated with placement into only eloquent cortex and/or non-target cerebrospinal fluid spaces ($p=0.005$).

CONCLUSION: Freehand insertion is associated with significant malpositioning into suboptimal functional spaces, cortex, and non-target CSF spaces. The likelihood of malpositioning can be predicted with baseline clinical and radiographic features, with height-to-width ratio appearing to be a novel but important radiographic predictor.

15:50 – RT010

AUTOMATING MEDICAL IMAGING PROTOCOL SELECTION: A FEASIBILITY STUDY OF MACHINE LEARNING IN QUALITY AND SAFETY

Authors: Andrew D. Brown, Thomas R. Marotta

OBJECTIVE: Our objective is to demonstrate the feasibility of automated protocol selection by applying natural language processing (NLP) to MRI requisitions.

METHODS: This study focused on MRI brain examinations performed from January 1, 2014 – June 30, 2015 at our institution. The dataset consisted of 7,487 observations. We randomly divided the dataset into a training set (70%) and test set (30%). Each MRI has an associated protocol which represents a set of MRI sequences. The prediction task represents a multilabel classification problem with 41 classes, each corresponding to an MRI sequence. We constructed three models to predict the specific image sequences for MRI examinations performed during our study period utilizing the tokenized clinical indication, as per standard NLP techniques, and demographic information. To measure the quality of the model predictions we calculate Hamming loss, accuracy, precision and recall. The models were compared to a baseline that predicted the most common protocol for all observations in the test set.

RESULTS / DISCUSSION: Table 1 presents a detailed list of model performance metrics. NLP is a field within machine learning dedicated to teaching computers to understand human speech. Our approach demonstrates the feasibility of using NLP techniques to automate protocol selection. These approaches significantly outperform the baseline. Automation represents an opportunity to not only improve efficiency and reduce costs but also improve quality and reduce errors.

CONCLUSION: The NLP-based models we present are able to protocol MRI brain examinations with high accuracy. Future work will focus on evaluating model performance for other imaging modalities and organ systems.

16:00 – RT013

IMAGING OF NON-LESIONAL EPILEPSY USING HYBRID PET/MRI: COMPARISON OF MR ATTENUATION CORRECTION (MRAC) AND CT ATTENUATION CORRECTION (CTAC)

Authors: Benjamin Y. Kwan, Udunna Anazodo, Jorge Burneo, William Pavlosky, Frank Prato, Jonathan Romsa, David Steven, Jonathan Thiessen

OBJECTIVE: PET/MR imaging can provide greater rates of lesion localization in patients with medically refractory epilepsy (MRE). However, the use of PET/MR can be limited by MR based attenuation correction (MRAC), where inaccurate estimation of correction factors may lead to falsely low areas of PET activity. Recent advances in MR image processing have improved the performance of MRAC for PET/MR neuroimaging. This paper compares a novel MRAC approach to CT based attenuation correction (CTAC) (the current clinical standard), both qualitatively and quantitatively in patients with MRE.

METHODS: PET/MR imaging was acquired simultaneously in 8 patients with MRE on a PET/MR system (Siemens Healthcare, Erlangen, Germany) immediately after a clinical PET/CT scan. PET/MR data were corrected for attenuation using a standard CTAC (PET-CTAC) and the RESOLUTE MRAC method (PET-MRAC). PET-CTAC and PET-MRAC were qualitatively compared through rating of metabolic activity in the frontal, temporal, parietal, occipital lobes and cerebellum from visual assessments, while quantitatively, the mean relative difference between the two PET images were calculated across voxels in the whole brain and in several brain regions.

RESULTS / DISCUSSION: Across all regions, qualitative assessment demonstrated complete concordance in findings of metabolic activity between PET-CTAC and PET-MRAC. The relative difference between PET-CTAC and PET-MRAC activity across the whole brain was 3.3%. Regional relative differences were greatest in the cerebellum (4.6%) and least in the limbic system (2.7%).

CONCLUSION: Qualitative and quantitative assessments of PET corrected using CTAC and MRAC methods in PET/MRI are similar in this study population and suggests the potential usage of PET/MRI in MRE.

16:10 – RT014

DETERMINING THE NECESSITY OF ORAL CONTRAST FOR ABDOMINAL/PELVIC COMPUTED TOMOGRAPHY SCANS: AN APPROACH USING BIOELECTRIC IMPEDANCE ANALYSIS AND BODY-MASS INDEX

Authors: Yuhao Wu, Ismail Ali, Faisal Khosa, Luck Louis, Patrick McLaughlin, Savvas Nicolaou, Timothy O'Connell, Bernd Teunissen

OBJECTIVE: Patients with a sufficient volume of intra-abdominal fat can successfully undergo abdominal/pelvic computed tomography (CT) scans without oral contrast, whereas oral contrast may be necessary in those with very low volumes of intra-abdominal fat. The purpose of this study is to determine whether body fat percentage, measured via a portable bioelectric impedance analysis device, and body-mass-index, can predict the amount of intra-abdominal fat and guide the delivery of oral contrast in patients scheduled for abdominal/pelvic CT.

METHODS: A prospective trial consisting of 101 patients was conducted at Vancouver General Hospital between June 1st and July 19th, 2016. BMI was calculated and fat percentage was measured using bioelectric impedance analysis methods. Three board-certified radiologists then reviewed each scan and designated an abdominal fat score of 1-5, with scores ≥ 3 indicating that there is sufficient intra-abdominal fat that oral contrast would be unnecessary.

RESULTS / DISCUSSION: Oral contrast administration was unnecessary in 97% of the High BMI (BMI ≥ 25) patients and necessary in 83% of the Low BMI patients (BMI ≤ 21). For patients with Intermediate BMIs (21 < BMI <25), using fat percentage ≥ 30% as an additional threshold would reduce the administration of oral contrast by 74%. Using BMI and bioelectrical impedance analysis in combination produced a sensitivity of 90% (18/20) and specificity of 90% (73/81) for predicting the requirement of oral contrast.

CONCLUSION: Using a combination of BMI and bioelectric impedance analysis better predicts which patients can forgo oral contrast before abdominal/pelvic CT which may improve emergency department workflow.

16:20 – RT015

A NEEDS ASSESSMENT OF SENIOR MEDICAL STUDENT RADIOLOGY ELECTIVES: WHERE ARE THE GAPS AND WHAT CAN WE IMPROVE?

Authors: Natasha Larocque, Karen Finlay, Stefanie Lee, Sandra Monteiro

OBJECTIVE: Designing Diagnostic Radiology electives for medical students is challenging due to the lack of patient care responsibilities compared to other clinical rotations. The purpose of this study was to conduct a needs assessment of Radiology electives at our institution in order to identify current educational gaps, suggestions for improvement, and set priorities for future elective structure.

METHODS: An online retrospective survey consisting of quantitative and qualitative components was sent to all students who completed a clerkship Radiology elective at McMaster University during the 2015 calendar year. The Salant-Dillman survey protocol was used to maximize response rate. Student evaluations of current and potential elective activities were assessed using dichotomous, ranking, and 5-point Likert scale questions (1=poor, 2=fair, 3=good, 4=very good, 5=excellent). Responses were analyzed using descriptive statistics. Two independent assessors analyzed qualitative data using quantitative content analysis.

RESULTS / DISCUSSION: Response rate was good (62%). Mean score for overall elective experience was 3.4/5 (SD=1.08). The majority of students (86%) believed they achieved their educational objectives during their elective. Self-rated radiology knowledge gained post-elective was 3.4/5 (SD=0.99). The highest rated educational activities were: working with residents (mean=4.1/5, SD=1.24) and attending resident rounds/self-study time (mean=3.6/5, SD=1.16). Suggestions for future elective activities included reviewing cases (37%) and having a structured schedule (31%). When compared to other clinical electives, (e.g. Medicine/Surgery), mean elective score was 3.1/5 (SD=1.16).

CONCLUSION: Although most students reported achieving their educational objectives, we have identified several areas for potential improvement, which can guide future efforts to restructure electives and will be prospectively studied at our site.

16:30 – RT016

ROUTE-TO-DIAGNOSIS OF LUNG CANCER IN NOVA SCOTIA

Authors: Aamir Suhail, Candice Crocker, Bijon Das, Daria Manos

OBJECTIVE: Most diagnostic algorithms regarding the use of imaging for suspected lung cancer and strategies for management following imaging are directed towards family physicians. However, international literature suggests that a significant proportion of lung cancer patients first access medical care via the Emergency Department (ED), with downstream inequality in health and survival outcomes when compared to non-ED based diagnoses. There is little Canadian data regarding route of lung cancer diagnosis.

METHODS: Following institutional REB approval, all incident cases of lung cancer diagnosed in 2014 were identified using province-wide registry data. This was matched to a provincial electronic radiology database to identify first presentation computed tomography or radiograph imaging and examine requisition point of origin. Survival curves were plotted using the Kaplan-Meier method.

RESULTS / DISCUSSION: 948 patients were diagnosed with lung cancer in Nova Scotia in 2014. 339 (36%) patients were diagnosed based on imaging initiated from an ED visit. Of these, all-cause mortality was 73.5% as of the censor date (April 1 2016) compared with 57% for alternate route presentation. Patients presenting to the ED demonstrated lower survival compared to non-ED diagnoses (HR=1.85, 95% CI: 1.57-2.18). 60% of ED presenting cancers were stage IV at diagnosis, versus 43% for non-ED.

CONCLUSION: The ED is a common route of presentation of lung cancer and is associated with advanced stage at diagnosis. This has implications for ED resource allocation while also raising concerns regarding barriers to primary care access. Strategies are needed to encourage earlier diagnosis and to ensure ED patients with suspicious imaging are followed appropriately.

FACULTY
CORPS PROFESSORAL

SHIELA APPAVOO, MD, FRCPC

University of Alberta, Edmonton, Alberta, Canada

Dr. Appavoo is a general radiologist with an interest in breast imaging. She is in practice with Medical Imaging Consultants in Edmonton. Currently she chairs the CAR Breast Imaging Working Group, which recently revised the Tomosynthesis section of the *CAR Practice Guidelines and Technical Standards for Breast Imaging and Intervention*.

PRESENTATION

- Breast Imaging | Breast Tomosynthesis in Practice: Early Experience with Screening and Diagnosis, Pg 58

DAVID C. BARNES, MD, FRCPC

Dalhousie University, Halifax, Nova Scotia, Canada

Dr. Barnes is Head of the Dalhousie University Department of Diagnostic Radiology, and was program director of Nuclear Medicine and Research Director until 2009. He practiced family medicine at the University of Waterloo Student Medical Clinic before completing a residency in radiology and nuclear medicine at Dalhousie University. He also completed a residency in nuclear medicine at the University of Western Ontario prior to joining the faculty at Dalhousie University in 1989.

MODERATOR

- The Challenges and Opportunities in Undergraduate Medical Education, Pg 41

The Honourable GAÉTAN BARRETTE, MD

Minister of Health and Social Services, Government of Quebec, Quebec, Quebec, Canada

Dr. Gaétan Barrette is the Quebec Minister of Health and Social Services, and was first elected to the National Assembly of Quebec in the 2014 election. He represents the electoral district of La Pinière as a member of the Quebec Liberal Party. A 1985 graduate in medicine of l'Université de Montréal, Dr. Barrette became a member of Royal College of Physicians and Surgeons of Canada in 1989. In 1991 he pursued a Fellowship in Vascular and Surgical Radiology at the University of California, San Diego. He currently practises at Maisonneuve-Rosemont Hospital where he has been on staff since 1990. Dr. Barrette was President of the Fédération des médecins spécialistes du Québec between 2006 and 2014. He was also Chairman of the Board of the Financière des professionnels Inc. which manages a $2 billion portfolio. He was also a member of the Boards of Sogemec Assurances Inc. and the Régie de l'assurance maladie du Québec (RAMQ). He also has been head of the Foundation of the Fédération des médecins spécialistes du Québec (2012 to 2014). Dr. Barrette participates regularly in various conferences and forums on the subject of specialized medicine throughout Quebec, across Canada and abroad.

PRESENTATION

- CAR Hot Topics | Fiscal Pressures on Healthcare in Quebec, Pg 57

FERCO BERGER, MD

Sunnybrook Health Sciences Centre, University of Toronto, Toronto, Ontario, Canada

Dr. Berger is a Dutch radiologist specialising in emergency and trauma radiology. He focused on this topic in the latter half of his radiology training in Amsterdam, further specialising in this field by completing a fellowship in emergency and trauma radiology in Vancouver. He returned to the Netherlands in 2011 to set up the new division in emergency and trauma radiology at the VU University Medical Center, the largest Level 1 trauma centre in Amsterdam. In 2016, he established the Emergency and Trauma Radiology Division at the Sunnybrook Health Sciences Centre Department of Medical Imaging in Toronto. He is doing so with a team of dedicated emergency and trauma radiologists.

PRESENTATION

- Radiology Care: A Value-Driven Approach (Emergency Radiology) | Polytrauma: Is It Always Whole-Body CT? Pg 45

ANA-MARIA BILAWICH, BSc, MD, FRCPC

University of British Columbia, Vancouver, British Columbia, Canada

Dr. Bilawich is a clinical assistant professor at the University of British Columbia Department of Radiology, Head of the Cardiothoracic Section at Vancouver General Hospital, and Co-Director of the Cardiothoracic Imaging Fellowship at Vancouver General Hospital, University of British Columbia. She has a special interest in interstitial lung disease and teaching at the undergraduate and postgraduate levels.

SIMULATION WORKSHOP

- HRCT of the Chest: A Hands-on Practical Workshop of Diffuse Lung Disease — Cystic Lung Diseases and Emphysema, Pg 50

ROBERT BLEAKNEY, MD

Joint Department of Medical Imaging (JDMI), University of Toronto, Toronto, Ontario, Canada

Dr. Bleakney is a musculoskeletal radiologist at the University of Toronto Joint Department of Medical Imaging. He is also Head of the Musculoskeletal Division, Musculoskeletal Fellowship Supervisor, and an assistant professor of Medical Imaging at the University of Toronto. Dr. Bleakney completed medical school at Queen's University in Belfast, Northern Ireland, and a residency in radiology at Aberdeen Royal Infirmary in Aberdeen, Scotland, prior to completing a fellowship in musculoskeletal radiology in Toronto. His clinical and research interests are education, sports imaging, musculoskeletal tumours and atypical femoral fractures.

PRESENTATION

- MSK: Sports Injuries I Sports MRI of the Hip and Groin, Pg 44

MODERATOR

- MSK: Sports Injuries, Pg 44

JOY BORGAONKAR, FRCPC

Dalhousie University, Halifax, Nova Scotia, Canada

Dr. Borgaonkar obtained a Bachelor of Science in 1989 and medical degree in 1993 from Memorial University of Newfoundland, where she also completed a residency in radiology. She completed a fellowship in breast imaging at the QEII Health Sciences Centre at Dalhousie University, followed by a fellowship in thoracic imaging at Massachusetts General Hospital, Harvard Medical School. She is currently assistant professor of Medicine at Dalhousie University. Her major interests are in the areas of clinical radiology and teaching. She has developed a program to proactively book CT scans to optimize the follow-up of incidentally-detected pulmonary nodules, and has developed an electronic resource to provide patients and physicians with information regarding the significance of these nodules. She has received an award for her teaching of Dalhousie radiology residents.

SIMULATION WORKSHOP

- HRCT of the Chest: A Hands-on Practical Workshop of Diffuse Lung Disease I Diffuse Abnormalities of Lung Density, Pg 50

GILLES BOUCHARD, MD

Université Laval, Québec, Québec, Quebec, Canada

Dr. Bouchard practices diagnostic radiology at the Centre hospitalier de l'Université (CHU) de Québec in Quebec City, and is a clinical professor at the Université Laval Department of Radiology. He completed a fellowship in magnetic resonance imaging at Mount Sinai Medical Center in Miami Beach 30 years ago. Since then, he has been teaching basic physics in magnetic resonance imaging in many residency programs at Université Laval. Over the last 25 years, he has been involved with the Royal College of Physicians and Surgeons of Canada examination and certification process. In 2016, he was nominated vice-president of the Société de radiologie du Québec, and will become president next November. In 2009, he received the Professor of the Year Award, given by the residents of the Université Laval diagnostic radiology program.

MODERATOR

- CAR Radiologists-in-Training Contest, Pg 86

DEAN BRUCE, MD, FRCPC

Medical Imaging Consultants and University of Alberta, Edmonton, Alberta, Canada

Dr. Bruce is Director of MRI with Medical Imaging Consultants, and has been a clinical radiologist there since 2007. He completed a musculoskeletal fellowship in San Diego, and spends more than half of his clinical work time involved in musculoskeletal imaging and procedures. Clinical teaching is very important to him, and he is an associate clinical professor of Radiology and Diagnostic Imaging at the University of Alberta Hospital.

PRESENTATION

- Mistakes We All Make | Improving MSK Interpretation Prowess, Pg 62

DANNY CACCAVELLI, F.PI., TEP

MD Management Limited, Montreal, Quebec, Canada

Danny Caccavelli, Financial Planner/Investment Advisor, joined MD Management Limited in 2008. Prior to that, he worked at a Canadian financial institution as a financial planner for high-net-worth clients. Danny's career in financial services began in 1999. Danny graduated from McGill University and holds Financial Planner (F.PI.) and Trust and Estate Practitioner (TEP) designations. He also belongs to the Institut québécois de planification financière (IQPF) and is a member of the Institute of Advanced Financial Planners (IAFP).

PRESENTATION

- Employment and Retirement | Building the Right Retirement Plan for You, Pg 38

TANYA P. CHAWLA, MBBS, FRCR, FRCPS

Joint Department of Medical Imaging (JDMI), University of Toronto, Toronto, Ontario, Canada

Dr. Chawla is an abdominal radiologist at University of Toronto Joint Department of Medical Imaging. She qualified in medicine at the Charing Cross and Westminster Medical School in London, England, and in radiology from the University of Southampton. After completing a fellowship in Toronto, she accepted a faculty position. Her interests are in the field of GI imaging and in postgraduate education. She has been actively engaged in both undergraduate and graduate teaching.

PRESENTATION

- Imaging Complications of Oncological Therapy and MR Elastography | Imaging the Complications of Oncological Therapy in the Abdomen, Pg 52

MODERATOR

- Imaging Complications of Oncological Therapy and MR Elastography, Pg 52

ELLEN M. CHUNG, MD

Uniformed Services University, Bethesda, Maryland, U.S.A.

Dr. Chung is an active-duty colonel in the United States Army, vice-chair of Radiology and Radiological Sciences at the Uniformed Services University of the Health Sciences (USUHS), and chief of the Pediatric Section at the American Institute for Radiologic Pathology. She served as the integrated chief of Diagnostic Radiology during the merger of Walter Reed Army Medical Center and National Naval Medical Center to form Walter Reed National Military Medical Center. A graduate of Georgetown University and Georgetown University School of Medicine, she completed a residency in radiology at Tripler Army Medical Center in Honolulu, Hawaii, followed by a fellowship in pediatric radiology at the Boston Children's Hospital. She is board-certified in radiology with a Certificate of Added Qualification in pediatric radiology.

PRESENTATION

- Plenary Session: Radiologic-Pathologic Correlation of Polycystic Kidney Disease and Other Ciliopathies, Pg 48

FRÉDÉRIC CLARENÇON, MD, PhD

Pitié-Salpêtrière University Hospital (AP-HP), Paris VI University, Paris, France

Dr. Clarençon is an interventional neuroradiologist and Head of the Pitié-Salpêtrière University Hospital Department of Interventional Neuroradiology in Paris. Dr. Clarençon's doctoral thesis was on advanced imaging techniques for brain arteriovenous malformations.

PRESENTATION

- Radiology Care: A Value-Driven Approach (Neuro) | Advanced Imaging of Cerebral and Spinal Vascular Malformations, Pg 36

JASON CLEMENT, MD FRCPC

University of British Columbia, Vancouver, British Columbia, Canada

Dr. Clement has been a radiologist at St. Paul's Hospital in Vancouver for the past 15 years. His practice includes interventional and diagnostic radiology. Dr. Clement is also a clinical assistant professor at the University of British Columbia.

PRESENTATION

- Post-Residency Panel | Preparing For Your First Year Out of Residency: Tips and Tricks, Pg 51
- Mistakes We All Make | Vascular Imaging and Intervention, Pg 62

ANDREU F. COSTA, MD, MSc, FRCPC

QEII Health Sciences Centre, Dalhousie University, Halifax, Nova Scotia, Canada

Dr. Costa is an academic abdominal radiologist at the QEII Health Sciences Centre, and an assistant professor at Dalhousie University. He has a keen interest in abdominal imaging research, particularly in imaging of hepatobiliary disease and in improving image quality. He is a committed teacher to radiology residents, fellows and medical students, and has been recognized with departmental teaching awards. As Head of the Abdominal Imaging Section at the QEII Health Sciences Centre, he is actively engaged in several administrative endeavours and committees at the local, provincial and national levels.

CONTEST JUDGE

- Educational Exhibits, Pg 64

HEATHER CURTIS, MD, FRCPC

Dalhousie University, Halifax, Nova Scotia, Canada

Dr. Curtis is an assistant professor of Radiology at Dalhousie University. She is a graduate of Dalhousie Medical School and completed a residency at Dalhousie University in 2009. After completing a fellowship in women's imaging at the University of Toronto in 2010, she returned to Halifax as a radiologist at the IWK Health Centre. In 2012, Dr. Curtis joined the Diagnostic Imaging Section at the QEII Health Sciences Centre, specializing in breast and abdominal imaging. Dr. Curtis is past president of the Nova Scotia Association of Radiologists, and has been the undergraduate program director for Diagnostic Imaging at Dalhousie University since 2012. She has a special interest in undergraduate medical education and oversees the clinical electives program. She participates in several departmental committees including the Residency Program Committee and the Medical Education Council for the Department of Diagnostic Imaging. She has been involved in the development of a national curriculum for undergraduate radiology education and is actively involved in the development, design and implementation of the undergraduate ultrasound curriculum at Dalhousie University.

PRESENTATION

- The Challenges and Opportunities in Undergraduate Medical Education | Ultrasound in Undergraduate Medical Education: A Tale of Two Programs, Pg 41

BRIAN DAY, MRCP (UK), FRCS (ENG), FRCS (CA)

Cambie Surgery Centre, Vancouver, British-Columbia, Canada

Dr. Day graduated in medicine from the University of Manchester. After postgraduate studies in internal medicine and general surgery, residency in orthopedics at the University of British Columbia, and trauma fellowships in Basel, Oxford and USC, he set up practice at Vancouver General Hospital and the University of British Columbia. He is recognized as a pioneer in arthroscopic surgery and sports medicine in Canada. Due to his interest in technology, he was involved in developing the world's first surgical robot and the first satellite telemedicine broadcast between North America and China. In 1979, he was the recipient of the Canadian Orthopaedic Association's Edouard Samson Award for outstanding research. Dr. Day served as Vice-President of the Canadian Orthopedic Foundation, a charitable foundation, and has served on the executive of the Canadian Orthopedic Research Society. He is a former research committee chair and past president of the Arthroscopy Association of North America, the world's leading academic society in his field. He has lectured worldwide and has published over 200 articles and book chapters. In addition to academic orthopedics, he has studied, lectured, and written on health policy. He is a Past President of the Canadian Medical Association. In 2014, Dr. Day was honoured to receive the Don Rix Leadership Award from the Doctors of BC. He is motivated to support the Doctors of BC in creating a health system that is excellent for patients and physicians.

PRESENTATION

- CAR Hot Topics | Access to Healthcare in Canada and How Canada Ranks Compared to the Rest of the World, Pg 57

CAROLE DENNIE, MD, FRCPC

University of Ottawa, Ottawa, Ontario, Canada

Dr. Dennie is a professor of Diagnostic Radiology at the University of Ottawa. She completed residencies at the University of Ottawa and McMaster University, and a fellowship in thoracic radiology as well as additional subspecialty training in cardiac MRI. She is Head of Thoracic and Cardiac Imaging at The Ottawa Hospital and Co-Director of Cardiac Radiology and MRI at the University of Ottawa Heart Institute. She is Director of Continuing Medical Education in the Department of Diagnostic Radiology at the University of Ottawa, and Chair of the Diagnostic Radiology Examination Committee of the Royal College of Physicians and Surgeons of Canada.

PRESENTATION

- Radiology Care: A Value-Driven Approach (Thoracic) | Transforming Lung Cancer Referrals: Ensuring a Value-Added Service, Pg 40

MODERATOR

- Radiology Care: A Value-Driven Approach (Thoracic), Pg 40

SUKHVINDER DHILLON, MD

University of Alberta, Edmonton, Alberta, Canada

Born and raised in the U.K., Dr. Dhillon completed a musculoskeletal fellowship at the University of Alberta and moved to Edmonton in 2003. His research interests include MRI of ankylosing spondylitis and aspects of spinal anatomy. Over the past three years he has developed a major interest in medical education. His primary focus in this field is making the process of learning radiology more efficient by using targeted methods. He is currently developing online educational material and a radiology learning lab. He also has a keen interest in departmental clinical audit, and has helped to author the CAR clinical audit website.

CONTEST JUDGE

- Departmental Clinical Audit Projects Contest, Pg 81

DEREK J. EMERY, MD

University of Alberta, Edmonton, Alberta, Canada

Dr. Emery is Professor and Chair of the University of Alberta Department of Radiology and Diagnostic Imaging. He is a neuroradiologist with a research interest in the study of appropriateness and in the use of magnetic resonance imaging to study neurologic disease. He is the medical director at the Peter S. Allen MR Research Centre at the University of Alberta. Dr. Emery is active in teaching and clinical neuroradiology.

CONTEST JUDGE

- Educational Exhibits, Pg 64

MARCO ESSIG, MD, PhD, FRCPC

University of Manitoba, Winnipeg, Manitoba, Canada

Dr. Essig is Professor and Chair of the University of Manitoba Radiology Department, and medical director of the Winnipeg Regional Health Authority Diagnostic Imaging Program. He received his medical degree and doctorate in neurological sciences from the University of Heidelberg, Germany. After completing a residency in radiology at the German Cancer Research Centre, Dr. Essig completed a fellowship in neuroradiology at the University of Iowa Hospitals and Clinics, and a second in interventional radiology at Brigham and Women's Hospital at the Harvard Medical School. Dr. Essig earned a board certification in diagnostic radiology and neuroradiology and was appointed professor at the University of Heidelberg in 2006. Dr. Essig's research focuses on the integration of functional imaging techniques into neuroimaging protocols in order to enable individualized and improved patient management with a special focus on brain cancer.

CONTEST JUDGE

- CAR Radiologists-in-Training Contest, Pg 86

NAJLA FASIH, FRCR, FRCPC

University of Ottawa, Ottawa, Ontario, Canada

Dr. Fasih is a radiologist and associate professor at the University of Ottawa Radiology Department, Abdominal Imaging and Abdominal MRI Division. She obtained a radiology certification in London, England, after completing a residency in Lahore, Pakistan, in 2004. She completed a subspecialty fellowship in abdominal imaging at the University of Ottawa. Dr. Fasih's subspecialty interests include oncological and gynecological imaging as well as therapeutic intervention including radiofrequency ablation. She has been involved in several teaching and research initiatives at the University of Ottawa and is the humble recipient of teaching awards at both the undergraduate and postgraduate levels. She has been a course director for several continuing professional development courses in diagnostic imaging offered at the University of Ottawa.

CONTEST JUDGE

- Departmental Clinical Audit Projects Contest, Pg 81

REZA FORGHANI, MD, PhD

Jewish General Hospital and McGill University, Montreal, Quebec, Canada

Dr. Forghani is Associate Chief at the Jewish General Hospital Department of Radiology, a tertiary-care teaching hospital affiliated with McGill University, a clinical investigator at the Jewish General Hospital Lady Davis Institute and Segal Cancer Centre, and an assistant professor of Radiology at McGill University. He completed his M.D. and Ph.D., as well as a residency in radiology at McGill University, followed by a fellowship in diagnostic neuroradiology at the Massachusetts General Hospital, Harvard Medical School. Dr. Forghani's expertise is in neuroradiology and head and neck imaging. He has a special interest in head and neck cancer, advanced imaging and analysis, and genome-phenotype correlation. He is currently leading an active research program, evaluating applications of dual-energy CT for the evaluation of head and neck pathology and advanced image texture or radiomic analysis, focusing on head and neck cancer.

CONTEST JUDGE

- Departmental Clinical Audit Projects Contest, Pg 81

BRUCE B. FORSTER, MSc, MD, FRCPC

University of British Columbia, Vancouver, British Columbia, Canada

Dr. Forster is Professor and Head of the University of British Columbia Radiology Department, and Regional Department Head and Medical Director of Diagnostic Imaging at Vancouver Coastal Health and Providence Health Care. He was recently Director of Diagnostic Imaging for the Vancouver 2010 Winter Olympics/Paralympics Games. As an associate member of the Allan McGavin Sports Medicine Centre, he has been involved in the clinical, educational, and research aspects of sports imaging for 25 years; he is also consultant to the editor for *Radiology*, and associate editor of *British Journal of Sports Medicine*. Dr. Forster has delivered over 300 invited lectures, many internationally, and has served as a visiting professor in Canada, the United States, Indonesia, Singapore, Japan, and the Middle East. He is the author of over 110 peer-reviewed scientific publications, and 100 educational exhibits, and has served as president of the Pacific Northwest Radiology Society, and on the Board of Directors of the Canadian Association of Radiologists and is currently on the Board of Directors of the Canadian Radiological Foundation. Dr. Forster is Lead Physician for *Choosing Wisely: Medical Imaging*, one of the most comprehensive appropriateness initiatives in British Columbia, and is chair of the CAR/CRF/UBC Radiology Leadership and Business course, in collaboration with the Sauder School of Business.

PRESENTATION

- The Challenges and Opportunities in Undergraduate Medical Education | Collaborating with Anatomists: The Future of Pre-Clinical Radiology, Pg 41

MARGARET A. FRASER, MDCM, FRCPC

University of Ottawa, Ottawa, Ontario, Canada

Dr. Fraser completed a residency in radiology at McGill University and a body imaging fellowship at the University of Toronto. She practises body imaging and emergency radiology at The Ottawa Hospital Department of Medical Imaging, with special interest in gynecological and gastrointestinal disease. She is happy to be in beautiful Montreal for the Canadian Association of Radiologists' 80th Annual Scientific Meeting.

PRESENTATION

- Controversies in Radiology | Controversies and Opportunities in the Diagnosis of Endometriosis, Pg 55

BRIAN GOLDMAN, MD, FACEP, FCFP

Mount Sinai Hospital, Toronto, Ontario, Canada

Dr. Goldman is an emergency room physician at Mount Sinai Hospital, and an assistant professor at the University of Toronto Department of Family and Community Medicine. Since 2007, he has hosted White Coat, Black Art, an award-winning show about the culture of modern medicine on CBC Radio One. His TED talk, *Doctors Make Mistakes: Can We Talk About That?* has been viewed more than 1.2 million times. He is the author of Canadian bestsellers *The Night Shift — Real Life in the Heart of the ER* and *The Secret Language of Doctors*.

PRESENTATION

- Feature Lecture: Empathy and Patient Engagement in 21st-Century Radiology, Pg 35

MAYANK GOYAL, MD, FRCPC

University of Calgary, Calgary, Alberta, Canada

Dr. Goyal is a professor of Radiology and Clinical Neurosciences at the University of Calgary. He is Director of Imaging and Endovascular Treatment at the Calgary Stroke Program. Dr. Goyal's passion and main research interest is acute stroke imaging, workflow and intervention (over 190 publications). He is one of the principal investigators in two multi-centric trials in the field, ESCAPE and SWIFT PRIME, both published in NEJM. Dr. Goyal is also an innovator, and has patented a novel imaging technique called *multiphase CTA* (used in ESCAPE and tested in the PROVE IT study). Initial results and feedback, published in *Radiology*, suggest that the technique is extremely useful and saves on average 20 minutes in acute stroke treatment. He is also leading a meta-analysis (HERMES) consisting of the recent five positive trials published in NEJM. The first two papers (Mayank as first/co-first author) were recently published in *The Lancet* and JAMA.

KEYNOTE PRESENTATIONS

- Opening Lecture | Changing Acute Stroke: A Journey, Pg 34
- Plenary Session: Rethinking Stroke Imaging in Light of Recent Evidence, Pg 35

WILL GUEST, MD, PhD

University of British Columbia, Vancouver, British Columbia, Canada

Dr. Guest grew up in Winnipeg and obtained his undergraduate degree in physics and biochemistry from the University of Manitoba. He then moved to Vancouver to enroll in the MD/PhD program at the University of British Columbia, completing his doctoral research on the biophysics of protein misfolding in neurodegeneration. He is now a 4th year radiology resident at the University of British Columbia. Next year he will be moving to Toronto for a fellowship in diagnostic and interventional neuroradiology.

PRESENTATION

- Advanced Technologies: Novel Technologies | Determining Risk of Myocardial Infarction from Cardiac CT: Unlocking the Power of Artificial Intelligence, Pg 54

ASHISH GUPTA, MD

The Ottawa Hospital, University of Ottawa, Ottawa, Ontario, Canada

Dr. Gupta is an assistant professor at The Ottawa Hospital Department of Diagnostic Imaging, University of Ottawa. He is a member of the Thoracic Imaging Division and the Angiography and Interventional Radiology Division. He completed postgraduate studies in radiodiagnosis at the Postgraduate Institute of Medical Education and Research, Chandigarh, India, in 2007. He completed a subspecialisation in cardiovascular and intervention radiology at the All India Institute of Medical Sciences, New Delhi, India, in 2009, and clinical fellowships in thoracic imaging in 2010 and angiointerventional radiology in 2011 at the University of Ottawa. His interests in thoracic radiology include imaging of lung cancer, pleura and thoracic interventions.

SIMULATION WORKSHOP

- HRCT of the Chest: A Hands-on Practical Workshop of Diffuse Lung Disease | Fibrotic Interstitial Lung Diseases, Pg 50

RAJIV GUPTA, MD, PhD, MSc, BE

Massachusetts General Hospital (MGH) and Harvard Medical School, Boston, Massachusetts, U.S.A.

Dr. Gupta is an associate radiologist at the Massachusetts General Hospital (MGH), an assistant professor of Radiology at the Harvard Medical School, and a lecturer in mechanical engineering at Massachusetts Institute of Technology. Dr. Gupta earned a medical degree from Cornell University, a Ph.D. in Computer Science at the State University of New York at Stony Brook, a Master of Science (Physics) and a Bachelor of Engineering (Electrical) from BITS, Pilani. He also directs the Advanced X-ray Imaging Sciences (AXIS) Center at MGH. Prior to joining MGH, Dr. Gupta was a computer scientist at GE Global Research Center in Niskayuna, New York, conducting research in medical imaging, non-destructive evaluation of aircraft engine parts, and computer vision. He also served on the faculty of the University of Southern California, Los Angeles, Department of Electrical Engineering Systems. Dr. Gupta's research interests include development and clinical applications of novel X-ray imaging modalities.

PRESENTATION

- Advanced Technologies: CT | Dual Energy CT: Principles, Technology, and Clinical Applications, Pg 49

CAMERON J. HAGUE, MD

University of British Columbia, Vancouver, British Columbia, Canada

Dr. Hague is a cardiothoracic radiologist at St. Paul's Hospital in Vancouver. He has a special interest in interstitial lung disease and COPD research. Dr. Hague also has a keen interest in teaching, serving for many years on the University of British Columbia Radiology Medical Education Committee, and has received numerous teaching awards.

MODERATOR

- Post-Residency Panel | Preparing For Your First Year Out of Residency: Tips and Tricks, Pg 51
- Resident Review: Thoracic Imaging, Pg 53 and 56
- Junior Hot Seat Session for Residents, Pg 59
- Senior Hot Seat Session for Residents, Pg 59

ANGUS HARTERY, MD, FRCPC

Memorial University, Paradise, Newfoundland, Canada

Dr. Hartery is a practising radiologist and clinical assistant professor in the Discipline of Radiology at Memorial University. Dr. Hartery completed a fellowship in abdominal imaging at the University of Toronto University Health Network in 2011. He is currently Director of the Postgraduate Radiology Residency Program. His interests are postgraduate and undergraduate medical education, online education with interactivity to promote engagement, and online assessment with immediate feedback and statistical analysis. Dr. Hartery has previously received the Region 5 Mentor of the Year Award from the Royal College of Physicians and Surgeons of Canada. Dr. Hartery is very pleased to be participating at the CAR Annual Scientific Meeting.

PRESENTATION

- Junior Hot Seat Session for Residents, Pg 59
- Mistakes We All Make | Abdominal Imaging, Pg 62

JULIE HURTEAU-MILLER, MD, FRCPC

Children's Hospital of Eastern Ontario, Ottawa, Ontario, Canada

Dr. Hurteau-Miller is an assistant professor at the Children's Hospital of Eastern Ontario. She completed medical school and a residency in radiology at the Université de Sherbrooke. She completed a fellowship in pediatric radiology in 1998, including six months of pediatric neuroradiology at the University of California, Los Angeles (UCLA) and the Children's Hospital Los Angeles. For two years, she was a practising pediatric radiologist at The Montreal Children's Hospital. Dr. Hurteau-Miller's special interests are pediatric neuroradiology, neonatal imaging and fetal MRI.

PRESENTATION

- Senior Hot Seat Session for Residents, Pg 59

JOÃO R. INÁCIO, MD

The Ottawa Hospital, University of Ottawa, Ottawa, Ontario, Canada

Dr. Inácio is a cardiothoracic radiologist at The Ottawa Hospital Department of Medical Imaging, Chest, Cardiac and Emergency sections, and has been an assistant professor of Radiology at the University of Ottawa since 2011. He was born and raised in Lisbon, Portugal, and graduated from the University of Lisbon Medical School. Dr. Inácio completed a residency in radiology at the Hospital de Santa Maria/University of Lisbon; he was a radiologist at the Hospital de Santa Maria and assistant professor of Radiology at the University of Lisbon. He completed a mini-fellowship in cardiovascular CT and MR at the University of California at Los Angeles (UCLA) Radiology Department, Diagnostic Cardiovascular Section, clinical fellowships in emergency/trauma radiology and cardiothoracic imaging at the University of British Columbia, Vancouver General Hospital. Dr. Inácio received the American College of Radiology Cardiac CT Certificate of Advanced Proficiency (CoAP) and Diplomate of Certification Board of Cardiovascular Computed Tomography (CBCCT). His areas of interest include interstitial lung disease, mechanisms of lung cancer spread, chest intervention and CT myocardial perfusion.

PRESENTATION

- Resident Review: Thoracic Imaging | Cardiac CT: Beyond the Coronary Arteries, Pg 56

SIMULATION WORKSHOP

- HRCT of the Chest: A Hands-on Practical Workshop of Diffuse Lung Disease | Cystic Lung Diseases and Emphysema, Pg 50

ZAHRA KASSAM, MD

Western University, London, Ontario, Canada

Dr. Kassam is an assistant professor of Radiology and Oncology at the Schulich School of Medicine, Western University. She graduated from the Western Radiology Residency Program in 2006, and Stanford University in 2007, after completing a fellowship in body imaging. Dr. Kassam has keen clinical interests in oncologic imaging, particularly gastrointestinal and gynecologic malignancies. She plays an active role in guideline development and quality improvement, collaborating frequently with clinical colleagues. She serves as the Southwest Regional Imaging Lead and Colorectal Cancer Champion for Cancer Care Ontario, and is the Director of MRI at St. Joseph's Health Care, London. Dr. Kassam is also an associate scientist at the Lawson Research Institute, and is currently involved in numerous cancer imaging clinical trials, including hybrid imaging/PET-MRI of rectal and prostate cancer. She is a member of the Educational Exhibit Committee of the RSNA, and the Disease Focused Panel on Rectal Cancer, Society of Abdominal Radiology.

PRESENTATION

- Radiology Care: A Value Driven Approach (GU/GI) | Bottoms Up! Pitfalls and Pearls in Rectal MRI: What the Radiologist Needs to Know in 2017, Pg 42

VALERIE J. KEOUGH, MD, FRCPC

Queen Elizabeth II Health Sciences Centre, Dalhousie University, Halifax, Nova Scotia, Canada

Dr. Keough is an assistant professor of Radiology at Dalhousie University and abdominal radiologist at the QEII Health Sciences Centre in Halifax. Following a residency at Dalhousie University, Dr. Keough completed a fellowship in abdominal radiology at the University of Toronto. Dr. Keough has a special interest in hepatopancreaticobiliary and multiorgan transplantation imaging. In addition to clinical and teaching commitments, Dr. Keough is a past president of the Nova Scotia Association of Radiologists, an invited speaker and judge at CAR Annual Scientific Meetings, and prior CAR working group member.

CONTEST JUDGE

- Educational Exhibits, Pg 64

FAISAL KHOSA, MD, MBA, FFRRCSI, FRCPC

Vancouver General Hospital, Vancouver, British Columbia, Canada

Dr. Khosa is a radiologist at the Vancouver General Hospital, University of British Columbia. He is the recipient of the CAR/CRF Leadership scholarship in 2017. Dr. Khosa and his ER team received the Outstanding Support Award from the Vancouver General Hospital Trauma Program in 2016. Dr. Khosa has also received numerous educational, clinical service and research awards, including the American Roentgen Ray Scholarship (2013–16), the Outstanding Young Investigator Award (2015), and the One in One Hundred Mentor Award (2014). He received the Medal of Excellence ("Tamgha-i-Imtiaz") from the Government of Pakistan and The College of Physicians and Surgeons Award for 15 years of Outstanding Service to Medicine in Pakistan. Dr. Khosa is board-certified in Radiology in the U.S., Canada and Europe. He completed an MBA with a major in leadership. His academic interests include mentoring, leadership and imaging in the acute care setting.

PRESENTATION

- Mistakes We All Make | Emergency Radiology, Pg 61

CONTEST JUDGE

- CAR Radiologists-in-Training Contest, Pg 86

IAIN D. KIRKPATRICK, BSc (Med), MD, FRCPC, DABR, FSAR

University of Manitoba, Winnipeg, Manitoba, Canada

Dr. Kirkpatrick is an associate professor and Section Head of Abdominal Imaging at the University of Manitoba, and Director of Computed Tomography, Radiography, and Interventional Radiology at St. Boniface General Hospital in Winnipeg. He completed a residency in radiology at the University of Manitoba, and a fellowship in abdominal imaging at Stanford University, where he remained as an adjunct faculty member until 2012.

PRESENTATION

- Radiology Care: A Value-Driven Approach (GU/GI) | PI-RADS V2: What You Need to Know, Pg 42

MODERATOR

- Radiology Care: A Value-Driven Approach (GU/GI), Pg 42

MARIO KONTOLEMOS, MD CM, MSc, FRCPC

The Ottawa Hospital, University of Ottawa, Ottawa, Ontario, Canada

Originally from Montreal, Dr. Kontolemos completed medical school training and a residency in radiology at McGill University in 2011, followed by a fellowship in diagnostic neuroradiology at the University of Ottawa, where he is practicing in a tertiary-care setting. His main clinical interests are stroke and CNS tumour imaging as well as head and neck imaging. In parallel, he maintains a strong passion for medical education with ongoing active involvement in the radiology resident training program in Ottawa.

PRESENTATION

- Post-Residency Panel | Preparing For Your First Year Out of Residency: Tips and Tricks, Pg 51

JONATHON A. LEIPSIC, MD, FRCPC FSCCT

University of British Columbia, Vancouver, British Columbia, Canada

Dr. Leipsic is Chairman of the Providence Health Care Research Institute Department of Radiology and Vice Chairman of Research for the University of British Columbia Department of Radiology. He is an associate professor of Radiology and Cardiology at the University of British Columbia. Dr. Leipsic is also Canada Research Chair in Advanced Cardiopulmonary Imaging. Dr. Leipsic has over 300 peer-reviewed manuscripts in press or in print, over 250 scientific abstracts, and is editor of two textbooks. He speaks internationally on a number of cardiopulmonary imaging topics with over 120 invited lectures in the last four years. He is President of the Society of Cardiovascular Computer Tomography, the largest international society dedicated to cardiac CT, and Chair of the CAR 80th Annual Scientific Meeting.

PRESENTATION

- Special Presentation: 80 Years of CAR, Pg 34

MARK LEVENTAL, FRCPC

McGill University, Montreal, Quebec, Canada

Dr. Levental is an associate professor of Radiology at McGill University. He is Chief of the Jewish General Hospital Department of Radiology in Montreal. Dr. Levental completed medical school training at McGill University in 1988, then a residency in family medicine followed by a residency in diagnostic radiology at McGill University. Dr. Levental completed a fellowship in abdominal imaging at the University of California in San Diego in 1996. He has been an examiner with the Royal College of Physicians and Surgeons of Canada since 2005. Dr. Levental has special interests in abdominal imaging as well as neuro/ENT imaging.

CONTEST JUDGE

- CAR Radiologists-in-Training Contest, Pg 86

MODERATOR

- Controversies in Radiology, Pg 55

MARIE-HÉLÈNE LÉVESQUE, MD, FRCPC

Institut universitaire de cardiologie et de pneumologie de Québec, Quebec, Quebec, Canada

Dr. Lévesque is a radiologist at the Institut universitaire de cardiologie et de pneumologie de Québec, Université Laval. She completed her medical school training and a residency in diagnostic radiology at Université Laval, and a fellowship in thoracic and cardiac imaging at Massachusetts General Hospital in Boston.

PRESENTATION

- Junior Hot Seat Session for Residents, Pg 59

CHRIS M. LINDQUIST, BSc, BSc (Med), MD, FRCPC

Health Sciences Centre, University of Manitoba, Winnipeg, Manitoba, Canada

Dr. Lindquist is an abdominal radiologist at the Health Sciences Centre, University of Manitoba, and a lecturer at the University of Manitoba Department of Radiology. He completed both medical school training and a residency in diagnostic radiology at the University of Manitoba. He then completed an MR-Predominant Body Imaging and Musculoskeletal Fellowship at the Northwestern University Feinberg School of Medicine. He currently practices both abdominal radiology in an academic setting as well as general radiology in several community hospitals in Winnipeg.

PRESENTATION

- Radiology Care: A Value-Driven Approach (GU/GI) | Liver Imaging Reporting and Data System (LI-RADS): What You Need to Know, Pg 42

EDWARD A. LYONS, OC

Health Sciences Centre, University of Manitoba, Winnipeg, Manitoba, Canada

Dr. Lyons is a radiologist at the Health Sciences Centre, University of Manitoba. He is a former professor and Head of Radiology, Obstetrics and Gynecology and Anatomy and past board chair at the Saul & Claribel Simkin Centre. He served as president of numerous local and national organizations, including CAR (2009-11), the Manitoba Association of Radiologists (2004-08), the Society of Radiologists in Ultrasound (1989-90), Congregation Shaarey Zedek (1990-91), and the Jewish Federation of Winnipeg (2005-07). Dr. Lyons has served on numerous Canadian, American and international imaging committees and organizations, written numerous articles, chapters, and books, and lectured on ultrasound around the world. Dr. Lyons was honoured with the Officer of the Order of Canada in 2007, the Queen Elizabeth Diamond Jubilee Medal in 2012, an honorary CMA membership in 2013, and a University of Manitoba Distinguished Alumni Award for a lifetime achievement in 2016.

PRESENTATION

- Employment and Retirement | The Radiologist Was Once an Integral Member of the Health Care Team, Pg 38

MODERATOR

- Employment and Retirement, Pg 38 and 39

THOMAS MAMMEN, MD, FRCPC

Hamilton General Hospital, Hamilton, Ontario, Canada

Dr. Mammen is an assistant professor at McMaster University and a musculoskeletal radiologist at the Hamilton General Hospital. He completed medical school training at the University of Ottawa and a residency in radiology at Dalhousie University. He completed an MSK fellowship at St. Paul's Hospital, University of British Columbia. Dr. Mammen has a keen interest in medical education and recently completed a Masters in Medical Education at the University of Dundee, Scotland.

PRESENTATION

- MSK: Sports Injuries | Not Uncommon Foot and Ankle Diagnoses for the General Radiologist, Pg 44

ERIKA H. MANN, MD, FRCPC, DABR

The Hospital for Sick Children, Oakville, Ontario, Canada

Dr. Mann is an assistant professor at the University of Toronto Department of Medical Imaging and Section Head for GI/ GU Imaging at The Hospital for Sick Children. She completed medical school training at Queen's University in Kingston in 1998, followed by a residency in radiology at the University of Toronto, and a fellowship in pediatric radiology at The Hospital for Sick Children in 2005, joining as staff afterward. She holds certification in pediatric radiology from the American Board of Radiology. Dr. Mann has interest in international pediatric radiology development, inflammatory bowel disease and quality improvement initiatives. Her present work is in pediatric general and body imaging.

PRESENTATION

- Radiology Care: A Value-Driven Approach (Thoracic) | The Radiologist: Art Critic or Consultant in Patient Care? Pg 40

DARIA MANOS, MD, FRCPC

Dalhousie University, Halifax, Nova Scotia, Canada

Dr. Manos is an associate professor of Medicine at Dalhousie University, Head of Thoracic Radiology at the QEII Health Sciences Centre in Halifax, and Co-chair of the Cardiothoracic Fellowship Program at Dalhousie University. She obtained a Bachelor of Arts from McGill University in 1996, then completed medical school training and a residency in radiology at Dalhousie University, where she also served as chief resident. She completed a fellowship in thoracic radiology at Vancouver General Hospital in 2007. A regular lecturer for the largest radiology CME meetings in North America, Dr. Manos has received many teaching awards including for digital, interactive and print-based educational resources.

PRESENTATION

- Resident Review: Thoracic Imaging | Diffuse Air Space Disease, Pg 56

SIMULATION WORKSHOP LEADER

- HRCT of the Chest: A Hands-on Practical Workshop of Diffuse Lung Disease, Pg 50

SIMULATION WORKSHOP

- HRCT of the Chest: A Hands-on Practical Workshop of Diffuse Lung Disease | Diffuse Abnormalities of Lung Density, Pg 50

CAITLIN T. McGREGOR, MD, FRCPC

Sunnybrook Health Sciences Centre, University of Toronto, Toronto, Ontario, Canada

Dr. McGregor was born in Fredericton, raised in Calgary, and completed her post secondary education in Ontario. Dr. McGregor is a practising radiologist in abdominal imaging, Head of the Ultrasound Department, and a member of the Quality Improvement Committee at Sunnybrook Health Sciences Centre. She earned an Honours Co-op Bachelor of Science in Biochemistry from the University of Waterloo and a medical degree from the University of Toronto. Dr. McGregor completed a residency in radiology at the University of Toronto, followed by a fellowship in abdominal imaging at Sunnybrook Health Sciences Centre.

MODERATOR

- Mistakes We All Make, Pg 61

MATTHEW D. McINNES, MD, FRCPC

The Ottawa Hospital, University of Ottawa, Ottawa, Ontario, Canada

Dr. McInnes is an associate professor at the University of Ottawa and Director of the Diagnostic Radiology Residency Program. He is a radiologist at The Ottawa Hospital Department of Medical Imaging, Abdominal and Chest Radiology divisions, and a clinical investigator in The Ottawa Hospital Research Institute (OHRI) Clinical Epidemiology program. He is deputy editor for the Journal of Magnetic Resonance Imaging and associate editor for Radiology, both in the area of evidence-based practice. He completed radiology training at the University of Toronto in 2006, followed by a one-year clinical fellowship in abdominal imaging at the University of Toronto University Health Network. He holds a cross appointment in the School of Epidemiology, Public Health and Preventive Medicine at the University of Ottawa. Dr. McInnes' current areas of research interest are systematic reviews and diagnostic test accuracy in imaging.

PRESENTATION

- Development of Academic Life I How to Optimize Research Publication Probability! Pg 46

BRUNO MORIN, MD, FRCPC

Cité de la Santé de Laval and Université de Montréal, Sainte-Thérèse, Québec, Canada

Dr Morin est radiologiste en chef à la Cité de la Santé de Laval depuis 2006, et chargé d'enseignement clinique à l'Université de Montréal depuis 2015. Le Dr Morin a été élu Président de la Société canadienne-française de radiologie en 2014 et actuellement, il est trésorier de la Société de radiologie du Québec. Le Dr Morin est aussi responsable du comité scientifique du centre de simulation de la Société de radiologie du Québec. Diplômé de médecine en 1991 à l'Université Laval, Québec, le Dr Morin a complété sa résidence en radiologie à l'Université de Montréal et obtenu son diplôme de FRCPC en 1996.

MODERATOR

- Departmental Clinical Audit Projects Contest, Pg 81

PETER L. MUNK, MDCM, FSIR

Vancouver General Hospital, Vancouver, British Columbia, Canada

Dr. Munk is a professor of Radiology, Orthopedics and Palliative Care at the University of British Columbia and Head of MSK Imaging at the Vancouver General Hospital. Dr. Munk is also editor in chief of the CARJ, associate editor of the *British Journal of Radiology*, and author of four books and 400 papers. He is a graduate of McGill Medical School and a fellow in Musculoskeletal Radiology at the University of California, San Francisco. He is also a fellow of the Society of Interventional Radiology and member of the International Skeletal Society.

PRESENTATION

- Development of Academic Life I A Primer on Effective Abstract Writing, Pg 46

ELSIE T. NGUYEN, MD, FRCPC

University of Toronto, Toronto, Ontario, Canada

Dr. Nguyen is an assistant professor in the Cardiothoracic Division at the Toronto General Hospital, University of Toronto. Dr. Nguyen completed a thoracic imaging fellowship at the University of British Columbia where she learned the original microcoil technique from Dr. John Mayo in 2006. She then completed a cardiovascular fellowship at Stanford University in 2007. She has developed a simplified microcoil localization technique and has completed hundreds of microcoil localizations since 2008 with a 99% complete resection rates.

PRESENTATION

- Radiology Care: A Value-Driven Approach (Thoracic) | Pre-Operative CT-Guided Microcoil Lung Nodule Localization: Our Added Value, Pg 40
- The Challenges and Opportunities in Undergraduate Medical Education | National Radiology Curriculum for Undergraduate Medicine, Pg 41

SAVVAS NICOLAOU, MD

University of British Colombia, Vancouver, British Columbia, Canada

Dr. Nicolaou is Director of Emergency and Trauma Imaging at the Vancouver General Hospital and a professor at the University of British Columbia. At the Faculty of Medicine, he is Director of Undergraduate Radiology Education, where he has helped to integrate radiology into the curriculum. He earned a medical degree from the University of Toronto and completed a residency in diagnostic radiology at the University of British Columbia. Dr. Nicolaou is actively involved in teaching and mentoring medical students, residents and fellows. Dr. Nicolaou continues to contribute to the field of emergency radiology, having published over 100 articles and abstracts in peer-reviewed journals. The major focus of his research is on ultra-low dose techniques in the acute setting, dual-energy CT in the acute setting, polytrauma imaging, brain perfusion in trauma and the role of MRI in the acute setting.

PRESENTATION

- Radiology Care: A Value-Driven Approach (Emergency Radiology) | Role of the ER Section in a Radiology Department, Pg 45

TIMOTHY O'CONNELL, MEng, MD

Vancouver General Hospital, Vancouver, British Columbia, Canada

Dr. O'Connell is an emergency and trauma radiologist at the Vancouver General Hospital. He is also Director of the Imaging Informatics Fellowship at the University of British Columbia. He completed a residency at the University of British Columbia and a fellowship in emergency and trauma radiology and imaging informatics at Brigham & Women's Hospital, Harvard Medical School. His interests include emergency radiology workflow, dual-energy CT, and quantitative imaging.

PRESENTATION

- Radiology Care: A Value-Driven Approach (Emergency Radiology) | Differentiation of Bowel Ischemia, Pg 45

ANASTASIA OIKONOMOU, MD, PhD, FSCCT

Sunnybrook Health Sciences Centre, University of Toronto, Toronto, Ontario, Canada

Dr. Oikonomou is a cardiothoracic radiologist, Head of the Cardiothoracic Imaging Division and Director of the Cardiothoracic Imaging Fellowship Program at Sunnybrook Health Sciences Centre. Dr. Oikonomou is an assistant professor at the University of Toronto. She completed medical school training and a residency in radiology at Ippokration Hospital, Aristoteles University in Thessaloniki, Greece, and a doctoral thesis at Democritus University of Thrace, Greece. She completed fellowships in thoracic imaging at Royal Brompton in London, England, thoracic imaging and body MRI at The Ottawa Hospital, research fellowships in thoracic imaging at the Vancouver General Hospital, and in cardiac imaging at the University of Ottawa Heart Institute. Dr. Oikonomou became a fellow of the Society of Cardiac Computed Tomography (FSCCT) in 2013. Dr. Oikonomou was also a lecturer and assistant professor of Radiology at the Democritus University of Thrace Department of Medical Imaging, Greece (2003–13).

SIMULATION WORKSHOP

- HRCT of the Chest: A Hands-on Practical Workshop of Diffuse Lung Disease | Diseases with Nodular Pattern, Pg 50

EMILY PANG, MD

Vancouver General Hospital, Vancouver, British Columbia, Canada

Dr. Pang is an abdominal radiologist at the Vancouver General Hospital. She completed a residency in radiology at the University of Toronto and a fellowship in abdominal imaging at the Vancouver General Hospital.

CONTEST JUDGE

- Scientific Exhibits, Pg 74

MICHAEL N. PATLAS, MD, FRCPC

McMaster University, Hamilton, Ontario, Canada

Dr. Patlas is Professor of Radiology and Chief of the Emergency/Trauma Division at McMaster University. Dr. Patlas is a member of the CAR Annual Scientific Meeting Working Group, the RSNA Scientific Program Committee, and the ARRS and RadioGraphics Subspecialty Panel for Trauma/Emergency Radiology. He is an editorial board member of *Current Problems in Diagnostic Radiology* and *Annals of Clinical & Laboratory Science*, and a reviewer for nine journals. His main research interests include imaging of traumatic and non-traumatic abdominal emergencies. He has authored 138 peer-reviewed papers, chapters and abstracts. He received multiple accolades for his research and clinical activities including a Young Investigator Award from the CAR, the Hamilton Health Sciences Medical Staff Association President's Award for Distinguished Service, and six awards from the RSNA.

PRESENTATION

- Controversies in Radiology I Imaging of the Acute Abdomen: Oral Contrast a Must, Pg 55

MODERATOR

- Controversies in Radiology, Pg 55

ELENA PEÑA, MD

The Ottawa Hospital, University of Ottawa, Ottawa, Ontario, Canada

Dr. Peña is a cardiothoracic radiologist at The Ottawa Hospital Department of Medical Imaging, and assistant professor of Radiology at the University of Ottawa. She is Director of the Cardiac Radiology Fellowship Program and resident supervisor for the cardiac radiology rotation. She is involved in medical student, resident and fellow teaching. She was co-director for the past CME course entitled "Cardiopulmonary Imaging Update" held in 2013 in Quebec City. She has been a lecturer at the Resident Review course, held in Ottawa in March every year since 2010. She has published several peer-reviewed articles and two book chapters, and given over 30 oral presentations and posters at national and international meetings. Her primary clinical interest is in cardiopulmonary imaging. Her major research interests are in pulmonary vascular diseases, cardiomyopathies and atrial fibrosis imaging.

PRESENTATION

- Resident Review: Thoracic Imaging I How Do I Approach Cardiac MR?, Pg 53
- Mistakes We All Make I Making the Black Box of the Heart More Transparent, Pg 62

ANDRÉ PICARD

The Globe and Mail, Toronto, Ontario, Canada

André Picard is the health columnist at The Globe and Mail and the author of four books, most recently The Path to Health Care Reform: Policies and Politics. He has received much acclaim for his writing, including the Michener Award for Meritorious Public Service Journalism and the Centennial Prize of the Pan-American Health Association, awarded to the top health journalist in the Americas. He is also an eight-time finalist for the National Newspaper Awards – Canada's version of the Pulitzer Prize. André is a graduate of the University of Ottawa and Carleton University, and has received honourary doctorates from the University of Manitoba and the University of Ontario Institute of Technology.

MODERATOR

- CAR Hot Topics, Pg 57

TINO D. PISCIONE, MD, PhD, FRCSC

Canadian Medical Protective Association (CMPA), Ottawa, Ontario, Canada

Dr. Piscione is a physician advisor in practice improvement with the Canadian Medical Protective Association (CPMA). Prior to joining the CMPA in 2014, Dr. Piscione was paediatric nephrologist and clinician-scientist at The Hospital for Sick Children Department of Paediatrics in Toronto, and assistant professor of Paediatrics at the University of Toronto. Dr. Piscione earned a medical degree from Queen's University in 1991. He subsequently completed a residency in paediatrics and a fellowship in paediatric nephrology at The Hospital for Sick Children in 1996. At The Hospital for Sick Children, Dr. Piscione was associate, and subsequently, head program director of the Paediatric Nephrology Residency Training Program at the University of Toronto. Having completed the Patient Safety & Quality Improvement Certificate Program at the University of Toronto, Dr. Piscione is keenly interested and involved in the design and development of educational content on safety and quality at CMPA.

PRESENTATION

- Employment and Retirement I Speaking Out or Being Outspoken: The Difference Between Responsible and Disruptive Behaviour in Radiology, Pg 39
- Plenary Session: CMPA — Mobile Device Use in Clinical Practice: Opportunities and Realities, Pg 61

TOM POWELL, MB, BCh, BAO, FFR RCSI

McGill University Health Centre, Montreal, Quebec, Canada

Dr. Powell was born in Dublin, Ireland. He has been an assistant professor at McGill University and a musculoskeletal radiologist at the McGill University Health Centre (Montreal General, Royal Victoria and Montreal Children's sites) for the past 12 years. He attended medical school at University College, Dublin, and completed radiology training at the Faculty of Radiology at the Royal College of Surgeons in Dublin. He completed a fellowship in thoracic radiology at the University of British Columbia and a fellowship in musculoskeletal imaging at the University of Toronto. His areas of interest include musculoskeletal interventional radiology and imaging of sports injury, musculoskeletal oncology, inflammatory disease and trauma.

PRESENTATION

- MSK: Sports Injuries | Current Concepts: Imaging the Shoulder and Elbow in Athletes, Pg 44

FRANCESCA PROULX, MD CM, FRCPC, DABR

McGill University Health Centre, Montreal, Quebec, Canada

Dr. Proulx is an assistant professor with the Radiology Residency Program at McGill University, and Chief of the Breast Centre at the Jewish General Hospital. She completed medical school training and a residency at McGill University. She completed a fellowship in women's imaging at the Beth Israel Deaconess Medical Center, Harvard Medical School in Boston, and in thoracic imaging at the Centre hospitalier de l'Université de Montréal (CHUM). Dr. Proulx's clinical and research interests include women's and thoracic imaging, 3D tomosynthesis, breast MRI and breast imaging education.

CONTEST JUDGE

- Scientific Exhibits, Pg 74

KHASHAYAR RAFATZAND, MD, FRCPC

Lakeshore General Hospital, Montreal, Quebec, Canada

Dr. Rafatzand is an assistant professor of Radiology and Director of Body MRI at the University of Massachusetts, where he has been proctoring a course on body MRI and MRI physics for the past three years. He completed a residency in radiology at McGill University, followed by a fellowship in body MRI at Beth Israel Deaconess Medical Center, Harvard Medical School. He has academic affiliation with McGill University as an adjunct professor of Radiology, and practices at Lakeshore General Hospital. Dr. Rafatzand has served on multiple national and international radiology society committees including CAR, the Society of Computed Body Tomography & Magnetic Resonance (SCBTMR) and the International Society for Magnetic Resonance in Medicine (ISMRM). He holds a certificate of leadership proficiency from the American College of Radiology. He is a reviewer for ISMRM Journal and Radiology. His current interests and research activities focus on MR economics, dynamic MRI of ventral hernias, radiation protection and virtual reality. This is his first CAR Annual Scientific Meeting invited lecture.

PRESENTATION

- Advanced Technologies: CT | Latest Advancements in CT Scan Technology, Pg 49

MODERATOR

- Advanced Technologies: CT, Pg 49

KAWAN S. RAKHRA, MD, FRCPC

The Ottawa Hospital, University of Ottawa, Ottawa, Ontario, Canada

Dr. Rakhra is Head of the Musculoskeletal Imaging Section at The Ottawa Hospital Department of Medical Imaging, and an associate professor in the Department of Radiology with cross appointment to the Division of Orthopaedic Surgery. His main clinical interests and research endeavours focus on hip disease including femoroacetabular impingement (FAI), advanced cartilage MRI techniques and sports medicine.

PRESENTATION

- Controversies in Radiology | Controversies in Femoroacetabular Impingement, Pg 55

JEAN RAYMOND, MD, FRCPC

Centre hospitalier de l'Université de Montréal (CHUM), Montreal, Quebec, Canada

Dr. Raymond is a neuroradiologist, Director of the Interventional Neuroradiology Research (INR) Laboratory, and professor at the Université de Montréal Department of Radiology. He leads the INR Laboratory at the Centre hospitalier de l'Université de Montréal (CHUM) with equal measures of innovation, hard work and probity. Dr. Raymond's achievements include establishing the CHUM's centre for neuro-endovascular treatment; serving as principal investigator on several multi-centre clinical trials; publishing over 200 articles in peer-reviewed journals; teaching countless students and trainees at all levels, several of which are now making their own mark in the field. Dr. Raymond organized the World Federation of Interventional and Therapeutic Neuroradiology Congress in 2009. He will persevere in promoting the necessary research care reconciliation, to eventually provide verifiable care in real time to all patients. He was presented with the 2015 CAR Gold Medal Award.

PRESENTATION

- Radiology Care: A Value-Driven Approach (Neuro) | Values Need Connections to Reality: The Role of Research in Clinical Care, Pg 36

JEREMY REMPEL, MD, FRCPC

University of Alberta, Edmonton, Alberta, Canada

Dr. Rempel is an interventional and diagnostic neuroradiologist at the University of Alberta. He completed medical school at the University of Manitoba in 2004, followed by a residency in diagnostic radiology at Memorial University in St. John's in 2009. Dr. Rempel then completed a fellowship in interventional and diagnostic neuroradiology at the University of Toronto in 2012.

PRESENTATION

- Imaging Complications of Oncological Therapy and MR Elastography | Oncology Complications in Neuroradiology, Pg 52

GISELLE REVAH, BASc, MD, FRCPC

University of Ottawa, Ottawa, Ontario, Canada

Dr. Revah is an assistant professor at the University of Ottawa Department of Radiology, and practices clinical cardiothoracic imaging, non-vascular thoracic interventions and clinical abdominal imaging. She completed a residency at the University of Toronto, a fellowship in abdominal imaging and interventions at Beth Israel Deaconess Medical Center, Harvard University Medical School, and a fellowship in cardiothoracic imaging at New York University. Dr. Revah has many diverse research interests and has presented her research at national and international conferences.

PRESENTATION

- Resident Review: Thoracic Imaging | The Mediastinum, Pg 56

LARA RICHMOND, BSc, MD

Sunnybrook Health Sciences Centre, University of Toronto, Toronto, Ontario, Canada

Dr. Richmond is a radiologist in the Breast Imaging Division at Sunnybrook Health Sciences Centre, University of Toronto. She completed a fellowship in abdominal imaging at the Joint Department of Medical Imaging (Mount Sinai Hospital, University Health Network and Women's College Hospital) following medical school training and a residency in radiology at the University of Toronto.

PRESENTATION

- Breast Imaging | Breast MRI: Recent Advances, Pg 58

FRANK J. RYBICKI, MD, PhD

The Ottawa Hospital, University of Ottawa, Ottawa, Ontario, Canada

Dr. Rybicki is Professor and Chair of Radiology at the University of Ottawa, and Chief of Medical Imaging at The Ottawa Hospital. Dr. Rybicki introduced wide-area detector CT to radiology globally in 2007; since its adoption, the technology has become a medical standard for appropriate patient care. Dr. Rybicki is a recognized leader in medical 3D printing and currently serves as president of the Radiological Society of North America Special Interest Group on 3D printing, and editor in chief of *3D Printing in Medicine*.

PRESENTATION

- Advanced Technologies: Novel Technologies | The Role of the Radiologist in 3D Printing, Pg 54

MODERATOR

- Advanced Technologies: Novel Technologies, Pg 54

KARL SAYEGH, MD

McGill University Health Centre, Montreal, Quebec, Canada

Dr Sayegh is currently an assistant professor of radiology at McGill University and the director of Cardiothoracic Imaging and director of the Cardiac Imaging fellowship program at McGill University Health Center. Dr. Sayegh attended medical school at the University of Montreal followed by a diagnostic radiology residency at McGill University in Montreal. Dr Sayegh then completed a fellowship in Abdominal Imaging and Intervention at the Brigham and Women Hospital and also a fellowship in Cardiothoracic Imaging at the Massachusetts General Hospital, where he also served as a Clinical Assistant in radiology. He then completed an additional fellowship in Cardiac Imaging at the Baptist Cardiac and Vascular Institute. Dr Sayegh's main interests are in the field of cardiothoracic imaging and include assessment of coronary artery disease by cardiac CT, Cardiac CT in acute chest pain, cardiomyopathy assessment by MRI and evaluation of adult congenital heart disease.

PRESENTATION

- Advanced Technologies: CT | Recent Advancement in Cardiac CT, Pg 49

JONATHAN A. SCHESKE, MD

Kelowna General Hospital, University of British Columbia, Kelowna, British Columbia, Canada

Dr. Scheske grew up in the outdoors of the Okanagan Valley. Dr. Scheske practices general and cardiovascular radiology at the Kelowna General Hospital and is a clinical instructor at the University of British Columbia. Following university, medical school training and a residency in radiology at the University of British Columbia, he completed a fellowship in advanced cardiac imaging at the Massachusetts General Hospital in Boston.

PRESENTATION

- Post-Residency Panel | Preparing For Your First Year Out of Residency: Tips and Tricks, Pg 51
- Resident Review: Thoracic Imaging | Game-Changing Cardiac Cases, Pg 53
- Senior Hot Seat Session for Residents, Pg 59

JEAN M. SEELY, MD

The Ottawa Hospital, University of Ottawa, Ottawa, Ontario, Canada

Dr. Seely is Head of Breast Imaging at The Ottawa Hospital Department of Medical Imaging and the Women's Breast Health Centre in Ottawa, and associate professor of Medicine at the University of Ottawa. She is Regional Breast Imaging Lead for the Ontario Breast Screening Program in the Champlain region. She established the Breast MRI program in Ottawa in 2001. She is a specialist in breast and chest disease, and has published over fifty articles and chapters in breast MRI, screening mammography and interventions for diagnosis of breast and lung cancer. She is working to reduce the mortality and morbidity of breast cancer and providing high-quality breast imaging nationally and internationally. Dr. Seely is a member of CAR's Breast Imaging Working Group and the CAR Mammography Accreditation Program Board of Directors.

PRESENTATION

- Breast Imaging | Radioactive Seed Localization: Practical Tips for Starting the Program, Pg 58

MODERATOR

- Breast Imaging, Pg 58

JAI J. SHANKAR, MD, DM, MSc

QEII Health Sciences Centre, Dalhousie University, Halifax, Nova Scotia, Canada

Dr. Shankar is an associate professor of Neuroradiology at the QEII Health Sciences Centre Department of Diagnostic Imaging, Dalhousie University, with cross appointment to neurosurgery in the Department of General Surgery. He is a consultant neuroradiologist at the IWK Health Centre (pediatric hospital) Department of Radiology in Halifax. In recognition of his contribution to research in the field of radiology, he received the Dalhousie University Dr. Charles Lo Prize in Radiology Research in 2013, and the CAR Young Investigator Award in 2014. Through distance learning, Dr. Shankar will be completing a Master of Science (MSc) Epidemiology from the London School of Hygiene & Tropical Medicine, University of London, England in the fall of 2017. He has over 60 publications in peer-reviewed journals and has participated in over 100 presentations in national and international conferences.

PRESENTATION

- Radiology Care: A Value-Driven Approach (Neuro) | Imaging in Brain Death, Pg 36

MODERATOR

- Radiology Care: A Value-Driven Approach (Neuro), Pg 36

ADNAN M. SHEIKH, MD

The Ottawa Hospital, University of Ottawa, Ottawa, Ontario, Canada

Dr. Sheikh is an associate professor of Radiology at the University of Ottawa, as well as Medical Director of 3D Printing, Section Head and Fellowship Director of Emergency Radiology at The Ottawa Hospital. Dr. Sheikh is Radiology Lead for The Marrow Study on Astronauts at the International Space Agency, sponsored by the Canadian Space Agency and NASA. In addition, Dr. Sheikh is associate editor of *3D Printing in Medicine*. Dr. Sheikh completed medical school and radiology specialist training in India, and fellowships in musculoskeletal imaging and emergency trauma imaging at the University of British Columbia before coming on staff at The Ottawa Hospital in 2005. His clinical interests are personalized, patient-specific 3D printing, marrow imaging, functional musculoskeletal imaging, bone and soft tissue tumour imaging, musculoskeletal intervention and emergency/trauma imaging.

MODERATOR

- Radiology Care: A Value-Driven Approach (Emergency Radiology), Pg 45

LISA SMYTH, BSc, MD, FRCPC, ABR

St. Clare's Mercy Hospital, St. John's, Newfoundland, Canada

Dr. Smyth is a diagnostic radiologist at St. Clare's Mercy Hospital and practices general radiology, with subspecialties in thoracic and breast imaging, being the Chief of service of Thoracic Imaging. She completed a fellowship at The Ottawa Hospital, University of Ottawa. With a keen interest in imaging-guided procedures, Dr. Smyth teaches at the Memorial University Medical School, as well as in the Diagnostic Radiology residency program.

PRESENTATION

- Post-Residency Panel | Preparing For Your First Year Out of Residency: Tips and Tricks, Pg 51
- Resident Review: Thoracic Imaging | The Chest X-Ray: What You Need to Know, Pg 53

CAROLINA A. SOUZA, MD, PhD

The Ottawa Hospital, University of Ottawa, Ottawa, Ontario, Canada

Dr. Souza is a thoracic radiologist, Thoracic Imaging Fellowship Director at The Ottawa Hospital, and associate professor at the University of Ottawa. Dr. Souza is originally from Brazil where she obtained her medical degree. In 2004, she completed a residency in radiology and was accepted for a two-year fellowship in thoracic imaging at the Vancouver General Hospital under the supervision of Dr. Nestor Müller. During her first year as a research fellow, Dr. Souza completed several research projects that were published in renowned peer-reviewed journals. In 2006, she obtained her Ph.D. in radiology from the University of Rio de Janeiro, Brazil. Dr. Souza has been actively involved in teaching, research and multidisciplinary patient care at The Ottawa Hospital since completing a clinical fellowship in 2006. In 2016, she established the Healthcare Education Scholars Program (HESP), Department of Innovation in Medical Education (DIME) at the University of Ottawa, a one-year program dedicated to scholarship in medical education. Her main areas of interest include interstitial and diffuse lung diseases, advances in lung cancer and medical education.

SIMULATION WORKSHOP LEADER

- HRCT of the Chest: A Hands-on Practical Workshop of Diffuse Lung Disease, Pg 50

SIMULATION WORKSHOP

- HRCT of the Chest: A Hands-on Practical Workshop of Diffuse Lung Disease | Fibrotic Interstitial Lung Diseases, Pg 50

NING SU, MD, PhD

Memorial University of Newfoundland, St. John's, Newfoundland, Canada

Dr. Su is a junior resident in the Discipline of Radiology at Memorial University of Newfoundland. After attending Memorial University as an undergraduate, Dr. Su completed a doctoral degree in basic science at the University of Toronto before pursuing his true passion in medicine. While in medical school, he was amazed by the technical aspects and potential patient impact of radiology and decided to pursue a residency in that field. Dr. Su is also an enthusiastic researcher, with interests in chest and abdominal imaging. In his spare time, he enjoys writing about himself in the third person immensely, listening to Johnny Cash, and causing mass confusion among the nursing staff by referring to himself using his last name.

PRESENTATION

- The Challenges and Opportunities in Undergraduate Medical Education | Radiology Electives: Strategies to Improve the Student Experience, Pg 41

AN TANG, MD, MSc, FRCPC

Université de Montréal, Montreal, Quebec, Canada

Dr. Tang is an associate professor of Radiology at the Université de Montréal. He earned a specialty degree in Radiology at the Université de Montréal in 2005, and completed a fellowship in abdominal imaging at the University of Toronto in 2006. That same year, Dr. Tang joined the team of radiologists at the Centre hospitalier de l'Université de Montréal (CHUM). Supported by fellowship awards from the Fulbright Program and the Canadian Institutes of Health Research, he completed a research fellowship in liver magnetic resonance imaging at the University of California, San Diego in 2011–12. He currently has active research funding from the Canadian Institutes of Health Research and MedTEQ. His current research interest is focused on imaging biomarkers of chronic liver disease and detection of liver cancer using artificial intelligence techniques.

PRESENTATION

- Development of Academic Life | Tips to Obtain a First Peer-Review Research Grant, Pg 46
- Imaging Complications of Oncological Therapy and MR Elastography | Liver Magnetic Resonance Elastrography: Concepts and Applications, Pg 52

MODERATOR

- Development of Academic Life, Pg 46

MARIE-MICHÈLE THÉRIAULT, MD

Université de Sherbrooke, Sherbrooke, Quebec, Canada

Dr. Thériault is an adjunct professor at the Université de Sherbrooke Department of Radiology. She completed a residency in radiology at the Université de Sherbrooke and a fellowship in cardiothoracic imaging at Dalhousie University.

SIMULATION WORKSHOP

- HRCT of the Chest: A Hands-on Practical Workshop of Diffuse Lung Disease | Diseases with Nodular Pattern, Pg 50

R. PETTER TONSETH, MD

University of British Columbia, Vancouver, British Columbia, Canada

Dr. Tonseth is a radiologist at the British Columbia Cancer Agency Department of Functional Imaging. He obtained a Bachelor of Science in biology from the University of Victoria in 1984, then completed medical school training at the University of British Columbia and a rotating internship through the Dalhousie program in 1989. He was a general practitioner in many coastal communities in British Columbia until 1999, when the opportunity to enter a residency in radiology at the University of British Columbia brought Dr. Tonseth and his wife back from sailing offshore to Vancouver via Hawaii on their 34-foot sailboat. Dr. Tonseth completed the dual radiology/nuclear medicine program and a residency in 2004, then practised with Night Hawk Radiology Services, providing teleradiology support from Australia to multiple sites across the United States, while also continuing to do locums in various communities in British Columbia, the Northwest Territories, Alberta, and Australia.

PRESENTATION

- The Challenges and Opportunities in Undergraduate Medical Education | Ultrasound in Undergraduate Medical Education: A Tale of Two Programs, Pg 41

CARLOS H. TORRES, MD, FRCPC

The Ottawa Hospital, University of Ottawa, Ottawa, Ontario, Canada

Dr. Torres is an associate professor of Radiology at the University of Ottawa, and has been a practising neuroradiologist at The Ottawa Hospital since 2008. He joined The Ottawa Hospital Department of Diagnostic Imaging after completing a two-year fellowship in neuroradiology at McGill University. Dr. Torres has been director and co-director of more than a dozen CME courses in Europe, North America and Latin America, and is currently chair of the International Scientific Committee for the Ibero Latin American Society of Neuroradiology (SILAN). He is associate editor of *3D Printing in Medicine* and a member of the editorial board of the RSNA *Daily Bulletin*. Dr. Torres lectures extensively at the national and international levels, and has been invited to speak at RSNA, CAR, ARRS, ASNR, ASSR, ASER and ENRS meetings. He is an international visiting professor for RSNA and for the Inter American College of Radiology. He has been a visiting professor in different academic centres in Canada and abroad, including Brazil, Colombia, El Salvador, Chile, Bhutan, China and Mongolia. Dr. Torres is actively involved in medical education and research. He has contributed to multiple peer-reviewed publications and has written ten book chapters.

PRESENTATION

- Mistakes We All Make | Neuroradiology, Pg 61

DAVID B. VICKAR, MD, BSc, FRCPC

Diagnostic Imaging Services, University of Alberta Hospital, Edmonton, Alberta, Canada

Dr. Vickar is a past president of the CAR and long-time volunteer to the national association. His practice is with Medical Imaging Consultants in Edmonton where he is primarily involved with ultrasound imaging. In recent years, he has gradually decreased his working days with the group practice to allow a graduated transition to "retirement", even at a relatively "young" age. He looks forward to a discussion on the possibilities of lifestyle balance in our complex working environment.

PRESENTATION

- Employment and Retirement | A Radiologist's View of Retirement, Pg 38

VIVEK VIRMANI, MD, DABR

Dr. Everett Chalmers Regional Hospital (DECH), Fredericton, New Brunswick, Canada

Dr. Virmani is a consultant radiologist at Dr. Everett Chalmers Regional Hospital (DECH). He completed fellowships in abdominal imaging and emergency radiology in Ottawa. He has an active interest in teaching and research, with more than fifty publications in peer-reviewed journals.

CONTEST JUDGE

- Scientific Exhibits, Pg 74

CYNTHIA WALSH, MD

The Ottawa Hospital, University of Ottawa, Ottawa, Ontario, Canada

Dr. Walsh is a radiologist at The Ottawa Hospital Department of Medical Imaging, specializing in imaging of the abdomen and pelvis. She completed medical school training at the University of Western Ontario and a residency at The Ottawa Hospital, University of Ottawa. She then completed a one-year fellowship in body imaging at Stanford Hospital, California. She currently lives in Ottawa with her husband and three children.

PRESENTATION

- Advanced Technologies: Novel Technologies | Software Development, Implementation, and Outcomes for Measuring Radiologist Productivity in a Canadian Radiology Department, Pg 54

CADTH Evidence Driven.

Updating the Canadian Medical Imaging Inventory

Map indicates locations of the six modalities included in the study

We need your help

CADTH is currently updating the Canadian Medical Imaging Inventory, and we need your help.

Medical imaging is an important component of modern health care, aiding in diagnosis, monitoring, and treatment of a variety of diseases and conditions from cancer to internal injury.

The Canadian Medical Imaging Inventory captures information on the status and use of medical imaging equipment in Canada.

This information is used to guide decisions in health technology management and policy, and to pave the way for ongoing exploration of medical imaging questions.

To view the inventory and learn how you can help with our update, visit: **cadth.ca/CMII**

CADTH is an independent, not-for-profit organization responsible for providing Canada's health care decision-makers with objective evidence to help make informed decisions about the optimal use of drugs and medical devices in our health care system.

CADTH receives funding from Canada's federal, provincial, and territorial governments, with the exception of Quebec.

CADTH Evidence Driven.

cadth.ca

GE Healthcare

Believe

in the power of One & Done imaging.

For more information please contact
Diane Villeneuve at 705-698-9423 or Diane.Villeneuve@ge.com

gehealthcare.com