Doing the Right Thing at the Right Time:
Appropriate Imaging Utilization

The Canadian Association of Radiologists

77th Annual Scientific Meeting

Montreal, Quebec | April 24–27, 2014

L'Association canadienne des radiologistes

77e Congrès scientifique annuel

Montréal (Québec) | du 24 au 27 avril 2014

La bonne chose au bon moment :
L'utilisation appropriée de l'imagerie médicale

Canadian Association of Radiologists
L'Association canadienne des radiologistes

613 860-3111 education@car.ca
www.car.ca

THANK YOU TO OUR SPONSORS
REMERCIEMENTS À NOS COMMANDITAIRES

Thank you to our sponsors for generously providing educational grants in support of the CAR 77th Annual Scientific Meeting.
Nous remercions les commanditaires suivants pour leur subvention de formation envers le 77e Congrès scientifique annuel de la CAR.

Gold / Or

BRACCO LIFE FROM INSIDE

Christie innoMed Solutions · Evolution · Vision

EOS imaging

Global imaging ON LINE Global answers to your specific needs

Mallinckrodt Pharmaceuticals

PHILIPS

TOSHIBA Leading Innovation

Silver / Argent

abbvie

Bayer HealthCare

AGFA HealthCare

Canon Because It Counts

HITACHI Inspire the Next

ALOKA illuminate the change

ELSEVIER

GE Healthcare

Intelerad® Distributed Radiology Solutions™

peerVue

McKESSON Canada

faxitron® Distributed by / Distribué par: PharmaMedSci A division of Interfax Systems Inc.

QGenda.com

REALTIME MEDICAL The Workflow Innovation Company

ScotiaMcLeod®

SIEMENS

TeraRecon

uOttawa Faculté de médecine Faculty of Medicine

CAR 77th ANNUAL SCIENTIFIC MEETING
77e CONGRÈS SCIENTIFIQUE ANNUEL DE LA CAR

MONTREAL, QUEBEC, APRIL 24 – 27, 2014
The Canadian Association of Radiologists wishes to extend its sincere thanks to the volunteer members of the ASM Working Group. It is their dedication, expertise and pursuit of excellence that has shaped this year's outstanding educational programme.

MONTRÉAL (QUÉBEC), DU 24 AU 27 AVRIL 2014
L'Association canadienne des radiologistes souhaite transmettre ses remerciements les plus sincères aux membres bénévoles du groupe de travail du Congrès. Leur dévouement et leur expertise ont contribué à mettre sur pied un programme scientifique d'une qualité exceptionnelle.

Canadian Association of Radiologists 77th Annual Scientific Meeting Working Group
Membres du groupe de travail du 77e Congrès scientifique annuel de l'Association canadienne des radiologistes

Carole Dennie, MD, Radiologist/radiologiste, Ottawa – Chair/présidente
Tanya Chawla, MD, Radiologist/radiologiste, Toronto
Christina Chingkoe, MD, Radiology Resident/ résidente en radiologie, Toronto
Phyllis Glanc, MD, Radiologist/radiologiste, Toronto
Angus Hartery, MD, Radiologist/radiologiste, St. John's
Dipinder Keer, MD, Radiology Resident/résident en radiologie, St. John's
Jonathon Leipsic, MD, Radiologist/radiologiste, Vancouver
Emil Lee, MD, Radiologist/radiologiste, Vancouver
William Miller, MD, Radiologist/radiologiste, Ottawa
Neety Panu, MD, Radiologist/radiologiste, Thunder Bay
Michael Patlas, MD, Radiologist/radiologiste, Hamilton
Donatella Tampieri, MD, Radiologist/radiologiste, Montréal

Working Group Disclosures / Divulgations du Groupe de travail
Dr. Jonathon Leipsic declares that he is a Consultant and Speaker with GE Healthcare.
Dr. Emil Lee declares he holds investments with, and is a founding partner of, Medval.

TABLE OF CONTENTS | TABLE DES MATIÈRES

PHILIPS

THE CAR PARTNER PROGRAM
LE PROGRAMME DES PARTENAIRES DE LA CAR

The Canadian Association of Radiologists places tremendous value on the industry partnerships it has cultivated. These partnerships are essential for the CAR in achieving its goal of advancing the profession through leadership in healthcare and excellence in patient care. We would like to extend our sincere gratitude to the following CAR partners for their leadership and continued support.

L'Association canadienne des radiologistes accorde une extrême importance aux partenariats qu'elle forge dans l'industrie. Aux yeux de la CAR, en stimulant le leadership et en encourageant l'excellence en soins de santé, ces ententes sont essentielles à l'avancement de notre profession. C'est pourquoi nous souhaitons exprimer notre sincère reconnaissance envers les partenaires de la CAR en considération de leurs qualités de leader et de leur appui continu.

AGFA HealthCare

BRACCO LIFE FROM INSIDE

Christie innoMed Solutions · Evolution · Vision

Mallinckrodt Pharmaceuticals

SIEMENS

Welcome Letters

Mots de bienvenue

As Minister of Health, I want to extend greetings to the participants of the 77th Annual Scientific Meeting of the Canadian Association of Radiologists. This year's theme, *Doing the Right Thing at the Right Time: Appropriate Imaging Utilization*, will focus on the appropriate use of medical imaging, which is key to providing quality care for patients.

Patients deserve to have access to the right care and right information at the right time. Over the years, the demand for medical imaging has grown exponentially and the pressure to offer the right medical care while assuring appropriateness and patient safety is greater than ever.

The Government of Canada commends radiologists for your professionalism and dedication in the vital role you play in ensuring the proper diagnosis and treatment of patients. Your expertise and commitment to offer patients access to accurate, safe and suitable diagnostic testing is helping to improve the healthcare system and the health and well-being of Canadians.

Health Canada remains committed to working with the healthcare community in our continued support of innovation, research and technology. Together, we can improve the quality, accessibility and sustainability of Canada's healthcare system.

I wish you all a very successful event.

En tant que ministre de la Santé, je désire souhaiter la bienvenue aux participants au 77e Congrès scientifique annuel de l'Association canadienne des radiologistes. Le thème de cette année, *La bonne chose au bon moment : l'utilisation appropriée de l'imagerie médicale*, met l'accent sur l'utilisation à bon escient de l'imagerie médicale, ce qui est essentiel pour fournir des soins de qualité.

Les patients méritent d'avoir accès aux bons soins et renseignements au bon moment. Au fil des ans, la demande de services d'imagerie médicale a connu une croissance exponentielle, et le besoin d'offrir des soins médicaux appropriés tout en veillant à la sécurité des patients se fait sentir plus que jamais.

Conscient du rôle crucial que les radiologistes jouent dans l'établissement du bon diagnostic et du traitement approprié des patients, le gouvernement du Canada vous félicite pour votre professionnalisme et votre dévouement. Votre expertise et votre ferme volonté d'assurer l'accès des patients à des tests de diagnostic précis, sûrs et adéquats contribuent à améliorer le système de soins de santé ainsi que la santé et le bien-être des Canadiens.

Santé Canada reste acquis à l'idée de collaborer avec le milieu des soins de santé pour continuer à favoriser l'innovation, la recherche et les progrès technologiques. Ensemble, nous pouvons améliorer la qualité, l'accessibilité et la viabilité du système canadien de soins de santé.

Je vous souhaite une rencontre des plus fructueuses.

Rona Ambrose
Minister of Health / Ministre de la Santé
Government of Canada / Gouvernement du Canada

Collection Assemblée nationale du Québec / Photographe : Marc-André Grenier

Pour notre gouvernement, « les bons soins, au bon endroit et au bon moment » est un véritable leitmotiv qui guide nos actions visant à améliorer la qualité, l'accessibilité et la continuité des soins et des services de santé au Québec. Avec un thème comme *La bonne chose au bon moment : l'utilisation appropriée de l'imagerie médicale*, ce 77e Congrès scientifique de l'Association canadienne des radiologistes s'inscrit sans contredit dans la même logique.

Les radiologistes sont des acteurs importants de notre système public de santé. Votre contribution est essentielle pour l'atteinte de nos objectifs communs d'amélioration et de consolidation des soins et des services offerts à la population.

En travaillant tous de concert, et dans un esprit de valorisation des pratiques collaboratives, je suis convaincu que nous parviendrons ensemble à offrir des soins et des services publics encore plus accessibles à l'ensemble de nos concitoyennes et concitoyens.

Je vous souhaite à toutes et à tous un congrès aussi intéressant qu'inspirant, au profit d'une pratique toujours plus innovante, performante et épanouissante.

For our government, providing "the right care in the right place at the right time" is an ideal that drives our efforts to constantly improve the quality, accessibility, and continuity of health care and health services in Québec. So with *Doing the Right Thing at the Right Time: Appropriate Imaging Utilization* as its theme, the 77th Annual Scientific Meeting of the Canadian Association of Radiologists goes hand in hand with this objective.

As radiologists, you are critical members of our public health system. You play a key role in achieving our shared goals of enhancing and consolidating the care and services available to the public.

I know that by working together to foster greater collaboration, we can make government health care and services even more accessible to all our citizens.

I wish you all an eye-opening, inspiring meeting that will open the door to even more innovative, effective, and rewarding practices.

Réjean Hébert
Ministre de la Santé et des Services sociaux et ministre responsable des Aînés
Minister of Health and Social Services and Minister responsible for Seniors

Québec

Au nom de tous les Montréalais, il me fait plaisir de vous souhaiter la bienvenue dans notre métropole à l'occasion du 77e Congrès scientifique annuel de l'Association canadienne des radiologistes.

Je suis convaincu que les présentations de haut calibre et les discussions qui se dérouleront ici au cours des prochains jours auront un impact positif sur votre profession et sur la qualité des soins de santé que reçoivent les patients canadiens.

Notre ville offre un environnement des plus propices à vos échanges. Avec ses 4 universités et plus de 150 centres de recherche, Montréal est très active dans le domaine des sciences de la vie et des technologies de la santé.

J'espère que vous profiterez de votre séjour pour découvrir ou redécouvrir Montréal, métropole francophone d'Amérique et l'une des villes les plus anciennes du continent. Vous constaterez que notre ville possède une personnalité originale, entre autres, du fait qu'elle se trouve au carrefour des influences américaines et européennes.

N'hésitez pas à mettre au programme de votre visite quelques-unes de nos nombreuses propositions gastronomiques et artistiques qui ont fait la réputation de notre ville. Montréal possède tous les attributs d'une véritable métropole internationale, son meilleur atout étant sa population, reconnue pour la qualité de son accueil.

Mes meilleurs voeux de succès accompagnent tous ceux qui ont pris part à l'organisation de cette importante rencontre.

Un excellent séjour à nos visiteurs!

On behalf of all Montréalers, I am pleased to welcome you to our metropolis for the 77th Annual Scientific Meeting of the Canadian Association of Radiologists.

I am certain that the high-calibre presentations and discussions that will take place over the next few days will have a positive impact on your profession and the quality of health care available to Canadian patients.

Montréal offers an environment that is extremely conducive to exchange, with its 4 universities and over 150 research centres. Our city is also extremely active in the fields of life sciences and health technology.

I hope that you will take the time to discover or rediscover Montréal, America's French-speaking metropolis and one of the continent's oldest cities. You will discover that Montréal has its own personality that mixes North American influences with European flair.

A visit to Montréal would not be complete without fine dining at some of our best restaurants and visiting the artistic venues that have built our reputation. This is truly an international and cosmopolitan city which takes pride in its greatest asset – the warmth and hospitality of Montréalers.

I wish the best of success to the organizers of this prestigious event and a productive meeting.

Enjoy your stay!

Denis Coderre
Maire de Montréal / Mayor of Montréal

Montréal

Dear Delegates,

On behalf of Tourisme Montréal and all of our tourism industry professionals, I wish you a warm welcome to Montréal. Medical research and training is of great importance in Montréal and we are extremely proud that the Canadian Association of Radiologists chose our city to hold its 77th Annual Scientific Meeting.

This gathering of radiology experts and professionals from Canada and around the world confirms Montréal's reputation as a premier destination for conferences and meetings. This event is also of great significance for our city, a leader in the health and life sciences sector, which is also one of its most thriving industries.

With its European style, world-class gastronomy and buzzing cultural scene, Montréal charms visitors from all walks of life who appreciate its cosmopolitan character and modern infrastructure. From one end of the island to the other, you will experience Montréal's unparalleled joie de vivre, creativity and signature hospitality.

We truly hope that all the participants will take full advantage of everything Montréal's spring has to offer and will have a memorable and rewarding experience.

Bienvenue à Montréal!

Chers congressistes,

Au nom de Tourisme Montréal et de toute l'industrie touristique montréalaise, je vous souhaite la bienvenue à Montréal. Ayant incontestablement à coeur la recherche et la formation dans le domaine médical, nous sommes très fiers que l'Association canadienne des radiologistes ait choisi notre ville pour y tenir son 77e Congrès scientifique annuel.

Cette rencontre d'experts et de professionnels de la radiologie à l'échelle nationale et internationale atteste la place prépondérante qu'occupe Montréal à titre de destination de choix pour la tenue de congrès. Cet événement revêt également une grande importance puisque notre ville est un chef de file du secteur des sciences de la santé, une des principales industries montréalaises.

Avec son style européen, sa gastronomie réputée et sa vie culturelle trépidante, Montréal charme les visiteurs de tous les horizons, qui apprécient également ses infrastructures modernes et son caractère cosmopolite. D'un bout à l'autre de l'île, vous serez séduits autant par la joie de vivre et la créativité de la métropole que par l'hospitalité des Montréalais.

Nous souhaitons à tous les participants de profiter pleinement de tout ce que le printemps à Montréal a à offrir et de vivre une expérience enrichissante et mémorable.

Bon séjour!

Yves Lalumière
Président-directeur général / President and Chief Executive Officer
Tourisme Montréal

Montréal

I am honoured to welcome all of you to Montreal for the Canadian Association of Radiologists 77th Annual Scientific Meeting (ASM).

This year's theme, *Doing the Right Thing at the Right Time: Appropriate Imaging Utilization*, reflects the commitment of radiologists, from coast to coast, to provide the highest quality and the most appropriate patient care possible. As leaders in their communities, radiologists have a duty, in their day-to-day practices, to reaffirm their engagement, their expertise and their drive to be an integral part of the healthcare team.

To this end, this year's ASM offers optimal learning opportunities with its mix of lectures, debates and hands-on learning. New offerings this year include a Live Ultrasound Simulation Workshop focusing on ankle tendons & ligaments, a debate on structured reporting, and a mock trial highlighting the medico-legal risks faced by radiologists.

It is equally important, in this age of "virtual contact", to maintain and encourage the face-to-face interaction with our like-minded colleagues from Canada and abroad. Your presence here today reflects that sentiment.

We have many people to thank for making this event possible: the ASM Working Group for their tireless efforts, our industry partners for their continued support and our esteemed guest speakers for accepting to share their knowledge with their Canadian colleagues.

I wish you all a successful meeting.

C'est un honneur pour moi de vous accueillir à Montréal pour le 77e Congrès scientifique annuel de l'Association canadienne des radiologistes.

Le thème de cette année, *La bonne chose au bon moment : l'utilisation appropriée de l'imagerie médicale*, reflète l'engagement des radiologistes, d'un océan à l'autre, à fournir les soins de la plus grande qualité et les plus appropriés qui soient à leurs patients. À titre de leaders dans leurs communautés, il leur incombe, dans leurs activités journalières, d'affirmer cet engagement, leur expertise et leur désir de s'intégrer au sein de l'équipe de soins de santé.

À cette fin, le Congrès abonde en occasions exceptionnelles d'apprentissage, avec son mélange de présentations, de débats et de formation pratique. Parmi les nouveautés cette année, on compte l'Atelier de simulation en matière d'échographie axé sur les tendons et ligaments de la cheville, un débat sur le signalement structuré et un procès fictif illustrant les risques médico-légaux que les radiologistes doivent affronter.

Il est également important, en cette ère de « contact virtuel », de maintenir et d'encourager l'interaction personnelle avec nos consoeurs et confrères de partout au Canada et d'ailleurs. Votre présence ici aujourd'hui en témoigne.

Nous remercions tous les collaborateurs qui ont rendu notre Congrès possible : le Groupe de travail du Congrès pour leurs efforts continus, nos partenaires d'industrie pour leur appui et nos conférenciers pour avoir bien voulu partager leurs connaissances avec leurs collègues canadiens.

À tous, je vous souhaite un Congrès des plus enrichissants.

Dr. Jacques Lévesque
President / Président
Canadian Association of Radiologists / L'Association canadienne des radiologistes

Canadian Association of Radiologists
L'Association canadienne des radiologistes

General Information

Renseignements généraux

MEETING THEME: *DOING THE RIGHT THING AT THE RIGHT TIME: APPROPRIATE IMAGING UTILIZATION*

The Canadian Association of Radiologists (CAR) has developed a program based on appropriateness in medical imaging, a subject deemed to be of prominent interest by Canadian radiologists at past annual meetings. The comprehensive event program, themed as ***Doing the Right Thing at the Right Time: Appropriate Imaging Utilization***, will address current key issues that affect radiologists and radiologists-in-training.

The 77th Annual Scientific Meeting (ASM) covers a broad range of subjects designed for both established and new radiologists. The didactic lectures, debates and hands-on workshops provide a healthy mix of formats to enhance every participant's learning experience.

ACCREDITATION

Participants should only claim the credits commensurate with the extent of their participation in the activity.

Canadian Radiologists

The Canadian Association of Radiologists (CAR) 77th Annual Scientific Meeting is an Accredited Group Learning Activity (Section 1) as defined by the Maintenance of Certification (MOC) Program of the Royal College of Physicians and Surgeons of Canada (RCPSC) and approved by the CAR for a maximum of **19 credit-hours**.

Participants in the **Live Ultrasound Simulation Workshop – Approach to Ankle Tendons and Ligaments** are eligible to claim a maximum of **9 credit-hours** (3 credits per hour) under Section 3 of the RCPSC MOC Program. The RCPSC recording system will automatically convert the credit-hours for this workshop to 3 credits per claimed hour (i.e., 3 hours x 3 credits = 9 credit-hours).

After the event, participating Canadian radiologists will be able to download a fillable PDF to complete their certificate of attendance at www.car.ca/files/cert2014

Participants can document their learning in the RCSPC MAINPORT portal at https://login.royalcollege.ca/oamlogin/login.jsp

American Radiologists

Through an agreement between the Royal College of Physicians and Surgeons of Canada and the American Medical Association (AMA), physicians may convert Royal College MOC credits to *AMA PRA Category 1 Credits™*. Information on the process to convert Royal College MOC credits to AMA credits can be found at www.ama-assn.org/go/internationalcme.

Canadian Technologists

The CAR 77th ASM has also been accredited by the Canadian Association of Medical Radiation Technologists (CAMRT) **Category A credits**.

Certificates of attendance will be sent by email to participating technologists following the event.

PRESENTATIONS

Presentation time slots are 30 minutes, unless otherwise indicated. Speakers will give 25-minute presentations with 5 minutes reserved at the end for questions from the audience. Every session has been designed as an educational offering to advance practitioners' professional development and the profession.

PHOTOGRAPHY

A photographer may be taking photos at the conference and social events. These photos may be used in CAR publications. Your participation at this event indicates your consent to be photographed.

DISCLAIMER

No responsibility is assumed by the CAR for any injury and/or damage to persons or property as a matter of product liability, negligence or otherwise, or from any use or operation of any methods, products, instructions or ideas contained in materials distributed or described during presentations throughout the CAR 77th Annual Scientific Meeting. Because of rapid advances in the medical sciences, in particular, independent verification of diagnoses and drug dosages should be made.

Although all advertising material on location and in print is expected to conform to ethical (medical) standards, inclusion in this event does not constitute a guarantee or endorsement of the quality or value of such product or of the claims made of it by its manufacturer and representatives.

LEARNING OBJECTIVES

At the end of the meeting, participants should be able to:

1. Integrate principles of appropriateness of imaging requests into clinical practice. (CanMEDS Role: Health Advocate)
2. Adopt an evidence-based approach to common radiologic findings to enable the formulation of an appropriate differential diagnosis. (CanMEDS Role: Scholar)
3. Choose an appropriate imaging modality to investigate patients with acute abdominal pain. (CanMEDS Roles: Health Advocate, Scholar)
4. Describe an appropriate algorithm for the management of acute chest pain in the emergency department due to acute coronary syndrome and acute pulmonary embolism according to the current guidelines, including special patient groups. (CanMEDS Roles: Scholar, Health Advocate)
5. Approach ultrasound examination of the ankle tendons and ligaments systematically and identify related pathology. (CanMEDS Role: Scholar)
6. Recognize the chest radiographic findings of the most common infectious, cardiovascular and interstitial lung diseases. (CanMEDS Role: Scholar)
7. Describe selected common head and neck disease processes encountered in community and academic practice, as well as important pathologies and their key distinguishing imaging features. (CanMEDS Role: Scholar)

8. Apply the current recommendations regarding the investigation and follow-up of cystic adnexal masses and endometrial anomalies discovered at imaging. (CanMEDS Roles: Health Advocate, Professional)

9. Identify and avoid common blind spots and recognize and avoid common misinterpretations in each of the following subspecialties: neuroradiology, MSK, abdominal and chest imaging. (CanMEDS Roles: Scholar, Professional)

10. Demonstrate improved proficiency in the diagnosis of common and atypical conditions in pediatric radiology. (CanMEDS Role: Scholar)

11. Demonstrate competence in specific updated referral practices for the main breast imaging modalities. (CanMEDS Role: Health Advocate)

12. Demonstrate that professionalism involves a wide array of responsibilities to oneself, to colleagues, to patients, to one's institution and to society. (CanMEDS Role: Professional)

13. List strategies to improve work/life balance. (CanMEDS Role: Professional)

14. Contrast the pros and cons of structured/itemized reporting in diagnostic radiology. (CanMEDS Role: Communicator)

15. Apply enhanced point-of-care, hepatic and obstetric ultrasound skills. (CanMEDS Roles: Scholar, Health Advocate)

16. Discuss the differential diagnoses of common pathologies in a selection of multimodal, multidisciplinary cases. (CanMEDS Roles: Scholar, Health Advocate)

ASM EVALUATION FORMS

Your comments and feedback are instrumental in helping us plan future meetings and events. To this end, an evaluation form for the overall meeting is included in your registration package. As well, session/speaker evaluation forms will be handed out at each session. Please take a few moments to complete these and return them on site to the CAR Registration Desk. Alternatively, you will receive a Web link after the meeting asking you to evaluate the event and the individual sessions, in case you did not have the opportunity to fill out the forms during the meeting. Thank you for your cooperation and guidance.

PRESENTATIONS

Many of the speakers at the CAR 77th ASM have agreed to make their presentations available to attendees. Therefore, we will send attendees an email after the event with links to these presentations in PDF.

VERY IMPORTANT VOLUNTEER "VIV" EVENT

In recognition of the efforts of our volunteer groups, we are inviting our **CAR volunteers** to join us for the exclusive Very Important Volunteer "VIV" Event, where we will acknowledge their invaluable contributions to the CAR as well as to the profession of radiology.

Saturday, April 26
5:30 p.m. – 6:15 p.m.

Le Windsor, Peacock Alley
1170 Peel Street
Montreal, Quebec

ANNUAL DINNER AND AWARDS GALA

Experience the gallantry of one of Montreal's most prestigious and historic landmarks.

This year's Annual Dinner and Awards Gala will be held in the awe-inspiring Versailles Ballroom at Le Windsor, one of downtown Montreal's most prestigious and historic landmarks. Le Windsor is located steps away from Le Centre Sheraton.

Saturday, April 26
6:30 p.m. – 7:30 p.m. – Cocktail Reception, Peacock Alley
7:30 p.m. – 10:00 p.m. – CAR Annual Dinner and Awards Gala, Versailles Ballroom

Le Windsor
1170 Peel Street
Montreal, Quebec

Tickets must be purchased in advance, either when registering online for the ASM or at the CAR Registration Desk before 4:00 p.m. on the day of the event.

ANNUAL GENERAL MEETINGS

Canadian Association of Radiologists
Saturday, April 26
12:15 p.m. – 1:25 p.m.
(Lunch included)

Le Centre Sheraton
Salon Drummond, Level 3
1201 René-Lévesque Blvd. West
Montreal, Quebec

Canadian Radiological Foundation
Saturday, April 26
12:15 p.m. – 1:25 p.m.
(Lunch included)

Le Centre Sheraton
Salon Drummond, Level 3
1201 René-Lévesque Blvd. West
Montreal, Quebec

ELECTRONIC ACCESS

This programme is available electronically in PDF format at www.car.ca/files/prog2014asm.pdf

The ASM agenda is also available via the following conference application at https://events.bizzabo.com/car14

THÈME DU CONGRÈS : *LA BONNE CHOSE AU BON MOMENT : L'UTILISATION APPROPRIÉE DE L'IMAGERIE MÉDICALE*

L'Association canadienne des radiologistes (CAR) a conçu un programme axé sur l'utilisation appropriée de l'imagerie médicale, un sujet jugé de première importance par les radiologistes canadiens lors des congrès annuels antérieurs. Le programme de l'événement, dont le thème est ***La bonne chose au bon moment : l'utilisation appropriée de l'imagerie médicale***, abordera des enjeux clés qui touchent autant les radiologistes actuels que les radiologistes en formation.

Le 77e Congrès scientifique annuel adresse un éventail de sujets tout désignés pour les radiologistes débutants et expérimentés. Les présentations didactiques, les débats et les ateliers pratiques forment un heureux mélange de formats qui rehaussera l'expérience d'apprentissage de chaque participant.

AGRÉMENT

Le participant doit réclamer ses unités de formation (crédits) proportionnellement à sa participation à l'activité.

Radiologistes canadiens

Le 77e Congrès scientifique annuel de l'Association canadienne des radiologistes (CAR) est reconnu comme une activité d'apprentissage de groupe (section 1) par le programme de Maintien du certificat (MDC) du Collège royal des médecins et chirurgiens du Canada (CRMCC), et la CAR approuve donc, au maximum, **19 heures-crédits** dans le cadre de cette activité.

Les participants à l'**Atelier de simulation en matière d'échographie de la cheville – tendons et ligaments** peuvent obtenir, au maximum, **9 heures-crédits** (3 crédits par heure) sous la section 3 du programme de MDC du CRMCC. Le système de suivis du CRMCC convertira automatiquement chaque heure réclamée pour cet atelier à 3 heures-crédits (c.-à-d., 3 heures x 3 crédits = 9 heures-crédits).

À l'issue du Congrès, les radiologistes canadiens qui y ont participé pourront télécharger un fichier PDF modifiable afin de préparer leur certificat de participation, à www.car.ca/files/cert2014

Les participants peuvent documenter leur apprentissage par le biais du portail MAINPORT du CRMCC à https://login.royalcollege.ca/oamlogin/login.jsp

Radiologistes américains

En vertu d'une entente entre le Collège royal des médecins et chirurgiens du Canada (CRMCC) et l'American Medical Association (AMA), les médecins peuvent convertir les crédits MDC du CRMCC en *crédits AMA PRA de catégorie 1™*. Pour de plus amples renseignements relatifs au processus de conversion, visitez le www.ama-assn.org/go/internationalcme.

Technologues canadiens

Le 77e Congrès scientifique annuel de la CAR a aussi été agréé par l'Association canadienne des technologues en radiation médicale (ACTRM) pour **crédits** de **catégorie A**.

Les certificats de participation seront envoyés par courriel aux technologues à l'issue du Congrès.

PRÉSENTATIONS

À moins d'avis contraire, 30 minutes sont prévues pour les conférences. Les présentations des conférenciers durent 25 minutes et sont suivies d'une période de questions de 5 minutes. Chaque séance offre un contenu éducationnel conçu pour favoriser le perfectionnement professionnel du praticien et pour contribuer à l'avancement de la profession dans son ensemble.

LES PHOTOS

Un photographe sera sur les lieux lors du Congrès et des réceptions. Il est possible que ces photos soient utilisées dans certaines publications de la CAR. La présence des participants au Congrès constitue leur consentement explicite à être photographiés.

AVIS DE NON-RESPONSABILITÉ

La responsabilité de la CAR ne saurait en aucune façon être engagée pour tout préjudice ou dommage aux personnes ou aux biens découlant du fait des produits, de la négligence ou autre, ou encore de l'utilisation ou de l'application de produits, de méthodes, d'instructions ou d'idées contenus lors du 77e Congrès scientifique annuel de la CAR. En raison notamment des progrès rapides du domaine des sciences médicales, un contrôle indépendant des diagnostics et de la posologie devrait être effectué.

Bien que tout matériel publicitaire imprimé et sur les lieux soit tenu de respecter les normes d'éthique (du domaine médical), la présence lors de cet événement de tel matériel ne constitue en rien une garantie, ni ne vient appuyer la qualité ou la valeur des produits ou les promesses du fabricant ou de ses délégués à leur égard.

LES OBJECTIFS D'APPRENTISSAGE

À la fin de la rencontre, les participants devraient pouvoir :

1. Intégrer les principes de pertinence des requêtes d'imagerie aux pratiques cliniques. (Rôle CanMEDS : promoteur de la santé)
2. Adopter une approche factuelle à l'égard de trouvailles radiologiques courantes afin de formuler un diagnostic différentiel approprié. (Rôle CanMEDS : érudit)
3. Choisir une modalité d'imagerie appropriée à l'évaluation des patients présentant une douleur abdominale aiguë. (Rôles CanMEDS : promoteur de la santé, érudit)
4. Décrire un algorithme convenant à la prise en charge, au service d'urgence, d'une douleur thoracique aiguë attribuable à un syndrome coronarien aigu et à une embolie pulmonaire aiguë selon les lignes directrices courantes, incluant les groupes de patients spéciaux. (Rôles CanMEDS : érudit, promoteur de la santé)
5. Aborder de façon systématique l'échographie des tendons et des ligaments de la cheville et identifier les affections connexes. (Rôle CanMEDS : érudit)
6. Reconnaître les trouvailles radiographiques pulmonaires associées aux pathologies infectieuses, cardiovasculaires et interstitielles les plus courantes. (Rôle CanMEDS : érudit)

7. Décrire certaines pathologies de la région de la tête et du cou couramment observées dans la pratique en milieu communautaire et universitaire ainsi que certaines affections importantes et leurs caractéristiques distinctives à l'imagerie. (Rôle CanMEDS : érudit)

8. Mettre en pratique les recommandations relatives à l'évaluation et au suivi des masses annexielles kystiques et des anomalies endométriales décelées par imagerie. (Rôles CanMEDS : promoteur de la santé, professionnel)

9. Cerner et éviter les zones aveugles courantes, ainsi que reconnaître et éviter les erreurs d'interprétation courantes propres à chacune des sous-spécialités suivantes : neuroradiologie, radiologie musculosquelettique et imagerie abdominale et thoracique. (Rôles CanMEDS : érudit, professionnel)

10. Démontrer de meilleures compétences dans le diagnostic d'affections courantes et atypiques en radiologie pédiatrique. (Rôle CanMEDS : érudit)

11. Démontrer la compétence à recourir aux plus récentes pratiques d'aiguillage en ce qui concerne les principales modalités d'imagerie du sein. (Rôle CanMEDS : promoteur de la santé)

12. Démontrer que le professionnalisme implique un large éventail de responsabilités envers soi-même, les collègues, les patients, l'établissement et la collectivité. (Rôle CanMEDS : professionnel)

13. Établir une liste de stratégies qui permettront d'atteindre une meilleure conciliation travail-vie. (Rôle CanMEDS : professionnel)

14. Peser les avantages et les inconvénients de l'utilisation de rapports radiologiques structurés ou détaillés. (Rôle CanMEDS : communicateur)

15. Mettre en pratique des compétences améliorées en matière d'échographie hépatique, obstétricale et au point de service. (Rôles CanMEDS : érudit, promoteur de la santé)

16. Discuter des diagnostics différentiels de pathologies courantes à partir d'une sélection de cas faisant appel à une approche plurimodale et multidisciplinaire. (Rôles CanMEDS : érudit, promoteur de la santé)

FORMULAIRES D'ÉVALUATION DU CONGRÈS

Votre rétroaction et vos commentaires sont essentiels à la bonne planification de nos événements futurs. À cette fin, un formulaire d'évaluation générale est inclus dans votre trousse d'inscription. De plus, des formulaires d'évaluation des conférenciers / sessions seront remis à chaque session. Nous vous prions de prendre quelques moments pour les compléter et les remettre au comptoir d'inscription de la CAR. Le cas échéant, vous recevrez un lien Web après le Congrès vous invitant à évaluer le Congrès, au cas où vous n'auriez pas eu l'occasion de le faire sur place. Nous vous remercions de votre coopération et de vos conseils.

PRÉSENTATIONS

Plusieurs des conférenciers au 77e Congrès scientifique annuel de la CAR ont consenti à rendre leurs présentations accessibles aux participants. Ainsi, nous enverrons un courriel aux participants après le Congrès avec des liens à ces présentations en PDF.

RÉCEPTION DES BÉNÉVOLES DE MARQUE « V.I.V. »

En reconnaissance des efforts des bénévoles de la CAR, nous les invitons à se joindre à nous pour la Réception des bénévoles de marque « V.I.V. », au cours de laquelle nous soulignerons leur immense contribution envers la CAR ainsi qu'à la profession de radiologie.

Samedi le 26 avril
17 h 30 – 18 h 15

Le Windsor, Peacock Alley
1170, rue Peel
Montréal (Québec)

DÎNER ANNUEL ET GALA DE REMISE DES PRIX

Laissez-vous séduire par le charme d'un des plus prestigieux points de repère historiques à Montréal.

Cette année, le dîner annuel et le gala de remise des prix auront lieu dans le Salon Versailles du Windsor, joyau architectural et historique du centre-ville de Montréal. Le Windsor est situé à quelques pas du Centre Sheraton.

Samedi le 26 avril
De 18 h 30 à 19 h 30 – Cocktail, Peacock Alley
De 19 h 30 à 22 h 00 – Dîner annuel et gala de remise des prix, Salon Versailles

Le Windsor
1170, rue Peel
Montréal (Québec)

Les billets doivent être achetés à l'avance, soit lors de l'inscription en ligne, ou au comptoir d'inscription de la CAR avant 16 h le jour même du gala.

ASSEMBLÉES GÉNÉRALES ANNUELLES

L'Association canadienne des radiologistes
Samedi le 26 avril
De 12 h 15 à 13 h 25
(Déjeuner inclus)

Le Centre Sheraton
Salon Drummond, 3e étage
1201, boul. René-Lévesque Ouest
Montréal (Québec)

Fondation radiologique canadienne
Samedi le 26 avril
De 12 h 15 à 13 h 25
(Déjeuner inclus)

Le Centre Sheraton
Salon Drummond, 3e étage
1201, boul. René-Lévesque Ouest
Montréal (Québec)

ACCÈS ÉLECTRONIQUE

Ce programme est disponible en format PDF à www.car.ca/files/prog2014asm.pdf

Le sommaire du programme est aussi disponible par l'entremise de l'application-conférence à https://events.bizzabo.com/car14

MARK YOUR CALENDAR

2015 Joint Congress on Medical Imaging and Radiation Sciences

Collaborative Care – Imaging and Treatment

May 27 to 30, 2015
Le Palais des congrès de Montréal, Montreal, Quebec

À NOTER À VOTRE AGENDA

Le congrès conjoint de l'imagerie médicale et des sciences de la radiation 2015

Une approche collaborative – imagerie médicale et traitement

Du 27 au 30 mai 2015
Le Palais des congrès de Montréal, Montréal (Québec)

Awards of Excellence

Prix d’excellence

CAR Gold Medal Award 2014
Dr. Martin Reed, Manitoba

In addition to his stellar achievements in his practice as a pediatric radiologist, Dr. Martin Reed has been active on the local, national and international scenes in advancing our profession.

Dr. Reed's contributions to the Canadian Association of Radiologists (CAR) span more than 40 years. During this time and up to 2013, he served in multiple roles on the boards of directors of both the CAR and the Canadian Radiological Foundation. He was the first to actively promote the CAR as a leader in improving the appropriateness of diagnostic imaging requests in Canada. Currently in his 10th year as Chair of the CAR initiatives on referral guidelines, he has lead three extensive projects on diagnostic imaging demand-side controls from 2007 to 2012.

He represents the CAR as a world-renowned leader in imaging appropriateness and most recently is chairing the CAR Working Group for the inaugural 2014 *Choosing Wisely Canada* campaign to help physicians and their patients make informed decisions in their health care. He is also co-chair of the International Radiology Quality Network Referral Guidelines Committee, and has participated in consultations with the World Health Organization on diagnostic imaging appropriateness.

He was co-chair of the Medical Isotopes and Imaging Modalities Advisory Committee of the Canadian Agency for Drugs and Technologies in Health and currently represents the CAR on the Implementers' Group for Diagnostic Imaging for Canada Health Infoway.

While his peers consider him to be a leader of our profession, he is also an avid supporter of the education of Canada's future generation of radiologists. He was program director for the University of Manitoba's Department of Radiology, was active in the Manitoba College of Physicians and Surgeons, and served as chair of the Specialty Committee in Pediatric Radiology for the Royal College of Physicians and Surgeons of Canada.

He is currently the Director of the Department of Radiology, Rehabilitation Centre for Children, Winnipeg and a radiologist at the Children's Hospital in Winnipeg. Dr. Reed has authored more than 100 peer-reviewed articles, books or book chapters and countless presentations.

Dr. Reed has a gift for balancing critical appraisal of the literature with clinical wisdom. He is a wonderful mentor for the next generation of scholars, and a true visionary leader for the CAR and for the profession. His passion, persistence and scholarly integrity are exemplary, and for these outstanding qualities, and many others, we are honoured to present him with the 2014 CAR Gold Medal Award.

Young Investigator Award 2014
Dr. Jai Jai Shiva Shankar, Nova Scotia

Dr. Jai Jai Shiva Shankar is described by his peers as a valued clinical and scientific collaborator, as well as a "driver of research and innovation". After obtaining his medical degrees abroad (India, France and Thailand) between 2001 and 2008, he pursued fellowships in neuroradiology at The Ottawa Hospital and in interventional radiology at both the Ottawa Hospital and the Toronto Western Hospital. He began his teaching career as an assistant professor of neuroradiology at the Queen Elizabeth II Hospital (Department of Diagnostic Imaging) in 2010. Since his arrival at the QE II, where he is currently an associate professor of neuroradiology, he quickly distinguished himself as a leader in the neuroradiology section and was responsible for a number of new interventional efforts.

His main areas of interest – interventional radiology, perfusion studies and functional MRI – have driven him to play a key role in a number of new initiatives, among them: intra-arterial stroke treatment using Stent-retriever mechanical thrombolysis; weekly stroke and interesting case rounds; CT perfusion imaging for acute stroke; MR perfusion imaging for brain tumors; percutaneous chemotherapeutic treatment for facial venous vascular malformation using Bleomycin; and setting up the Acute Stroke Code protocols. He is the principal investigator for the Canadian SILK Registry (a multicentre registry) and site principal investigator for international trials, including the MARCO POLO Trial, the ESCAPE Trial and the HEAT Trial.

He recently earned himself the Dr. Charles Lo Prize in Radiology Research from Dalhousie – a testament to his commitment and achievements in the field of radiology.

This past year, Dr. Shankar was a visiting professor at Memorial University of Newfoundland where he started the Endovascular Neuroradiology Program. Since 2007, he has received 9 awards, 8 grants, has published over 37 peer-reviewed journal articles (most of them as first author) and one book chapter. He is regularly invited as a speaker, both nationally and internationally, and sits on six committees. He has recently committed to undertaking the master's program in epidemiology through the London School of Hygiene & Tropical Medicine, United Kingdom.

His ability to motivate fellow radiologists and build strong collaborations with clinical colleagues, his natural leadership and his strong dedication to research have earned him the highest recommendations. The CAR is proud to present Dr. Shankar with the 2014 CAR Young Investigator Award.

Prix de la Médaille d'Or de la CAR 2014
Dr Martin Reed, Manitoba

En plus d'avoir accompli des choses remarquables en tant que radiologiste pédiatre, le Dr Martin Reed a su, par son action, faire progresser la radiologie à l'échelle aussi bien locale que nationale et internationale.

Il y a désormais plus de 40 ans que le Dr Reed contribue à l'Association canadienne des radiologistes (CAR). Jusqu'en 2013, il a joué de multiples rôles au sein des conseils d'administration de celle-ci, ainsi que de la Fondation radiologique canadienne. Le Dr Reed a été le premier à souligner activement la contribution majeure de la CAR à l'amélioration de la pertinence des demandes d'examens de radiologie au Canada. Présidant depuis 10 ans les initiatives de la CAR liées aux lignes directrices relatives à ces demandes, il a piloté, de 2007 à 2012, trois importants projets consacrés à la régulation des demandes d'examens de radiologie à des fins diagnostiques.

Représentant la CAR en tant que spécialiste mondialement réputé de la pertinence des examens de radiologie, le Dr Reed préside le groupe de travail de la CAR mis sur pied en prévision du lancement de la campagne *Choix judicieux Canada*, qui entend aider les médecins et leurs patients à prendre des décisions éclairées en matière de soins de santé. Également coprésident du Comité responsable des lignes directrices relatives aux examens de radiologie (Referral Guidelines Committee) du Radiology Quality Network, le Dr Reed a pris part à des consultations axées sur la pertinence des examens de radiologie à des fins diagnostiques, menées sous la houlette de l'Organisation mondiale de la Santé (OMS).

Le Dr Reed a par ailleurs été coprésident du Comité consultatif sur les isotopes médicaux et les techniques d'imagerie de l'Agence canadienne des médicaments et des technologies de la santé. Il représente actuellement la CAR au sein du groupe d'Inforoute Santé du Canada formé des responsables de la mise en œuvre de l'imagerie diagnostique.

Considéré par ses pairs comme un chef de file de la profession, le Dr Reed contribue grandement à la formation de la prochaine génération de radiologistes canadiens. Il a été directeur de programme au sein du département de radiologie de l'Université du Manitoba, a joué un rôle actif au sein du Collège des médecins et chirurgiens du Manitoba, ainsi que présidé le Comité de spécialité du Collège royal des médecins et chirurgiens du Canada axé sur la radiologie pédiatrique.

Le Dr Reed est actuellement directeur du Service de radiologie du Rehabilitation Centre for Children, à Winnipeg, ainsi que radiologiste à l'Hôpital pour enfants de Winnipeg. Auteur de plus d'une centaine d'articles, ouvrages et chapitres d'ouvrages évalués par les pairs, il a déjà prononcé une multitude de conférences.

Le Dr Reed sait allier analyse critique de la littérature et bon sens clinique. Merveilleux mentor pour la prochaine génération de chercheurs, il fait office de chef de file visionnaire pour la CAR et pour la profession. La passion, la ténacité et l'intégrité professionnelle du Dr Reed sont absolument exemplaires. C'est pour souligner ces qualités exceptionnelles qui sont les siennes, parmi bien d'autres, que nous avons l'honneur de lui décerner le Prix de la Médaille d'Or de la CAR 2014.

Prix du jeune chercheur de la CAR 2014
Dr Jai Jai Shiva Shankar, Nouvelle-Écosse

Le Dr Jai Jai Shiva Shankar est décrit par ses pairs comme un collaborateur clinique et scientifique de grande valeur, ainsi que comme un « réel acteur de la recherche et de l'innovation ». Après avoir mené à terme ses études de médecine en Inde, en France et en Thaïlande, de 2001 à 2008, il a été chercheur en neuroradiologie à l'Hôpital d'Ottawa, de même qu'en radiologie exploratrice au sein de cet hôpital et du Toronto Western Hospital. Le Dr Shankar a entrepris sa carrière d'enseignant en 2010, en tant que professeur adjoint de neuroradiologie au sein du service d'imagerie diagnostique du Queen Elizabeth II Hospital. Une fois entré au service de cet établissement, où il est désormais professeur agrégé de neuroradiologie, il n'a pas tardé à se démarquer en tant que chef de file.

Ses principaux centres d'intérêt, à savoir la radiologie exploratrice, les études de perfusion et l'IRM fonctionnelle, ont conduit le Dr Shankar à jouer un rôle clé dans le cadre d'un certain nombre d'initiatives novatrices : traitement des accidents intra-artériels par thrombolyse mécanique grâce à des endoprothèses; analyses hebdomadaires des cas intéressants d'AVC et autres; imagerie de perfusion par tomodensitométrie liée aux AVC aigus; imagerie de perfusion par IRM liée aux tumeurs cérébrales; traitement par chimiothérapie percutanée des malformations vasculaires veineuses du visage grâce à la bléomycine; mise au point des protocoles Acute Stroke Code liés aux AVC aigus; etc. Le Dr Shankar est en outre chercheur principal dans le cadre d'une étude nationale multicentre (Canadian SILK Registry), ainsi que chercheur principal sur site dans le cadre de divers essais internationaux, parmi lesquels les essais MARCO POLO, ESCAPE et HEAT.

Le Dr Shankar s'est récemment vu décerner par l'Université Dalhousie le prix Dr-Charles-Lo en recherche radiologique destiné à souligner son investissement et ses réalisations dans le domaine de la radiologie.

L'an dernier, le Dr Shankar a été professeur visiteur à l'Université Memorial de Terre-Neuve, où il a mis sur pied le programme de neuroradiologie endovasculaire. Depuis 2007, il s'est vu octroyer 9 prix et 8 subventions, a publié plus de 37 articles évalués par les pairs – la plupart en tant qu'auteur principal – et a signé un chapitre d'ouvrage. Il est régulièrement invité à prononcer des conférences, au Canada et à l'étranger, et siège au sein de six comités. Le Dr Shankar a récemment annoncé son intention de s'inscrire au programme de maîtrise en épidémiologie de la London School of Hygiene & Tropical Medicine, au Royaume-Uni.

Sa capacité à motiver ses collègues radiologistes ainsi qu'à tisser de solides collaborations avec les cliniciens, ses qualités naturelles de leadership et son grand dévouement pour la recherche ont valu au Dr Shankar les plus vifs éloges. C'est donc avec fierté que nous lui décernons le Prix du jeune chercheur de la CAR 2014.

GE Healthcare

At GE, we are committed to helping increase access to healthcare while improving its quality and lowering its cost. Just like physicians everywhere. So by investing in new innovations, we are empowering the world's healthcare professionals to do what they do best: caring for patients around the world. Every day, doctors are bringing better health to more people—and GE Healthcare technologies are behind them.

imagination at work

healthymagination

Agenda

Sommaire du programme

Agenda | Sommaire du programme

Thursday, April 24, 2014

16:00	Registration Opens (4th Floor)
16:00 – 20:00	Posting of Thursday's Case of the Day (4th Floor Foyer)
18:00 – 19:00	Opening Cocktail (Salle de bal Centre)
19:00 – 19:20	**Welcoming Address: Jacques Lévesque, President of the CAR** (Salle de bal Ouest)
19:20 – 20:00	**Opening Lecture: Ella Kazerooni – Patient-Centered Radiology: The Right Thing for the Right Patient at the Right Time** (Salle de bal Ouest)

Friday, April 25, 2014

07:30 – 08:00	Review of Thursday's Case of the Day (MSK and Neuro) – *Haron Obaid* and *Carlos Torres* | Moderator: *Demetris Patsios* (Salle de bal Est)
08:00 – 17:00	Scientific and Educational Exhibits (PowerPoint Presentations – 4th Floor Foyer)
07:30 – 08:00	Breakfast (Salle de bal Centre)
08:00 – 20:00	Posting of Friday's Case of the Day (4th Floor Foyer)
08:00 – 08:40	**Plenary: Patient Satisfaction and Service Excellence in Radiology – Ella Kazerooni** (Salle de bal Ouest)

Track Title *Moderator(s)* (Location)	**The Right Thing** *Michael Martin* (Salle de bal Ouest)	**Resident Review** *Neety Panu* (Salle de bal Est)	**Live Ultrasound Simulation Workshop – Approach to Ankle Tendons & Ligaments** *Mark Cresswell, Gina Di Primio, Karen Finlay, Viviane Khoury, Linda Probyn, Marcos Sampaio*
08:45 – 09:15	Appropriate Use of Imaging in Canada – *James Fraser*	Chest – *Carolina Souza*	An immersion into musculoskeletal ultrasound imaging for those who have pre-registered, featuring real patient models
09:15 – 09:45	Teleradiology: Is Appropriateness Impacted? – *Gregory Butler*	Mammography – *Neety Panu*	
09:45 – 10:15	Who Is Accountable for the Appropriateness of Studies: The Radiologist or the Referring Physician or Both? – *Ella Kazerooni*	Abdominal MRI – *Laurence Péloquin*	

10:15 – 10:40 Nutrition Break

Track Title *Moderator(s)* (Location)	**The Right Thing** *Michael Martin* (Salle de bal Ouest)	**Resident Review** *Neety Panu* (Salle de bal Est)	**Live Ultrasound Simulation Workshop – Approach to Ankle Tendons & Ligaments** *Mark Cresswell, Gina Di Primio, Karen Finlay, Viviane Khoury, Linda Probyn, Marcos Sampaio*
10:45 – 11:15	Point of Order Decision Support – *Martin Reed*	Musculoskeletal – *Anukul Panu*	An immersion into musculoskeletal ultrasound imaging for those who have pre-registered, featuring real patient models
11:15 – 11:45	Imaging Appropriateness in Pregnancy: What to Choose, When and Why – *Phyllis Glanc*	Ultrasound – *Shia Salem*	
11:45 – 12:15	Osteoporotic Vertebral Fractures – *Brian Lentle*	Pediatric – *Heather Bray*	

12:15 – 13:25 Lunch – Exhibits

Track Title *Moderator(s)* (Location)	Acute Abdominal Pain: Don't Investigate the Patient to Death *Michael Patlas* (Salle de bal Ouest)	Resident Review *Neety Panu* (Salle de bal Est)
13:30 – 13:52	Right Upper Quadrant Pain – *Silvia Chang*	Neuroradiology – *Sandeep Naik* (13:30 – 14:00)
13:52 – 14:14	Left Upper Quadrant Pain – *Michael Patlas*	Nuclear Medicine – *Petter Tonseth* (14:00 – 14:30)
14:14 – 14:36	Right Lower Quadrant Pain – *Mostafa Atri*	Interventional Radiology – *John Kachura* (14:30 – 15:00)
14:36 – 15:00	Left Lower Quadrant Pain – *Ania Kielar*	

15:00 – 15:25 Nutrition Break

Track Title *Moderator(s)* (Location)	The Right Thing – Chest Imaging *Elsie Nguyen* (Salle de bal Ouest)	Breast Imaging *Shiela Appavoo* (Salle de bal Est)	Resident Hot Seat Sessions *Julie Hurteau-Miller, Neety Panu, Petter Tonseth*
15:30 – 16:00	Acute Chest Pain in the Emergency Department: Acute Coronary Syndrome – *Elsie Nguyen*	Breast Ultrasound Screening – *Derek Muradali*	(Restricted attendance for residents only) Small group sessions for radiology residents who have pre-registered for this opportunity Residents will be asked to interpret a series of images in a simulated setting
16:00 – 16:30	The Right Test at the Right Time: Acute Pulmonary Embolism – *Elena Peña*	Breast MRI: When Is It Not Useful? – *Jean Seely*	
16:30 – 17:00	Practice Guidelines for Management of Solid and Subsolid Nodules – *Anastasia Oikonomou*	Women Aged 40–49: The Case in Favour of Screening – *Nancy Wadden*	

17:00 – 18:00 Stanley Cup Playoffs Cocktail Party (Salle de bal Centre)

18:30 – 20:00 Reception for Radiologists-in-Training

Saturday, April 26, 2014

07:30 – 08:00 Review of Friday's Case of the Day (Body and Chest) – *Errol Colak* and *Demetris Patsios* | Moderator: *Demetris Patsios* (Salle de bal Est)

08:00 – 17:00 Scientific and Educational Exhibits (PowerPoint Presentations – 4th Floor Foyer)

07:30 – 08:00 Breakfast (Salle de bal Centre)

08:00 – 08:40 **Plenary: The Incidental Findings Conundrum and Integrating the ACR Recommendations Into Practice – Alec Megibow** (Salle de bal Ouest)

Track Title *Moderator(s)* (Location)	Back to Basics – Chest *Carolina Souza* (Salle de bal Ouest)	Gynecology *Patricia Noël* (Salle de bal Est)
08:45 – 09:15	That Blurry, Beating Bag of Blood: The Heart on Radiograph and Non-Gated Thoracic Imaging – *Mark Landis*	Practical Approach to Ultrasound Evaluation of Cystic Adnexal Masses – *Laurence Péloquin*
09:15 – 09:45	Interstitial Lung Disease: Don't Panic! – *Carolina Souza*	Imaging of the Endometrium – *Tanya Chawla*
09:45 – 10:15	Pulmonary Infection – *Ana-Maria Bilawich*	Benign Uterine Conditions and Management Options – *Alison Harris*

10:15 – 10:40 Nutrition Break

Track Title *Moderator(s)* (Location)	Back to Basics – Head & Neck *Eugene Yu* (Salle de bal Ouest)	How I Do It – Live Action *Phyllis Glanc* (Salle de bal Est)	Departmental Clinical Audit Project Contest *Pascale Audet* (Salon 1)
10:45 – 11:15	Temporal Bone Imaging: Hear It to Master It – *Girish Fatterpekar*	Obstetrical Ultrasound: The Second Trimester – *Ants Toi*	Judges: *Carl Chartrand-Lefebvre* *Najla Fasih* *Ur Metser*
11:15 – 11:45	Head and Neck Case Review: Cases Referred From Outside Non-Specialist MDs – *Eugene Yu*	How I Perform an Ultrasound of the Abdomen – *Laurent Milot*	
11:45 – 12:15	Head and Neck Case Emergencies: Should I Call the Surgeon? – *Manon Bélair*	Transthoracic Ultrasound: What Every Radiologist Should Know – *Samer Dabbo* (11:45–11:55) What to Do When Everything Goes Wrong – *Ivan Diamond* (11:55–12:10)	

12:15 – 13:25 Lunch – CAR and CRF Annual General Meetings

12:15 – 13:25 Exhibits

Track Title *Moderator(s)* (Location)	**Back to Basics – Body Imaging** *Tanya Chawla* (Salle de bal Ouest)	**Young Radiologists** *Raquel del Carpio-O'Donovan* (Salle de bal Est)	**CAR Radiologists-in-Training Awards** *Micheline Thibodeau* (Salon 1)
13:30 – 14:00	An Approach to Pancreatic Lesions – *Alec Megibow*	Continuing Professional Development: Where Are We Going, and Why Should I Care? – *Sam Daniel*	Judges: *Pavel Crystal* *Angus Hartery* *Matthew McInnes*
		Preparation for Academic Promotion – *Carlos Torres*	
14:00 – 14:30	An Approach to Renal Lesions – *Martin O'Malley*	Leadership Roles – *Benoît Gallix*	
14:30 – 15:00	An Approach to Liver Lesions – *An Tang*	Work-Life Balance and Happiness at Work – *Patrice Bret*	

15:00 – 15:25 Nutrition Break

Track Title *Moderator(s)* (Location)	**Back to Basics – Pediatric** *Benvon Cramer* (Salle de bal Ouest)	**The Thinking Radiologist** *Christina Chingkoe / Michael Martin* (Salle de bal Est)	**CAR Radiologists-in-Training Awards** *Micheline Thibodeau* (Salon 1)
15:30 – 16:00	Pediatric: Neuroradiology – *Ravi Bhargava*	Jeopardy: Radiology Style Game Hosts: *Christina Chingkoe, Phyllis Glanc, Ali Jahed*	Judges: *Pavel Crystal* *Angus Hartery* *Matthew McInnes*
16:00 – 16:30	Pediatric: Body Imaging – *Kathy O'Brien*	Debate: Should Structured Reporting Be Mandatory? Panelists: *Gus Dotsikas, Jonathon Leipsic, Alec Megibow, Joseph O'Sullivan*	
16:30 – 17:00	Pediatric: MSK Imaging – *Benvon Cramer*		

17:30 – 18:15 Very Important Volunteer (VIV) Recognition Event

18:30 – 22:00 Annual Dinner and Awards Gala

Sunday, April 27, 2014

07:30 – 08:00 Breakfast (Salle de bal Centre)

Track Title *Moderator(s)* (Location)	**Mistakes We All Make** *Caitlin McGregor* (Salle de bal Ouest)
08:00 – 08:30	Neuroradiology – *Mathias Schmidt*
08:30 – 09:00	Abdominal Imaging – *Chirag Patel*
09:00 – 09:30	Chest – *Yannick Cartier*
09:30 – 10:00	Musculoskeletal – *Robert Bleakney*

10:15 – 10:40 Nutrition Break

Track Title *Moderator(s)* (Location)	**Slipping Through the Cracks and Into the Courtroom: A Mock Trial presented by the CMPA** *Steven Bellemarre* (Salle de bal Ouest)
10:30 – 12:00	CMPA Experts: *Steven Bellemare* and *Anika Clark*, assisted by: *Brieanne Brannagan* and *Mark Faassen* and Radiologist Actors: *Bruce Forster, Matthew McInnes, Jana Taylor*

Presentations

Présentations

Welcoming Address – Thursday, April 24, 2014

Welcoming Address by Dr. Jacques Lévesque, President of the CAR

With words of welcome from Dr. Reed Dunnick, President of the Radiological Society of North America
19:00 – 19:20: Salle de bal Ouest

Opening Lecture – Thursday, April 24, 2014

Patient-Centered Radiology: The Right Thing for the Right Patient at the Right Time

Dr. Ella Kazerooni
19:20 – 20:00: Salle de bal Ouest

This presentation will be 35 minutes, followed by a 5-minute interactive question period.

PRESENTATION SUMMARY: Historically, diagnostic radiologists focused on the quality and safety of performing and interpreting examinations, with little thought to their role and responsibilities to patients, families and providers before and after the examinations. Patient and family-centered care (PFCC) is increasingly recognized as a way to engage patients and families in the care they are receiving by seeing the care through their eyes, emotions and needs. By working together in partnership, the quality and safety of healthcare improve, costs decrease, and provider and patient satisfaction increase. In this presentation, we will discuss what PFCC is, what the benefits are, and importantly, how to get started in your own practice.

LEARNING OBJECTIVES: At the end of this session, participants should be able to:

1. Define the scope of the radiologist's responsibilities in patient care – beyond a diagnostic test itself.
2. Identify what patient and family-centered care (PFCC) is and the benefits to a radiology operation of incorporating PFCC into daily processes and decision making.
3. Apply strategies for incorporating patient and family-centered care into radiology practice.

Morning Tracks – Friday, April 25, 2014

Case of the Day – MSK and Neuroradiology

Dr. Haron Obaid / Dr. Carlos Torres
07:30 – 08:00: Salle de bal Est
Moderator: Dr. Demetris Patsios

These presentations will be 12 minutes, followed by 3-minute interactive question periods.

PRESENTATION SUMMARY: An unknown set of cases will be presented and will consist of a clinical history and relevant imaging. The findings and diagnoses and differential diagnoses will be reviewed. Relevant teaching points specific to the cases will be shown.

LEARNING OBJECTIVES (MSK): At the end of this session, participants should be able to:

1. Analyze imaging findings on multiple modalities of the MSK system.
2. Develop differential diagnoses based on the clinical information and imaging findings.
3. Recommend appropriate management for patients based on imaging findings.

LEARNING OBJECTIVES (NEURORADIOLOGY): At the end of this session, participants should be able to:

1. Recognize key imaging findings that lead to the diagnosis of the Case of the Day.
2. Form appropriate differential diagnoses based on clinical information and imaging findings.
3. Recognize the clinical implications of diagnoses.

Plenary Session: Patient Satisfaction and Service Excellence in Radiology

Dr. Ella Kazerooni
08:00 – 08:40: Salle de bal Ouest
Moderator: Dr. Carole Dennie

This presentation will be 35 minutes, followed by a 5-minute interactive question period.

PRESENTATION SUMMARY: Patients, families, third-party payers and healthcare providers increasingly recognize the role of patient satisfaction in healthcare today. The reason this is important and the role of radiology will be discussed.

LEARNING OBJECTIVES: At the end of this session, participants should be able to:

1. Recognize why patient satisfaction is important in radiology.
2. List the types of metrics used to evaluate patient satisfaction.
3. Pinpoint how a service excellence program elevates patient satisfaction.

The Right Thing

08:45 – 12:15: Salle de bal Ouest
Moderator: Dr. Michael Martin

APPROPRIATE USE OF IMAGING IN CANADA

Dr. James Fraser 08:45 – 09:15

PRESENTATION SUMMARY: The data available regarding the appropriateness of imaging in Canada will be briefly discussed, along with the relevance of appropriateness in imaging and what are the driving forces that affect appropriate use of imaging resources in Canada. Also, the important role of individual radiologists and of the profession in taking a proactive approach to ensure appropriate use of Canada's imaging resources will be discussed.

LEARNING OBJECTIVES: At the end of this session, participants should be able to:

1. Relate to the present state of evidence regarding appropriateness of imaging in Canada.
2. Describe the drivers affecting appropriateness of imaging in Canada.
3. Assess the importance of imaging appropriateness for a sustainable Canadian healthcare system.
4. Reflect on their role as radiologists in the appropriate use of imaging in Canada.

TELERADIOLOGY: IS APPROPRIATENESS IMPACTED?

Dr. Gregory Butler 09:15 – 09:45

PRESENTATION SUMMARY: The advent of remote transmission and interpretation of medical images has raised professional questions regarding ethics, politics, economics and quality. Long since the maturation of the technology, there remain questions about the quality achievable in off-site radiology interpretation.

This lecture will summarize the known potential quality pitfalls in off-site radiology professional service, with an emphasis on both the technical and professional imperatives that must be met to allow the promise of a service that is not only as good as that of an on-site radiologist, but in some cases better. The critical role that teleradiology can play in the design and deployment of the most advanced new ideas in radiologist peer review will be explored.

LEARNING OBJECTIVES: At the end of this session, participants should be able to:

1. Distinguish the similarities and differences between on-site and off-site (teleradiology) radiology practice.
2. Identify potential quality pitfalls in teleradiology in both technical and professional parameters.
3. Generate ideas for optimization of teleradiology to become a useful tool for improved radiology practice.
4. Evaluate how remote radiology services can improve patient care, referring physician satisfaction, and help preserve the professional future of radiology.
5. Identify the signs to watch for which will warn of teleradiology service design that can be a threat to quality practice as well as to the practice of radiology.
6. List new ideas and trends in radiologist peer review which utilize teleradiology. These can achieve prospective, anonymous and cross-platform case distribution to maximize patient safety and radiologist comfort, thereby turning peer review into a powerful quality process rather than a policing threat.

WHO IS ACCOUNTABLE FOR THE APPROPRIATENESS OF STUDIES: THE RADIOLOGIST OR THE REFERRING PHYSICIAN OR BOTH?

Dr. Ella Kazerooni 09:45 – 10:15

PRESENTATION SUMMARY: The appropriateness of diagnostic testing and interventional radiology procedures is a key quality metric for a radiology operation. Radiologists have a professional responsibility to ensure that the tests they perform and interpret are appropriately used. Appropriateness should be considered in both settings of inappropriate overutilization and underutilization. Rather than conforming to the historically negative perspective of radiologists as gatekeepers, radiologists should be partners in patient care with providers, using an evidence-based approach as part of care management programs to minimize the risk and costs associated with inappropriate utilization patterns.

LEARNING OBJECTIVES: At the end of this session, participants should be able to:

1. Define "appropriate" in the context of radiology examinations.
2. Identify the pros and cons of a referring provider vs. a radiologist's approach to appropriateness.
3. Recognize the tools available to radiologists in determining the appropriateness of imaging.

Morning Tracks – Friday, April 25, 2014

POINT OF ORDER DECISION SUPPORT

Dr. Martin Reed 10:45 – 11:15

PRESENTATION SUMMARY: Referral guidelines for radiology are available in various formats: booklets, CDs, the Internet and as part of computerized order entry systems (CPOE). In this presentation, these various formats and their advantages and disadvantages will be discussed. The primary focus of the talk will be on the provision of guidelines at the point of care as part of a CPOE, including lessons learned from pilot projects with CPOEs, important features of CPOEs with decision support and information about systems which are currently available.

LEARNING OBJECTIVES: At the end of the presentation, participants should be able to:

1. Identify the various formats for imaging referral guidelines.
2. List the advantages and disadvantages of each.
3. Assess the potential role for a CPOE with radiology decision support in his or her practice setting.

IMAGING APPROPRIATENESS IN PREGNANCY: WHAT TO CHOOSE, WHEN AND WHY

Dr. Phyllis Glanc 11:15 – 11:45

PRESENTATION SUMMARY: Imaging appropriateness in pregnancy is underpinned by the following three critical keywords: justification (or appropriate indications); optimization (of imaging dose); and limitation (only do what is necessary). Although these guidelines apply to all patients, they are particularly important in the setting of the developing embryo/fetus. The known bioeffects of ultrasound, CT, MRI, radiographs and associated contrast agents will be discussed. With this knowledge, the lecturer will then review common clinical situations that may arise during pregnancy and apply appropriate imaging algorithms to them.

LEARNING OBJECTIVES: At the end of this session, participants should be able to:

1. Demonstrate the effects of radiation exposure on the fetus.
2. Assess the effects of contrast agent administration during pregnancy.
3. Recommend appropriate imaging pathways in common clinical scenarios that occur in the pregnant patient.

OSTEOPOROTIC VERTEBRAL FRACTURES

Dr. Brian Lentle 11:45 – 12:15

PRESENTATION SUMMARY: Recent reviews have pointed out the absence of agreed-upon criteria by which to diagnose vertebral fractures. The methods proposed will be reviewed and illustrated. Their limitations will be discussed and a practical clinical solution to the dilemma will be suggested.

LEARNING OBJECTIVES: At the end of this session, participants should be able to:

1. Measure the importance of osteoporotic vertebral fractures in future fracture risk estimation.
2. Identify poor evidentiary basis concerning methods for diagnosing osteoporotic vertebral fractures.
3. Develop a practical approach to diagnosis in this context.

Morning Tracks – Friday, April 25, 2014

Resident Review

08:45 – 12:15: Salle de bal Est
Moderator: Dr. Neety Panu

PRESENTATION SUMMARY: The CAR is proud to present the annual case-based Resident Review session. This radiology overview is targeted to residents and clinical fellows, as well as to practicing radiologists interested in updating their working knowledge by covering major radiology subspecialties.

This case-based Resident Review session highlights the fundamentals of imaging of the major organ systems using different imaging modalities. Lecture content will focus on the review of a number of cases to provide attendees with the knowledge of appropriate use of radiological terminology, give attendees the most common (or important) differential diagnoses and provide them with an algorithm of multi-imaging modalities to arrive at the most appropriate diagnosis.

An emphasis will be placed on what the graduating resident "needs to know".

LEARNING OBJECTIVES: At the end of these sessions, participants should be able to:

1. Diagnose common pathologies as seen on a variety of imaging modalities.
2. Discuss the differential diagnoses of common pathologies in the following subcategories: chest, abdomen, pediatric, musculoskeletal, vascular/interventional, neuroradiology and nuclear medicine.
3. Describe key points of common radiological diagnoses.

The following highly respected and accomplished radiologists will be presenting the Resident Review session:

CHEST: Dr. Carolina Souza 08:45 – 09:15

MAMMOGRAPHY: Dr. Neety Panu 09:15 – 09:45

ADBOMINAL MRI: Dr. Laurence Péloquin 09:45 – 10:15

MUSCULOSKELETAL: Dr. Anukul Panu 10:45 – 11:15

ULTRASOUND: Dr. Shia Salem 11:15 – 11:45

PEDIATRIC: Dr. Heather Bray 11:45 – 12:15

For the afternoon portion of the Resident Review, please refer to page 40.

Live Ultrasound Simulation Workshop – Approach to Ankle Tendons & Ligaments

08:45 – 12:15
Dr. Mark Cresswell, Dr. Gina Di Primio, Dr. Karen Finlay, Dr. Viviane Khoury, Dr. Linda Probyn, Dr. Marcos Sampaio

As part of the program, a special MSK Live Ultrasound Simulation Workshop is offered to those who signed up when registering for the meeting.

The workshop begins with a 45-minute didactic segment, followed by 135 minutes of hands-on simulation experience, working with live models.

PRESENTATION SUMMARY: This "hands-on" workshop is a practical session where participants familiarize themselves with MSK ultrasonographic technique and practical application.

LEARNING OBJECTIVES: At the end of this workshop, participants should be able to:

1. Describe normal sonographic anatomy.
2. Identify the ultrasound appearances of common musculoskeletal pathology.
3. Correlate clinical problems with imaging findings.

Afternoon Tracks – Friday, April 25, 2014

Acute Abdominal Pain: Don't Investigate the Patient to Death

13:30 – 15:00: Salle de bal Ouest
Moderator: Dr. Michael Patlas

Each of the following four presentations are 20 minutes, including an interactive audience response of 2 minutes. Each presentation will also be followed by a 2-minute interactive question period.

RIGHT UPPER QUADRANT PAIN

Dr. Silvia Chang 13:30 – 13:52

PRESENTATION SUMMARY: Acute right upper quadrant (RUQ) pain is a common symptom in patients presenting to the emergency department. Although there are multiples causes of acute RUQ pain, the main diagnostic concern is acute cholecystitis, a potentially life-threatening condition. Imaging plays an important role in establishing this diagnosis, as clinical exam, physical exam and laboratory tests do not provide sufficient diagnostic certainty to determine management in these cases. Appropriate use of imaging tests is also important to establish a timely diagnosis of acute cholecystitis or an alternative diagnosis.

The most appropriate initial imaging modality in assessing the patient with acute RUQ pain is US. Cholescintigraphy can also be used in the setting of suspected acute cholecystitis or in equivocal US cases. CT and MRI can be helpful for indeterminant US cases or to assess for complications of acute cholecystitis or an alternative diagnosis. Other common causes of acute RUQ pain arising from the hepatobiliary system include cholelithiasis, choledocholithiasis and ascending cholangitis. Extra-hepatic causes include pancreatitis, GI tract (peptic ulcer disease, diverticulitis) and GU tract (pyelonephritis, obstructive uropathy). Some less common causes include hepatic abscess, ruptured hepatic adenoma, ruptured HCC, portal vein thrombosis, pulmonary system (pneumonia) and cardiac system (ACS).

LEARNING OBJECTIVES: At the end of this session, participants should be able to:

1. Develop an approach to the acute presentation of right upper quadrant (RUQ) pain.
2. Identify the advantages and disadvantages of various imaging modalities in the investigation of the patient with acute RUQ pain, with reference to the American College of Radiology (ACR) appropriateness criteria.
3. Interpret the imaging appearances of common, and uncommon, causes of RUQ pain.

LEFT UPPER QUADRANT PAIN

Dr. Michael Patlas 13:52 – 14:14

PRESENTATION SUMMARY: Multiple acute conditions can cause left upper quadrant (LUQ) pain. The presentation will be focused on numerous non-traumatic splenic emergencies presenting as acute LUQ pain. Occasionally, patients are investigated for symptoms of suspected splenic pathology (abscess, infarct, symptomatic splenic aneurysm and pseudoaneurysm, splenic torsion or rupture). However, more often, splenic emergencies (splenic masses, splenic vein thrombosis) are detected in emergency patients during evaluation of non-specific LUQ abdominal pain. Appropriate choice of imaging modalities and techniques and management options will be discussed.

LEARNING OBJECTIVES: At the end of this session, participants should be able to:

1. Identify the factors affecting LUQ lesion detection on multiple imaging modalities.
2. List the advantages of different cross-sectional modalities and techniques for diagnosis of conditions causing acute LUQ pain.
3. Consider management options in different conditions causing LUQ pain with emphasis on interventional radiology.

RIGHT LOWER QUADRANT PAIN

Dr. Mostafa Atri 14:14 – 14:36

PRESENTATION SUMMARY: Imaging of acute right lower quadrant pain is a common indication for imaging of ER patients. The most appropriate first imaging modality is ultrasound (US), both because of lack of radiation and absence of patient contact that would help identify the cause of pain. Most premenopausal women presenting with acute lower quadrant pain have a gynecological cause for their pain requiring US for proper diagnosis. US is accurate in diagnosing acute appendicitis and determining its complications. However, CT is required for planning abscess drainage. Although a normal appendix is not as frequently identified on US as on CT, patient contact helps determine the need for CT if normal appendix is not identified. Other causes of acute lower quadrant pain, such as diverticulitis, appendagitis and omental infarcts generally have point tenderness that helps the sonographer identify the cause of pain.

LEARNING OBJECTIVES: At the end of this session, participants should be able to:

1. Adopt a practical approach to imaging of acute lower quadrant pain.
2. Identify CT and US findings that increase specificity of detection of acute appendicitis.
3. Determine non-appendicitis causes of acute lower quadrant pain.

LEFT LOWER QUADRANT PAIN

Dr. Ania Kielar 14:36 – 15:00

PRESENTATION SUMMARY: Left lower quadrant (LLQ) pain is a common reason for patients to present to the emergency department. All imaging modalities including radiographs, sonography, CT and MRI have a role in imaging patients with acute LLQ pain.

Patient age and pretest probability should be considered when choosing an imaging modality while keeping the premise of ALARA (as low as reasonably achievable) and the Image Wisely campaign in mind. For example, sonography can be a useful starting point for imaging acute LLQ pain. This is particularly true in younger patients and in women, since it does not expose patients to radiation and it can be used to diagnose many conditions presenting with LLQ pain. Taking advantage of some of the helpful artifacts in sonography can be of benefit (e.g., Twinkling artifact for renal calculi and dirty shadowing for free air).

As a CanMEDS manager of the patient's imaging, the radiologist should be prepared to use more than one imaging modality if the cause of LLQ pain cannot be determined with the initial study performed.

LEARNING OBJECTIVES: At the end of this session, participants should be able to:

1. List the strengths and weaknesses of each imaging modality with respect to patients presenting with LLQ pain.
2. Employ appropriate imaging to investigate left lower quadrant pain with emphasis on Imaging Wisely.
3. Address CanMEDS roles of medical expert, manager, communicator and collaborator when dealing with patients presenting with acute LLQ pain.

Resident Review

13:30 – 15:00: Salle de bal Est
Moderator: Dr. Neety Panu

PRESENTATION SUMMARY: Continuation of the case-based Resident Review session.

The following highly respected and accomplished radiologists will be presenting the Resident Review session:

NEURORADIOLOGY: Dr. Sandeep Naik 13:30 – 14:00

NUCLEAR MEDICINE: Dr. Petter Tonseth 14:00 – 14:30

INTERVENTIONAL RADIOLOGY: Dr. John Kachura 14:30 – 15:00

Afternoon Tracks – Friday, April 25, 2014

The Right Thing – Chest Imaging

15:30 – 17:00: Salle de bal Ouest
Moderator: Dr. Elsie Nguyen

Each of the following three presentations are 25 minutes, including an interactive audience response of 5 minutes. Each presentation will also be followed by a 5-minute interactive question period.

ACUTE CHEST PAIN IN THE EMERGENCY DEPARTMENT: ACUTE CORONARY SYNDROME

Dr. Elsie Nguyen 15:30 – 16:00

PRESENTATION SUMMARY: The presentation will provide the audience with a thorough overview of the current literature for the integration of cardiac CT in the emergency department (ED). This will include a review of the data from recent multicentre trials. An in-depth discussion regarding other ancillary testing performed in the ED for acute chest pain will follow.

LEARNING OBJECTIVES: At the end of this session, participants should be able to:

1. Identify the current management of low-risk chest pain.
2. Analyze the randomized trial data supporting the integration of CCTA in the ED.
3. Discuss the pending consensus on appropriate use guidelines for imaging of acute chest pain in the ED.

THE RIGHT TEST AT THE RIGHT TIME: ACUTE PULMONARY EMBOLISM

Dr. Elena Peña 16:00 – 16:30

PRESENTATION SUMMARY: This lecture will provide a comprehensive review of the different diagnostic pathways used to diagnose acute pulmonary embolism. A current list of guidelines for special patient groups will also be provided. Clinical scenarios will be explored, followed by frequently asked questions and answers.

LEARNING OBJECTIVES: At the end of this session, participants should be able to:

1. Identify the imaging algorithm for the diagnosis of suspected acute pulmonary embolism.
2. Review the current guidelines for special patient groups.

PRACTICE GUIDELINES FOR MANAGEMENT OF SOLID AND SUBSOLID NODULES

Dr. Anastasia Oikonomou 16:30 – 17:00

PRESENTATION SUMMARY: Small pulmonary nodules of <4 mm, increasingly detected incidentally or at screening on MDCT, have a likelihood of malignancy of <1%. Specific guidelines for solid nodules have been implemented in order to avoid unnecessary imaging and radiation burden, based on morphologic criteria and the patient's risk profile. The need for further specification of guidelines applied to subsolid nodules emerged as adenocarcinoma proved to be the most frequent histological subtype of lung cancer. Furthermore, according to new classification of lung adenocarcinoma, specific subtypes with a near 100% survival rate with complete resection, may present on CT as subsolid nodules, rendering CT characterization of a nodule crucial for prognosis and management. For subsolid nodules, specific time intervals for follow-up are recommended based on classification of nodules as "pure-GGO", "part-solid" and "multiple", with or without a dominant lesion.

LEARNING OBJECTIVES: At the end of this session, participants should be able to:

1. Use appropriate terminology for solid and subsolid nodules and further classify them according to morphologic characteristics and the patient's risk profile.
2. Integrate in clinical practice updated knowledge about solid and subsolid nodules regarding radiology-pathology correlation, different prognosis, alternatives of management and probability of malignancy.
3. Apply specific guidelines for management and follow-up of solid and subsolid nodules according to evidence-based practice guidelines.

Afternoon Tracks – Friday, April 25, 2014

Breast Imaging

15:30 – 17:00: Salle de bal Est
Moderator: Dr. Shiela Appavoo

BREAST ULTRASOUND SCREENING

Dr. Derek Muradali 15:30 – 16:00

PRESENTATION SUMMARY: Screening breast ultrasound is being performed with increasing frequency in many jurisdictions in North America. In several locations, these studies are being promoted as a necessary screening test, on a population basis, regardless of individual breast cancer risk. However, there is concern that the evolution of screening breast ultrasound in this direction is based on opinion rather than on current medical evidence. The precise indications and role of screening breast ultrasound have therefore become controversial. This talk will discuss potential harms and benefits of screening breast ultrasound as well as suggest appropriate guidelines for its use.

LEARNING OBJECTIVES: At the end of this session, participants should be able to:

1. Determine the proper sonographic technique.
2. Define the potential benefits and harms of the test.
3. Adopt guidelines regarding its use.

BREAST MRI: WHEN IS IT NOT USEFUL?

Dr. Jean Seely 16:00 – 16:30

PRESENTATION SUMMARY: Breast MRI is a technique that has gained wide acceptance for clinical use. Although it is the most sensitive diagnostic test for breast cancer, breast MRI is not appropriate in some clinical situations. The talk will outline clinical indications where MRI should not be used, and focus on the clinical situations where it is appropriate, while providing an example of how a change in practice was achieved at The Ottawa Hospital. By the end of the presentation, participants will be familiar with the clinical indications for ordering breast MRI and understand the reasons for not ordering the test when not indicated.

LEARNING OBJECTIVES: At the end of this session, participants should be able to:

1. Identify the limitations of breast MRI in the preoperative setting.
2. Apply guidelines for high-risk screening with breast MRI to clinical practice.
3. Assess clinical situations where breast MRI should not be used.

WOMEN AGED 40–49: THE CASE IN FAVOUR OF SCREENING

Dr. Nancy Wadden 16:30 – 17:00

PRESENTATION SUMMARY: There is controversy surrounding the screening of women aged 40 to 49. Randomized control trials conducted (RCT) from the 1960s to the 1980s concluded that mortality was reduced by 15–20%, although individual trials did not show a statistically significant mortality reduction.

In November 2011, the Canadian Task Force on Preventive Health Care recommended against mammographic screening in this age group for women of average risk. While the Task Force considered only RCT in assessing the benefits of screening, it considered observational studies in assessing its harms of screening.

Factors such as improved quality of mammography and knowledge around mammographic interpretation might have rendered these trials irrelevant today. The mammograms previously used to determine their effectiveness for early detection of breast cancer bear no resemblance to modern mammograms. Current service screening and cohort studies report that for women who attended screening, the relative risk of mortality was 0.71, indicating a significant mortality reduction from breast cancer screening.

Another factor when considering screening for women aged 40–49 is the years of potential life gained. Because of women's longer life expectancy, more years of life are lost due to premature death in this age group. It is estimated that 40% of potential years of life lost to breast cancer occurs in women diagnosed before age 50. The division of age groups at 50 is artificial, as breast cancer incidence gradually increases with age.

LEARNING OBJECTIVE: At the end of this session, participants should be able to:

1. Recognize and analyze the pros and cons for screening women aged 40 to 49.

Afternoon Tracks – Friday, April 25, 2014

Resident Hot Seat Sessions

15:30 – 17:00
Dr. Julie Hurteau-Miller, Dr. Neety Panu, Dr. R. Petter Tonseth

Small group sessions for radiology residents who have pre-registered for this opportunity. Restricted attendance.

PRESENTATION SUMMARY: These sessions provide participating residents with a foundation for approaching cases in a "hot seat" setting in preparation for various examinations. All areas of radiology will be covered. Each resident will receive at least four training-appropriate cases. The cases will be discussed and feedback will be given.

LEARNING OBJECTIVES: At the end of this session, participating residents should be able to:

1. Assimilate and apply pertinent differential diagnoses in radiology related to the sample cases.
2. Apply a patterned approach to radiographic disease via a case-based approach.
3. Analyze feedback received from the moderators and use it to improve skills while interpreting cases orally.

Morning Tracks – Saturday, April 26, 2014

Case of the Day – Body and Chest

Dr. Errol Colak / Dr. Demetris Patsios
07:30 – 08:00: Salle de bal Est
Moderator: Dr. Demetris Patsios

These presentations will be 12 minutes, followed by 3-minute interactive question periods.

PRESENTATION SUMMARY: An unknown set of cases will be presented and will consist of a clinical history and relevant imaging. The findings and diagnoses and differential diagnoses will be reviewed. Relevant teaching points specific to the cases will be shown.

LEARNING OBJECTIVES (BODY): At the end of this session, participants should be able to:

1. Analyze imaging findings on a variety of body imaging studies.
2. Form appropriate differential diagnoses based on clinical information and imaging findings.
3. Recognize the clinical implications of diagnoses.

LEARNING OBJECTIVES (CHEST): At the end of this session, participants should be able to:

1. Analyze imaging findings on a variety of chest imaging studies.
2. Develop differential diagnoses based on the clinical information and imaging findings.
3. Recognize the clinical implications of diagnoses.

Plenary Session: The Incidental Findings Conundrum and Integrating the ACR Recommendations Into Practice

Dr. Alec Megibow
08:00 – 08:40: Salle de bal Ouest
Moderator: Dr. Carole Dennie, Chair of the CAR 77th Annual Scientific Meeting

This presentation will be 35 minutes, followed by a 5-minute interactive question period.

PRESENTATION SUMMARY: Incidental findings detected on cross-sectional imaging studies can be considered as an adverse outcome of the study. Although they can be beneficial (silent hydronephrosis, aortic aneurysms, early lung cancer), many more can actually be detrimental as they result in additional imaging or intervention, often with little patient benefit. Radiologists feel uncomfortable with the uncertainty generated by these findings and therefore are in the uncomfortable position of recommending further evaluation. The American College of Radiology (ACR) put together several teams to evaluate a variety of incidental findings encountered in abdominal imaging. Delphic consensus based on literature review generated a series of recommendations in the form of flow charts that can aid radiologists in deciding how to adjudicate an incidental finding. Review of these flow charts and a discussion of how they have been implemented in clinical practice will be provided. Finally, the concept of the indolent lesions of epithelial origin (IDLE) tumor will be introduced.

LEARNING OBJECTIVES: At the end of this session, participants should be able to:

1. Describe the clinical impact created by incidental findings.
2. Implement strategies available to radiologists to minimize requests for additional imaging.
3. Recognize the creation process and implementation of the ACR recommendations.

Morning Tracks – Saturday, April 26, 2014

Back to Basics – Chest

08:45 – 10:15: Salle de bal Ouest
Moderator: Dr. Carolina Souza

Each of the following three presentations are 20 minutes, including an interactive audience response of 5 minutes. Each presentation will also be followed by a 5-minute interactive question period.

THAT BLURRY BEATING BAG OF BLOOD: THE HEART ON RADIOGRAPHY AND NON-GATED THORACIC IMAGING

Dr. Mark Landis 08:45 – 09:15

PRESENTATION SUMMARY: This presentation will review the common cardiac findings one can make on general radiography and on routine non-gated thoracic computed tomography (CT).

It is the intention that after this presentation, the learner will emerge with a greater awareness of the types of findings one can make by careful evaluation of the heart and pericardium using these modalities.

LEARNING OBJECTIVES: By the end of this session, participants should be able to:

1. Identify common cardiac findings on basic radiography.
2. Identify common cardiac findings on routine non-gated thoracic CT.
3. Integrate how these findings may be relevant to the patient's current presentation.

INTERSTITIAL LUNG DISEASE: DON'T PANIC!

Dr. Carolina Souza 09:15 – 09:45

PRESENTATION SUMMARY: Interstitial lung diseases (ILDs) comprise a heterogeneous group of diseases affecting the lungs. ILDs have variable clinical manifestations, treatment and prognosis and may be acute (cardiogenic pulmonary edema, atypical infection) or chronic (idiopathic and secondary fibrotic lung diseases, diseases caused by environmental exposure). Lymphangitic carcinomatosis also presents with an interstitial pattern secondary to malignant involvement of the interstitium.

High-resolution CT is the imaging modality of choice in the diagnosis of ILD. Chest radiograph is limited in the detection and characterization of ILD; however, it is often the first imaging exam performed and may provide important information to guide management.

Imaging diagnosis of ILD is based mainly on pattern recognition and distribution of the abnormalities. Correlation with clinical findings often allows a presumptive diagnosis, precluding the need for additional diagnostic procedures. Conversely, pathological-radiological correlation has been proven critical in the final diagnosis of ILD, providing important information to pathologists. Radiologists must therefore be familiar with the most common ILDs and their imaging manifestations.

LEARNING OBJECTIVES: At the end of this session, participants should be able to:

1. Recognize the role of chest radiograph in the management of ILD.
2. Identify the typical HRCT manifestations of the most relevant ILD.
3. Adopt a systematic approach for the imaging diagnosis of ILD.

PULMONARY INFECTION

Dr. Ana-Maria Bilawich 09:45 – 10:15

PRESENTATION SUMMARY: Imaging plays a very important role in the detection and management of patients with pneumonia. Knowledge of the clinical setting, in combination with the CT pattern of involvement, is the best approach to the pulmonary infectious process. CT pattern approach is useful in differentiating pulmonary infection from non-infectious pulmonary disease. CT is useful in identifying complications of pneumonias.

LEARNING OBJECTIVES: At the end of this session, participants should be able to:

1. Recognize the broad range of potential radiographic findings of pulmonary infection. (CanMEDS Role: Medical Expert)
2. Utilize a CT pattern approach to differentiate pulmonary infection from non-infectious pulmonary disease, recognizing the importance of the clinical setting. (CanMEDS Role: Medical Expert)
3. Identify the complications of pneumonias. (CanMEDS Role: Medical Expert)

GYNECOLOGY

08:45 – 10:15: Salle de bal Est
Moderator: Dr. Patricia Noël

PRACTICAL APPROACH TO ULTRASOUND EVALUATION OF CYSTIC ADNEXAL MASSES

Dr. Laurence Péloquin 08:45 – 09:15

PRESENTATION SUMMARY: During the presentation, participants will review the proper recommended ultrasound techniques for evaluating adnexal cysts, required patient information for adequate management (including age and menopausal status), as well as normal adnexal anatomy.

Ultrasound features of adnexal cysts that must be evaluated to determine the malignancy risk, including size, internal cyst content, wall thickness, septations, solid nodule and ascites will be demonstrated using multiple ultrasound images. Common pitfalls will be highlighted.

Appropriate and clear recommendations for follow-up ultrasound and immediate complementary evaluation with MRI or surgical consultation will also be reviewed.

LEARNING OBJECTIVES: At the end of this session, participants should be able to:

1. Identify the patient's factors that influence management of an adnexal cyst.
2. Identify the features that characterize simple, indeterminate and malignant adnexal cysts. (CanMEDS Role: Medical Expert)
3. Analyze the features of an indeterminate adnexal cyst that suggest it can be safely followed with imaging rather than surgically removed.
4. Provide appropriate recommendations for follow-up ultrasound, immediate complementary evaluation with MRI or surgical consultation. (CanMEDS Role: Collaborator)

IMAGING OF THE ENDOMETRIUM

Dr. Tanya Chawla 09:15 – 09:45

PRESENTATION SUMMARY: Ultrasound remains the primary diagnostic modality for assessment of the endometrium in both asymptomatic individuals as well as in patients with dysfunctional uterine bleeding. This presentation will focus on the current approach to assessment of the endometrium and the role of modalities other than ultrasound in the work-up of these patients.

The presentation will be illustrated with a spectrum of normal and pathologic findings encompassing premenopausal, pregnant, post-partum and menopausal patients.

LEARNING OBJECTIVES: At the end of this session, participants should be able to:

1. Recognize normal and abnormal endometrial appearances on imaging.
2. Distinguish the patterns of endometrial disease.
3. Identify the role of imaging in evaluating the endometrium.

BENIGN UTERINE CONDITIONS AND MANAGEMENT OPTIONS

Dr. Alison Harris 09:45 – 10:15

PRESENTATION SUMMARY: MRI and ultrasound provide an excellent depiction of female pelvic anatomy and are the imaging modalities of choice for the accurate diagnosis of numerous benign gynecological conditions. Detection and characterization of leiomyomata and adenomyosis is performed routinely, and MRI plays an important role in stratifying patients into appropriate treatment options such as uterine fibroid embolization (UFE). MRI and US are also essential in the assessment and characterization of congenital uterine anomalies in patients presenting with delayed menarche or infertility.

LEARNING OBJECTIVES: At the end of this session, participants should be able to:

1. Identify the MRI and US appearances of congenital anomalies of the uterine corpus and cervix.
2. Distinguish the varying appearances of leiomyomata and adenomyosis with MRI and US.
3. Evaluate treatment options for benign uterine conditions with particular reference to UFE.

Morning Tracks – Saturday, April 26, 2014

Back to Basics – Head & Neck

10:45 – 12:15: Salle de bal Ouest
Moderator: Dr. Eugene Yu

Each of the following three presentations are 20 minutes, including an interactive audience response of 5 minutes. Each presentation will also be followed by a 5-minute interactive question period.

TEMPORAL BONE IMAGING: HEAR IT TO MASTER IT

Dr. Girish Fatterpekar 10:45 – 11:15

PRESENTATION SUMMARY: The temporal bone is considered to be a complex anatomical structure. It is perhaps related to the multispatial orientation of multiple tiny structures in a very small compact area. Utilization of 3-D software can help better understand this spatial relationship. This can then be applied to cross-sectional CT imaging, helping to better understand its anatomy.

LEARNING OBJECTIVES: At the end of this session, participants should be able to:

1. Distinguish the 3-D appearance of multiple small structures which constitute the temporal bone.
2. Apply the 3-D appearance of these small structures to understand the anatomy of the temporal bone when evaluating cross-sectional CT images.
3. Evaluate certain common pathologies of the temporal bone.

HEAD AND NECK CASE REVIEW: CASES REFERRED FROM OUTSIDE NON-SPECIALIST MDs

Dr. Eugene Yu 11:15 – 11:45

PRESENTATION SUMMARY: The presentation will consist of three to four case-based scenarios involving head and neck pathology that were referred to a tertiary care hospital from non-specialist MDs. The history and physical examination findings of each case will be presented. Important key and distinguishing imaging features for each case will be highlighted and discussed, including the evaluation of perineural tumor spread, upstaging of sinonasal and laryngeal neoplasm, and skull base disease.

LEARNING OBJECTIVES: At the end of this session, participants should be able to:

1. Identify the critical imaging features in the assessment of sinonasal cancer.
2. Recognize radiographic features of perineural tumor spread in head and neck cancer.
3. Determine the best imaging studies to perform in the assessment of the types of head and neck pathology presented in selected case scenarios.

HEAD AND NECK CASE EMERGENCIES: SHOULD I CALL THE SURGEON?

Dr. Manon Bélair 11:45 – 12:15

PRESENTATION SUMMARY: Four cases will be presented that will highlight different head and neck emergency situations where the radiologist's input is mandatory for prompt and appropriate management. For each case, the clinical information, the imaging findings and the clinical management will be presented as an interactive session.

LEARNING OBJECTIVES: At the end of this session, participants should be able to:

1. Identify and discuss findings of acute head and neck conditions that necessitate immediate action.
2. Propose the right imaging protocol for the HN emergencies situation.
3. Identify complications.

Morning Tracks – Saturday, April 26, 2014

How I Do It – Live Action

10:45 – 12:15: Salle de bal Est
Moderator: Dr. Phyllis Glanc

OBSTETRICAL ULTRASOUND: THE SECOND TRIMESTER

Dr. Ants Toi 10:45 – 11:15

PRESENTATION SUMMARY: This is a live scan which will demonstrate the elements of the standard second trimester obstetrical ultrasound scan, including additional helpful views to demonstrate fetal anatomy.

LEARNING OBJECTIVES: At the end of this session, participants should be able to:

1. Summarize current CAR standards for second trimester obstetrical scans.
2. Apply techniques for obtaining standard views.
3. Define additional views which may be helpful.

HOW I PERFORM AN ULTRASOUND OF THE ABDOMEN

Dr. Laurent Milot 11:15 – 11:45

PRESENTATION SUMMARY: During this live ultrasound session, the audience will see a different approach regarding the ultrasonography of the liver, focusing specifically on spatial localization/use of vascular landmarks, which has daily application for tumor localization and staging, as well as intra-operative ultrasound and ablation. The key principles of bowel ultrasonography will also be highlighted.

LEARNING OBJECTIVES: At the end of this session, participants should be able to:

1. Apply advanced techniques to scan the liver on ultrasound.
2. Describe the segmental anatomy of the liver as seen on ultrasound and how this relates to cancer staging.
3. Apply principles of scanning the bowel with ultrasound.

TRANSTHORACIC ULTRASOUND: WHAT EVERY RADIOLOGIST SHOULD KNOW

Dr. Samer Dabbo 11:45 – 11:55

This presentation will be 8 minutes, followed by a 2-minute interactive question period.

PRESENTATION SUMMARY: Transthoracic ultrasound is emerging as a useful clinical tool for the assessment of patients. Advantages of this modality over traditional chest x-rays and computed tomography include a rapid portable assessment without ionizing radiation exposure.

For each diagnosis, the ultrasound findings will be correlated to chest X-ray and CT. Normal lung findings will be reviewed via static images and dynamic clips of A-lines, B-lines, lung sliding, and the "sea-shore sign". Abnormal ultrasound findings will include absence of lung sliding and "bar-code sign" in pneumothorax, increased B-lines in pulmonary edema, and "hepatization" of lungs in consolidation.

Finally, limitations of transthoracic ultrasound in detection of pathologies will be highlighted.

LEARNING OBJECTIVES: At the end of the session, participants should be able to:

1. Identify technical factors, probe selection and patient positioning to optimize assessment of the lung on transthoracic ultrasound.
2. Recognize normal lung ultrasound and associated artifacts.
3. Identify typical ultrasound findings in acute lung pathology such as pneumothorax, pleural effusions, alveolar consolidation, pulmonary edema and rib fractures.
4. Correlate transthoracic ultrasound pathology with chest X-ray and CT findings.

WHAT TO DO WHEN EVERYTHING GOES WRONG

Dr. Ivan Diamond 11:55 – 12:10

This presentation will be 13 minutes, followed by a 2-minute interactive question period.

PRESENTATION SUMMARY: This interactive session will focus on what to do "when everything goes wrong" and the radiologist is faced with managing a cardiac arrest in the out-patient ultrasound setting.

LEARNING OBJECTIVES: At the end of this session, participants should be able to:

1. Describe recent changes to the guidelines for the provision of basic life support (BLS) especially the change to CAB (Circulation, Airway Breathing) rather than ABC (Airway, Breathing, Circulation).
2. Provide basic life support (BLS) to a pulseless patient in an outpatient ultrasound setting.
3. Explain how to operate an automated external defibrillator (AED). (CanMEDS Role: Medical Expert)

Morning Tracks – Saturday, April 26, 2014

Departmental Clinical Audit Project Contest

10:45 – 12:15: Salon 1
Moderator: Dr. Pascale Audet
Judges: Dr. Carl Chartrand-Lefebvre, Dr. Najla Fasih, Dr. Ur Metser

The following abstracts will be presented orally. Please refer to the Abstract Section starting on page 78 for the full abstract.

Les abrégés suivants seront présentés oralement. Veuillez consulter la section des résumés d'expositions, à la page 78, pour en faire la lecture complète.

10:45 – AP001
Impact of Implementation of the Simplified Wells Criteria on Referrals for Pulmonary Embolism – *Michelle Ong*

10:55 – AP002
An Issue with Proximity: A Clinical Audit of Optic Lens Involvement in CT Head – *Paul S. Benvenuto*

11:05 – AP003
Ventilation/Perfusion Scans: Clinical Audit of Nondiagnostic Scans Following Wider Application of SPECT and Transition to Trinary Reporting – *Ashley Mummery*

11:15 – AP004
An Audit to Evaluate the Diagnostic Adequacy and Safety of Percutaneous Ultrasound Guided Pediatric Liver Biopsy – *Guan Huang*

11:25 – AP005
Adequate Completion of Radiology Request Forms – Are Referrers Helping Us to Help Them? – *Bhim J. Odedra*

11:35 – AP006
How Effective are Radiologists at Recommending Bone Mineral Densitometry in Patients with Fragility Fractures? – *Dean T. Jeffery*

11:45 – AP007
Radiation Reduction Using 80 kV and 100 kV Protocols for CT Pulmonary Angiography – *Edward M. Cheung*

11:55 – AP008
Clinical Audit of Thyroid Biopsy Adequacy – *Michael Kozoriz*

12:05 – AP009
Colonic and Extracolonic Findings of Computed Tomographic Colonography in a Non-Screening Canadian Population at an Academic Centre – *Amanzo Ho*

Afternoon Tracks – Saturday, April 26, 2014

Back to Basics – Body Imaging

13:30 – 15:00: Salle de bal Ouest
Moderator: Dr. Tanya Chawla

Each of the following three presentations are 25 minutes, including an interactive audience response of 5 minutes. Each presentation will also be followed by a 5-minute interactive question period.

AN APPROACH TO PANCREATIC LESIONS

Dr. Alec Megibow 13:30 – 14:00

PRESENTATION SUMMARY: Pancreatic imaging requires multiphasic protocols because of the differential blood supply to the pancreas (arterial) and liver (portal venous). Furthermore, optimal cross-sectional imaging requires the use of thin section acquisitions and the creation of appropriate 3-D imaging planes to best display data.

There is an alarming increase in the incidence of pancreatic cancer, with little change in long-term survival rates. Pancreatic phase acquisitions are critical for early detection; significant lesions detected on the pancreatic phase can rapidly become isodense 20 seconds later on venous phase. Radiologists should know peripancreatic vascular anatomy to properly assess the possibility of resectability. They should also know how to image the pancreatic duct, whether by MRCP or with CT, as segmental distension without mass may be the only clue to the presence of an otherwise curable lesion.

Considerable knowledge has accumulated in the past 15 years concerning the imaging appearances of pancreatic cysts. Cross-sectional imaging has increased cyst detection frequency. Therefore, radiologists must distinguish indolent from malignant cysts and have a rational basis for deciding when to follow or intervene on these lesions.

As there is a wide variety of pancreatic neoplasms, imaging features of the more common lesions (PNET and SPEN) will be reviewed.

LEARNING OBJECTIVES: At the end of the session, participants should be able to:

1. Describe the components of an optimal pancreatic protocol for detecting and staging pancreatic neoplasms.
2. Identify the imaging parameters used in assessing patient disease status at the time of presentation with specific focus on appropriateness for aggressive surgical management.
3. Recognize the significance of commonly encountered pancreatic cysts and suggestions for imaging surveillance.

AN APPROACH TO RENAL LESIONS

Dr. Martin O'Malley 14:00 – 14:30

PRESENTATION SUMMARY: A case-based, interactive, practical approach to the characterization of renal masses will be presented. With the appropriate use of US, CT, and/or MRI, most renal masses can be characterized. In some cases, a specific diagnosis cannot be achieved with imaging. However, imaging should allow for appropriate triage of cases. Small renal masses, in particular, present a challenge for diagnosis by imaging alone. In some cases, image-guided biopsy will be required to establish a diagnosis.

LEARNING OBJECTIVES: At the end of this session, participants should be able to:

1. Apply a practical approach to characterizing renal lesions.
2. Select the appropriate modality for renal lesion characterization.
3. Identify the approach to small renal masses.

AN APPROACH TO LIVER LESIONS

Dr. An Tang 14:30 – 15:00

PRESENTATION SUMMARY: Contrast-enhanced computed tomography and magnetic resonance imaging are frequently used for the non-invasive diagnosis of focal liver lesions. Likelihood of primary and secondary liver malignancy varies according to risk factors.

This presentation will provide an algorithmic approach to the classification of focal liver lesions. Emphasis will be on the distinction between cystic and solid lesions. Clinical history, morphological features, signal characteristics, and enhancement patterns that facilitate decision-making will be reviewed. A selection of cases with review of clinical history and imaging features will be presented, with an emphasis on key features that permit the correct diagnosis and proper management. Imaging findings from ultrasound, CT and MRI will be integrated.

LEARNING OBJECTIVES: At the end of this session, participants should be able to:

1. Explain the classification of cystic and solid liver lesions.
2. Integrate ultrasound, CT and MRI imaging features to reach a short differential diagnosis.
3. List some key imaging features that favour each differential diagnosis.

Afternoon Tracks – Saturday, April 26, 2014

Young Radiologists

13:30 – 15:00: Salle de bal Est
Moderator: Dr. Raquel del Carpio-O'Donovan

CONTINUING PROFESSIONAL DEVELOPMENT: WHERE ARE WE GOING, AND WHY SHOULD I CARE?

Dr. Sam Daniel 13:30 – 13:45

This presentation will be 12 minutes, followed by a 3-minute interactive question period.

PRESENTATION SUMMARY: This session will highlight the changes in the landscape of continuing professional development with a glimpse to the future. Participants will also get an opportunity to review the framework of the three learning sections of the Maintenance of Certification Program of The Royal College of Physicians and Surgeons of Canada (RCPSC).

LEARNING OBJECTIVES: At the end of this session, participants should be able to:

1. Identify the opportunities for continuing professional development relevant to their professional practice.
2. Define the three learning sections of the Maintenance of Certification Program of the RCPSC.
3. Document the process, outcomes and performance improvement goals in MAINPORT.

PREPARATION FOR ACADEMIC PROMOTION

Dr. Carlos Torres 13:45 – 14:00

This presentation will be 12 minutes, followed by a 3-minute interactive question period.

PRESENTATION SUMMARY: This lecture is a review of the definitions and associated domains of scholarship of the various career paths. These paths include: clinician-teacher, clinician-educator, clinician-investigator, clinician-scientist, scientist and clinician-administrator. The criteria for promotion predominantly based on education and clinical care will be presented. In particular, an outline will be offered on how to prepare the application package for promotion, while emphasizing tips for success. Some of the common reasons for a declined promotion will be listed.

LEARNING OBJECTIVES: At the end of this session, participants should be able to:

1. Determine the purpose of their faculty career paths and their relationship to academic promotion.
2. Identify the career path which best reflects an applicant's activities.
3. Recognize the importance of the promotion package in presenting the applicant's activities to the promotion committee.
4. Use the tips provided to prepare and submit an application package for promotion consideration.

LEADERSHIP ROLES

Dr. Benoît Gallix 14:00 – 14:30

PRESENTATION SUMMARY: In a radiology department, like in any other organization, leaders have to deal with the mechanisms involved in motivating those members' behaviours that are instrumental in helping the group achieve its goals. Adaptation to the environment is also very important. Leaders should also help the group define strategic and operational decision making. Communication, team building and conflict resolution are important processes within this function.

LEARNING OBJECTIVES: At the end of this session, participants should be able to:

1. Make the distinctions between leadership and management.
2. Describe the role and functions of leaders.
3. Identify the different manners in which leaders interact with the group.

WORK-LIFE BALANCE AND HAPPINESS AT WORK

Dr. Patrice Bret 14:30 – 15:00

PRESENTATION SUMMARY: The common belief of individuals and organizations is that if you work harder, you will be more successful, and if you are more successful, then you will be happy. In fact, recent research in positive psychology demonstrates that this belief is backwards: happiness fuels success; it is not the other way around.

Happier people live longer, they are healthier, they have better relationships, they command a higher income and they are more creative than their less happy counterparts.

There are simple strategies that can reliably raise the levels of happiness among individuals.

This presentation will review the status of the research in the field and some strategies that can help healthcare professionals balance and enjoy their work life better.

LEARNING OBJECTIVES: At the end of this session, participants should be able to:

1. Discuss the role of happiness as a critical element of success for individuals and organizations.
2. Identify the current status of positive psychology, management and neuroscience research on the topic of happiness at work.
3. Apply strategies to improve their work-life balance as a healthcare professional.

Afternoon Tracks – Saturday, April 26, 2014

CAR Radiologists-in-Training Awards

13:30 – 17:00: Salon 1
Moderator: Dr. Micheline Thibodeau
Judges: Dr. Pavel Crystal, Dr. Angus Hartery, Dr. Matthew McInnes

The following abstracts will be presented orally. Please refer to the Abstract Section starting on page 82 for the full abstract.

Les abrégés suivants seront présentés oralement. Veuillez consulter la section des résumés d'expositions, à la page 82, pour en faire la lecture complète.

13:30 – RT001
Congenital Bronchopulmonary Malformations (BPMs) – Prenatal Sonographic Features with Postnatal Correlations – *Juliette Garel*

13:40 – RT002
In Search of Criteria Supporting Chronic Cerebrospinal Venous Insufficiency (CCSVI) in Patients with Multiple Sclerosis – *Satya N. Patro*

13:50 – RT003
Disclosure of the Resident Role in the Interventional Radiology Suite: How Do Interventional Radiologists Balance Patient Care and Resident Education? – *Rebecca Zener*

14:00 – RT004
Are Chest CT Requisitions Dangerously Incomplete? – *Matthew Walker*

14:20 – RT006
The Exposure Deficit: a Qualitative Study of Medical Student Opinions and Perceptions of Radiology – *Kari L. Visscher*

14:30 – RT007
Are We Missing Traumatic Bowel and Mesenteric Injuries? – *Bret A. Landry*

14:40 – RT009
Magnetic Resonance Imaging for the Determination of Femoral Head Physis Closure Status – *Anthony Vo*

15:30 – RT010
Does Distance Matter? Presence of a CT Scanner Within the Emergency Department and Its Effect on Requisition, Diagnostic and Disposition Times for Emergency Patients – *Wilfred Dang*

15:40 – RT011
Comparison of the Diagnostic Accuracy of Clinical Examination and MRI for Detecting Traumatic Meniscal Lesions with Arthroscopy as the Reference Standard – *Mohammed Azfar Siddiqui*

15:50 – RT012
Liver MRI with Gadofosoveset trisodium (Ablavar™) – *Helen M. Cheung*

16:10 – RT014
Is Oral Contrast Necessary for MDCT of Emergency Room Patients with Acute Abdominal Pain? – *Abdullah Alabousi*

16:20 – RT015
MRI Evaluation of Becker Muscular Dystrophy – *Neda Faridian-Aragh*

16:30 – RT016
Rate of Duplicate Publication in Radiology Journals – *Chris J. Hong*

16:40 – RT017
Comparison of Dual Energy Subtraction Chest Radiography and Traditional Chest X-Rays in the Detection of Pulmonary Nodules – *Farheen Manji*

Afternoon Tracks – Saturday, April 26, 2014

Back to Basics – Pediatric

15:30 – 17:00: Salle de bal Ouest
Moderator: Dr. Benvon Cramer

Each of the following three presentations are 25 minutes, including an interactive audience response of 5 minutes. Each presentation will also be followed by a 5-minute interactive question period.

PEDIATRIC: NEURORADIOLOGY

Dr. Ravi Bhargava 15:30 – 16:00

PRESENTATION SUMMARY: Neuroimaging of children is becoming increasingly utilized as advances in imaging equipment and imaging techniques allow for evaluation of a variety of abnormalities. Community radiologists are increasingly being asked to image children for common neurologic disorders that have presented to family physicians and community pediatricians.

A number of common radiological diagnoses are seen on imaging that may present in a number of different ways in children. These will be illustrated using a case-based approach. Other cases will demonstrate imaging pearls that will allow for diagnoses of more atypical conditions, where the radiologist may be the first physician to suggest the proper diagnosis. Finally, cases will be shown where the radiologist's prompt diagnosis can allow for early intervention in urgent/emergent conditions.

LEARNING OBJECTIVES: At the end of this session, participants should be able to:

1. Diagnose common pediatric brain/spine abnormalities using a case-based approach.
2. Identify clues on imaging studies that would allow for identification of an atypical disorder masquerading as a common condition from a series of cases.
3. Recommend appropriate imaging investigations to allow diagnosis of a child with an urgent/emergent neurologic disorder illustrated by cases.

PEDIATRIC: BODY IMAGING

Dr. Kathy O'Brien 16:00 – 16:30

PRESENTATION SUMMARY: Both common presentations of less common pediatric body cases and uncommon presentations of common pediatric body cases will be presented. A spectrum of imaging modalities utilized in the work-up and diagnoses will be shown.

LEARNING OBJECTIVES: At the end of this session, participants should be able to:

1. Demonstrate improved proficiency in the diagnosis of common and atypical conditions in pediatric body imaging.
2. Recognize the myriad clinical and imaging presentations of various pediatric body conditions.
3. Integrate new learning into practice.
4. Maintain clinical knowledge, skills and attitudes appropriate to pediatric body imaging.

PEDIATRIC: MSK IMAGING

Dr. Benvon Cramer 16:30 – 17:00

PRESENTATION SUMMARY: This will be a case-based presentation on common pediatric musculoskeletal (MSK) cases with typical and atypical appearances. Pathology will include congenital, inflammatory, traumatic and neoplastic etiologies for bone and soft tissue lesions.

The differential diagnoses and findings will be discussed. Less common etiologies will be included to illustrate these differentials. Common pitfalls in diagnosis will also be presented.

LEARNING OBJECTIVES: At the end of this session, participants should be able to:

1. Identify and diagnose common pediatric MSK lesions.
2. Manage these lesions appropriately.
3. Recognize the pitfalls and differential diagnoses in common pediatric MSK lesions.

Afternoon Tracks – Saturday, April 26, 2014

The Thinking Radiologist

15:30 – 17:00: Salle de bal Est
Jeopardy Moderator: Dr. Christina Chingkoe
Debate Moderator: Dr. Michael Martin

JEOPARDY: RADIOLOGY STYLE

Game Hosts: Dr. Christina Chingkoe, Dr. Phyllis Glanc, Dr. Ali Jahed 15:30 – 16:00

PRESENTATION SUMMARY: The audience will be divided into teams, and cases will be presented in a jeopardy format, with teaching points and discussion.

Using a jeopardy-type quiz game format, two teams of participants will compete to see which team can get the most points by the end of the game. The audience will be split to support the two teams and will be called upon to participate. Cases will be "Aunt Minnie" types and, as always, it is important to correlate with the category name.

Test your skills as a team player during this fully interactive 30-minute encounter.

Enjoy the light-hearted format!

Disclaimer: The *Jeopardy!* game show and all elements thereof, including but not limited to copyright and trademark thereto, are the property of Jeopardy Productions, Inc. and are protected under law. This session is not affiliated with, sponsored by, or operated by Jeopardy Productions, Inc.

LEARNING OBJECTIVES: At the end of this session, participants should be able to:

1. Identify an array of imaging-related diagnoses based on "Aunt Minnie" style imaging presentations. (CanMEDS Role: Medical Expert)
2. Describe the major imaging features that distinguish certain "Aunt Minnie" type cases from other diagnoses.
3. Describe the session as FUN!

DEBATE – SHOULD STRUCTURED REPORTING BE MANDATORY?

Panelists: Dr. Gus Dotsikas, Dr. Jonathon Leipsic, Dr. Alec Megibow, Dr. Joseph O'Sullivan 16:00 – 17:00

Four panelists will present and defend their thoughts on this sensitive topic for 50 minutes, followed by 10 minutes of interaction and questions from the audience.

PRESENTATION SUMMARY: This friendly debate will feature four presenters, two arguing for the utilization of structured reporting for diagnostic imaging studies and two arguing against. This will provide a thorough exploration and assessment of the merits and disadvantages of structured reporting, and will allow the audience to determine if this method of reporting should be incorporated in their clinical practice.

LEARNING OBJECTIVES: At the end of this session, participants should be able to:

1. Describe common methods of utilizing structured reporting in diagnostic imaging.
2. Appraise the merits and disadvantages of structured reporting for diagnostic imaging studies.
3. Integrate structured reporting into their departments, should they wish to do so.

Morning Tracks – Sunday, April 27, 2014

Mistakes We All Make

08:00 – 10:00: Salle de bal Ouest
Moderator: Dr. Caitlin McGregor

NEURORADIOLOGY

Dr. Matthias Schmidt 08:00 – 08:30

PRESENTATION SUMMARY: This presentation will follow a case-based format to illustrate common pitfalls in neuroimaging.

Topics of discussion include misses, near-misses and interpretive errors related to tumors, trauma and other conditions that affect the head, neck and spine.

LEARNING OBJECTIVES: At the end of this session, participants should be able to:

1. Identify commonly missed abnormalities of the head and neck on plain radiographs, CT and MRI.
2. Identify commonly missed abnormalities of the spine on plain radiographs, CT and MRI.
3. Describe interpretive errors in imaging of the head, neck and spine.

ABDOMINAL IMAGING

Dr. Chirag Patel 08:30 – 09:00

PRESENTATION SUMMARY: This will be a case-based session highlighting common mistakes made by radiologists interpreting MRI, ultrasound and CT of the abdomen and pelvis. Visual errors and interpretive errors will be discussed.

LEARNING OBJECTIVES: At the end of this session, participants should be able to:

1. Identify common blind spots in abdomen pelvic ultrasound CT and MRI. (CanMEDS Role: Medical Expert)
2. Recognize and avoid common misinterpretations in abdominal imaging. (CanMEDS Role: Medical Expert)
3. Develop personal strategies for avoiding common mistakes. (CanMEDS Role: Medical Expert)

CHEST

Dr. Yannick Cartier 09:00 – 09:30

PRESENTATION SUMMARY: This presentation will highlight common mistakes and errors pertaining to chest imaging and provide some strategies to avoid them.

LEARNING OBJECTIVES: At the end of this session, participants should be able to:

1. Identify the most common pitfalls and/or blind spots pertaining to thoracic imaging.
2. Update their knowledge of thoracic imaging.

MUSCULOSKELETAL

Dr. Robert Bleakney 09:30 – 10:00

PRESENTATION SUMMARY: The presentation will cover the commonly missed MSK dislocations, including posterior shoulder, carpal and CMC Lisfranc.

Clinical features will be reviewed. Normal anatomy and the subtle radiographic signs of the various dislocations will be reviewed and illustrated.

LEARNING OBJECTIVES: At the end of this session, participants should be able to:

1. Apply their knowledge of the commonly missed MSK dislocations.
2. Identify the subtle radiographic signs of a posterior shoulder dislocation on AP radiograph.
3. Diagnose the commonly overlooked Carpal and CMC dislocations.
4. Identify the pattern of Lisfranc injury.

Slipping Through the Cracks and Into the Courtroom: A Mock Trial presented by the CMPA

10:30 – 12:00: Salle de bal Ouest
Moderator: Dr. Steven Bellemare

This presentation, created by the Canadian Medical Protective Association (CMPA), will be 80 minutes followed by a 10-minute interactive question period.

CMPA Mock Trial Participants:

CMPA Experts: Dr. Steven Bellemare and Ms. Anika Clark

Assisted by: Ms. Brieanne Brannagan and Mr. Mark Faassen Dr. Tim Zmijowskyj and Dr. Ross Berringer, Physician Risk Managers, CMPA

Radiologist Actors: Dr. Bruce Forster, Dr. Matthew McInnes, Dr. Jana Taylor

PRESENTATION SUMMARY: A mock trial is an experiential teaching modality drawn from law school pedagogy which permits learners to witness the application of medico-legal and risk management concepts in the safety of the classroom. Just as simulation brings an element of reality and situational awareness to simulated medical situations, mock trials provide medical and legal credibility to the process of acquiring medico-legal knowledge.

The activity presents a real (closed) yet disguised clinical case, from presentation to adverse event and eventual outcome. It outlines the allegations of medical negligence against the defendant healthcare providers. With the help of participants acting as witnesses and CMPA provincial counsel acting as defense and plaintiff's counsel, the mock trial presents short snippets of the actual trial including testimonies. At the end, the audience is asked for its "verdict" before being informed of the outcome of the actual case.

Teaching and advice are provided throughout by lawyers and physicians on a variety of topics including medical negligence, the anatomy of a lawsuit, the provision of safer patient care, documentation to improve defensibility, testifying in court and more. The format serves as an ideal method for effectively engaging audiences in learning about medico-legal issues in a pedagogically diverse and collegial fashion.

LEARNING OBJECTIVES: At the end of this session, participants should be able to:

1. Outline how system breakdowns negatively impact patient safety.
2. Describe how risk management strategies can help prevent adverse outcomes.
3. Explain how the courts view responsibility in the care continuum.

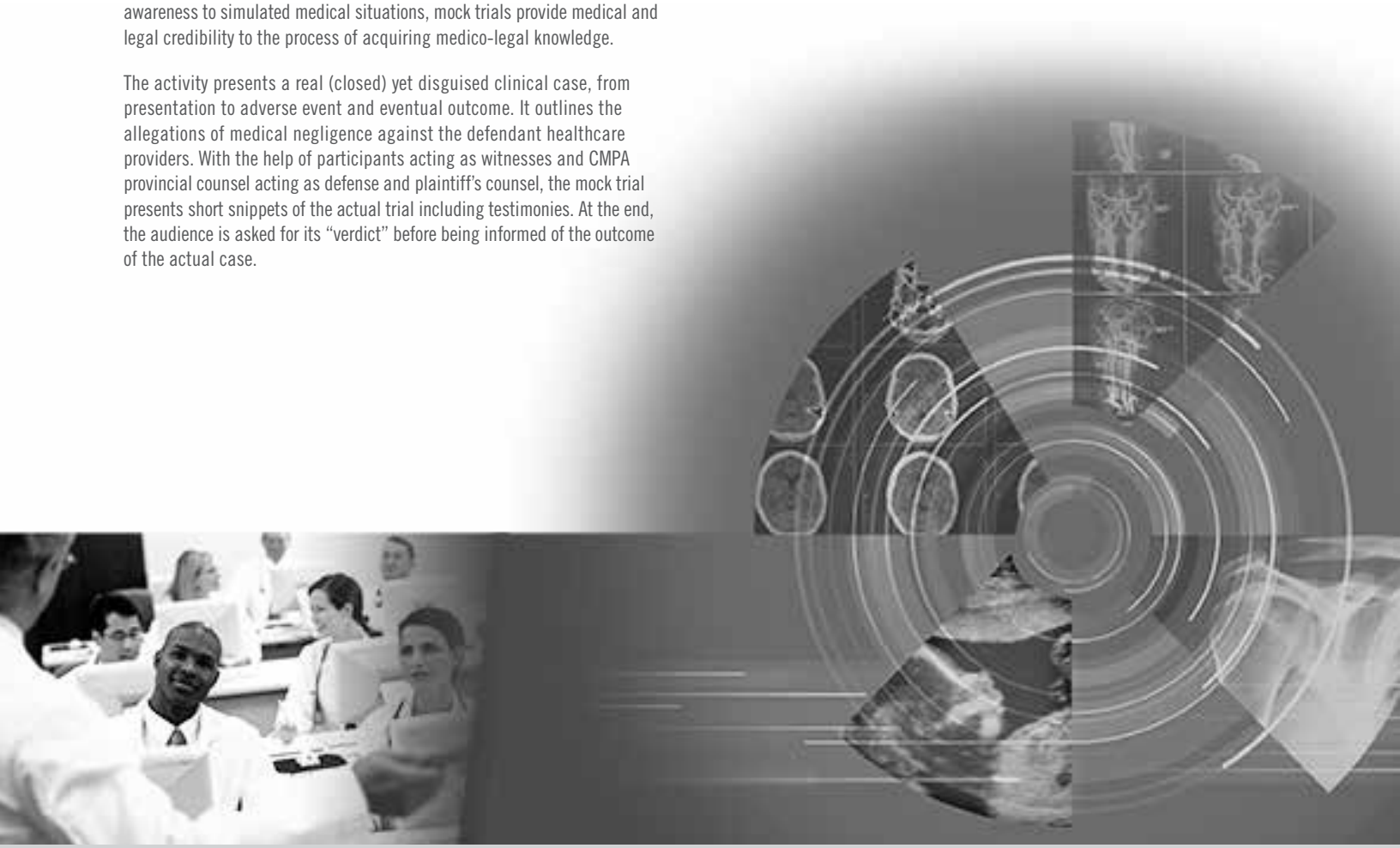

Abstracts

Résumés

Educational Exhibits | Expositions éducatives

All the Educational Exhibits are in digital format and are available for viewing in the foyer of the Salle de bal, 4th floor.
FRIDAY, APRIL 25, 2014 – SATURDAY, APRIL 26, 2014
Prizes for this contest are funded by the Canadian Radiological Foundation (CRF).

Toutes les expositions éducatives sont en format numérique et peuvent être visionnées dans le foyer de la Salle de bal au 4e étage.
VENDREDI LE 25 AVRIL 2014 – SAMEDI LE 26 AVRIL 2014
Les prix pour ce concours sont financés par la Fondation radiologique canadienne (FRC).

JUDGES / JUGES : Dr. Alison Harris, Dr. David Landry, Dr. Jessica Murphy-Lavallée

EE001

THE ANGRY SYNOVIUM – WHEN GOOD LINING MEMBRANE TURNS BAD!

Authors: Fergus Cafferty, Ingrid Heaslip, Bruce Forster, Gordon Andrews

LEARNING OBJECTIVES:

1. Display a range of synovial pathologies on various imaging modalities.
2. Discuss both the options and appropriateness of various imaging modalities for investigation of synovial pathology, and when to advise additional studies after initial identification of pathology.
3. Demonstrate what additional diagnostic information is gained by the use of MR or CT with intra-articular or intravenous contrast, over non contrast studies.
4. Highlight features typical of aggressive and malignant synovial lesions.

BACKGROUND: The synovium is typically only visualised when abnormal.

We display and discuss cases demonstrating the typical features of various synovial pathologies from our archive. These range from aggressive lesions such as synovial sarcoma, to benign lesions such as synovial plicae or cysts, with several in between, including pigmented villonodular synovitis, synovial chondromatosis and hemangiomatosis, lipoma arborescens, hemophilic arthropathy, and rice body effusions due to fungal and TB infection, and rheumatoid.

The differences between arthrographic versus standard imaging is also demonstrated.

CONCLUSION: Synovial lesions are commonly diagnosed radiologically without prior clinical suspicion, on studies performed for non-specific joint pain or swelling, or as incidental findings on studies performed following trauma.

MRI with intraarticular and/or intravenous gadolinium has greatly increased the confidence of evaluation of these pathologies.

It is important when reporting joint studies to recognize the presence of synovial pathology, give a reasonable differential, and in particular, recognize the aggressive, malignant lesions.

EE002

ACUTE ADULT ELBOW TRAUMA WITH REVIEW OF ANATOMY

Authors: Tyson Bolinske, Michael Simmons

LEARNING OBJECTIVES: The primary goals of the exhibit are to provide an image rich anatomic review of the ligamental and skeletal components of the elbow with multimodality examples of acute traumatic. An anatomical based radiographic search pattern will be discussed in an attempt to enhance the reader's efficiency and accuracy in the interpretation of the presenting radiographs. Lastly, given the high frequency of radial head and neck fractures, the commonly used Mason classification will be illustrated.

BACKGROUND: Detailed knowledge of the articulations, fossae, bony processes, ligaments, and additional soft tissues comprising the elbow is essential in the interpretation of radiographs, computed tomography (CT), and magnetic resonance imaging (MRI) alike. The most difficult diagnoses for the general radiologist and resident include subtle fractures such as coronoid process fractures. These fractures are significant in that they are often an early indication of underlying severe ligamental injury. Lack of precise anatomic knowledge and imaging appearances of acute trauma has the potential to lead to missed diagnoses, delayed diagnoses, patient morbidity, and degradation of clinician trust among many possible consequences.

CONCLUSION: Traumatic elbow injuries are encountered on a daily basis in the primary care and emergency room setting. A solid anatomical foundation combined with detailed knowledge of injury patterns will well equip the interpreting radiologist to quickly and accurately intervene in the patient's medical care.

EE003

RADIOLOGICAL DETECTION AND DIAGNOSIS OF POST ESOPHAGECTOMY COMPLICATIONS

Authors: Stacey L. Speer, Mark Landis

LEARNING OBJECTIVES:

1. Provide an epidemiologic overview of esophageal cancer.
2. Review the esophageal resection techniques employed for curative and palliative purposes for esophageal cancer.
3. Examine the postoperative complications following esophagectomy.
4. Examine the radiological techniques via fluoroscopy and computed tomography for detecting anastomotic complications.

BACKGROUND: The incidence of esophageal cancer is rapidly increasing. It is the third most common gastrointestinal malignancy and is now the sixth leading cause of cancer related deaths. The surgical management of esophageal cancer involves performing an esophageal resection, which is a very complex procedure with considerable patient morbidity and mortality. Postoperative complications can have disastrous consequences when they occur and therefore radiological imagining in combination with clinical assessment can facilitate the early identification of complications.

CONCLUSION: We aim to highlight the role of postoperative imaging following esophageal resection, the radiologic imaging techniques used and imaging features of potential complications in the context of esophageal cancer. We will provide an approach for the assessment and diagnosis of post esophagectomy complications and we will review the evidence on the use of fluoroscopic water soluble contrast swallow and computed tomography for detecting anastomotic complications in the early postoperative state.

EE004

HOT SCROTUM SIGN ON CROSS-SECTIONAL IMAGING: A THROCKMORTON SIGN FOR THE 21ST CENTURY: A CASE SERIES DEMONSTRATING A NOVEL IMAGING SIGN

Authors: David T. Nakamura, Michael Cody, Helen HR Kim, Jemmianne Bautista, Mohammad A. Helmy

LEARNING OBJECTIVES:

1. Review scrotal pathology with special attention to cross sectional imaging correlates.
2. Learn clues to detection of scrotal pathology on cross-sectional imaging and assess for extension of scrotal disease into the pelvic organs, even when the scrotum is incompletely imaged.
3. Make appropriate follow-up and further imaging suggestions.

BACKGROUND: Generally, the scrotum is not a region of particular focus in abdominal and pelvic cross sectional imaging. However, the spectrum of scrotal pathology is broad and encompasses a number of diseases, which may extend into the pelvis by way of the spermatic cords. We have recently discovered a heretofore undescribed cross-sectional imaging sign which appears highly sensitive for scrotal pathology, even when the scrotum is incompletely visualized. We will present cases of scrotal infection, neoplasm, inflammatory disease, vascular disease and trauma; detection of which is aided by our newly described sign.

While superficial structures such as the scrotum are often readily amenable to clinical assessment, a focused physical examination is often not performed in the setting of a busy emergency department or with vague patient complaints. As a result, readily available CT imaging is often utilized as a surrogate for clinical assessment. Knowledge of clues to detecting pathology within or originating from the scrotum will aid in early diagnosis of scrotal pathology and prevent delays in treatment.

CONCLUSION: Despite the often overlooked territory, scrotal disease can have profound implications for patient care. We believe that knowledge and application of our novel cross-sectional imaging sign will improve radiologic diagnosis of scrotal pathology as well as clinical outcomes.

EE005

CIRCUMNAVIGATING THE ANKLE: WHAT IS IMPINGING AND WHERE?

Authors: Ingrid Heaslip, Fergus Cafferty, Bruce Forster, Gordon Andrews

LEARNING OBJECTIVES:

1. Review the ligamentous anatomy of the ankle and patterns of injury.
2. Discuss, with imaging examples, the different ankle impingement syndromes and their imaging features.
3. Recognize the constellation of findings associated with each of the differing impingement regions.
4. Discuss which imaging modality is most appropriate to optimize diagnosis.

BACKGROUND: Ankle impingement is a mechanical restriction of range of movement, which is often painful and debilitating. It is typically the result of either soft tissue or osseous abnormalities. Impingement is usually secondary to repetitive, often sub-clinical, trauma, overuse and repeated sprains. It can be compartmentalized based on the clinical direction of impingement, including anterior, anterolateral, posterior, posteromedial and anteromedial. Each direction obviously has different regional anatomy, resulting in a somewhat unique list of impingement causes.

Conventional radiography is usually the first line test to out-rule bony injury, but cross-sectional imaging is usually required for further information. CT is excellent for assessing the osseous structures. Technetium bone scan can also be of benefit for localizing inflammation. MRI, including arthrography, however is the optimum test to evaluate the soft tissues and ligamentous structures.

CONCLUSION: Ankle impingement is an important cause of chronic pain and disability in both athletes and the general population. There is an opportunity to categorize this disability from an imaging standpoint, correlating the direction of restriction with the structures and pathology that are somewhat unique to that region. This regional approach will aid radiologists in what can be a difficult imaging diagnosis and help guide clinical management.

EE006

ENCOURAGING APPROPRIATE IMAGING UTILIZATION: ON-CALL COMMUNICATION TIPS TO AVOID POTENTIAL PITFALLS AND BUILD BETTER RELATIONSHIPS

Author: Stefanie Y. Lee

LEARNING OBJECTIVES: After viewing this exhibit, the reader will be able to:

1. Identify potentially challenging situations that may occur when discussing appropriate imaging utilization, particularly in the on-call setting.
2. Identify underlying factors which may lead to miscommunication or misunderstandings.
3. Describe and demonstrate various ways to avert or handle such situations in a constructive manner.

BACKGROUND: When doing after hours call, radiology residents are generally responsible for handling a large volume of requests from throughout the hospital. In addition to providing accurate and timely interpretations, residents are challenged to triage cases while avoiding miscommunication and misunderstandings in the setting of often rushed phone conversations and stressful patient care situations. The purpose of this exhibit is to discuss potential pitfalls in on-call interactions, as well as strategies to prevent or defuse them.

CONCLUSION: On-call phone interactions, particularly those involving triaging and study appropriateness, can be challenging due to external pressures and potential misunderstandings due to miscommunication. However, anticipating such situations and making an effort to understand the other party's viewpoint can allow residents to employ more effective communication strategies, leading to smoother workflow, less stress, and better quality of care.

A number of on-call scenarios will be provided, spanning initial protocolling of requests to communication of results, with take-home points and specific strategies and sample phrases for each situation. General principles of communication and strengthening working relationships will also be covered.

EE007

PEDIATRIC RENAL TUMOURS: A PICTORIAL REVIEW

Authors: Anish S. Mann, Grant W. Stoneham, Paul S. Babyn

LEARNING OBJECTIVES:

1. Realize pediatric renal tumours encompass a broad spectrum ranging from the benign to malignant to metastatic.
2. Know clinical features (age of presentation, symptoms, related disorders) associated with each neoplasm.
3. Recognize the ultrasound, CT, and MRI imaging findings for each tumour type.

BACKGROUND: The modern management of pediatric cancers has resulted in significantly improved survival rates compared to a few decades ago. Even so, cancer remains the leading cause of childhood deaths - renal tumours being amongst the most common culprits. Many pediatric renal mass lesions were previously categorized as Wilms tumour. Although Wilms tumours account for the vast majority of childhood kidney masses (~ 90%), renal tumours of childhood encompass a wider variety of distinct entities ranging from benign, to malignant, to metastatic origins. The radiologic identification of these tumours has significant contributions to treatment, metastatic potential, surgical approach, and prognosis. This educational exhibit reviews both uncommon and common renal tumours and highlights the unique clinical history, age of presentation, and characteristic imaging features for each tumour type – required for the knowledgeable radiologist to make an accurate diagnosis. Specific ultrasound, CT, and MRI findings will be discussed with examples. Examples included are: congential mesoblastic nephroma, angiomyolipoma, renal teratoma, Wilms tumour, clear cell sarcoma, renal cell carcinoma, rhabdoid tumour, lymphoma, and neuroblastoma. Potential pseudotumors will also be shown.

CONCLUSION: Imaging contributes significantly to the diagnosis of pediatric renal masses and tumours. The correct diagnosis of a potential pediatric tumour helps guide treatment and ultimately improves health outcomes in children affected with renal cancers.

EE008

IMAGING REVIEW OF FLEXOR ANNULAR PULLEY INJURIES IN THE FINGERS

Authors: David Russell, Gordon Andrews, Brendan Quiney, Mark Cresswell

LEARNING OBJECTIVES:

1. Review the anatomy of the flexor pulleys in the fingers, an uncommonly imaged region.
2. Become aware of the mechanism of injury in flexor annular pulley tears.
3. Review the imaging characteristics of these injuries on US, CT, and MRI, with case examples of each.
4. Provide an approach for the diagnosis of flexor pulley injuries.

BACKGROUND: Flexor annular pulley injuries of the finger are a relatively common injury seen in certain activities such as sport climbing. Imaging is helpful for both confirming the diagnosis as well as for surgical planning. The flexor pulleys hold the flexor tendons and sheaths along the bones of the finger. Under extreme forces, these pulleys can suffer partial or complete tears. Complete tears need far longer to heal completely and often require surgical repair.

CONCLUSION: Our aim here is to review the flexor pulley anatomy, describe the mechanism of injury, and identify the common sites where this typically occurs. Additionally, a review of the imaging characteristics of these injuries on US, CT and MRI allows for illustration of a diagnostic approach.

EE010

CALL PREPARATION CURRICULUM: MORE THAN JUST THE IMAGE. PROFESSIONALISM EDUCATION TEACHING RESIDENTS TO "DO THE RIGHT THING"

Authors: Danielle Walker, Karen Finlay

LEARNING OBJECTIVES:

1. Discuss the importance of professionalism as it applies to the radiology resident.
2. Explore barriers to professionalism by radiology residents specific to the "on-call" scenario.
3. Outline strategies to facilitate increased professionalism on-call, with a focus on communication and collaboration.

BACKGROUND: Professionalism has become a hot topic in the field of radiology. However, there is little written exploring professionalism by radiology resident's on-call. The high stress on-call situation is fraught with challenges to maintaining professional behaviour. Despite this, traditional curriculum for on-call preparation focuses almost exclusively on image interpretation. This presentation emphasizes the need to expand curriculum and offers a template for on-call preparation beyond the CanMEDS Medical Expert role, addressing the important roles of Professional, Communicator and Collaborator.

CONCLUSION: Professionalism in radiology is essential for the survival of our specialty. For the trainee, this topic is most relevant during the high-stress "on-call" scenario. There is an important need to develop call-preparation curriculum that comprehensively prepares residents for call and beyond.

EE011

TOP 14 MISSED DIAGNOSES IN THE HEAD AND NECK OF 2014

Authors: Stephanie Lam, Jaykumar Nair, Jeffrey Chankowsky, Carlos Torres, Huguette Remy, Raquel del Carpio-O'Donovan

LEARNING OBJECTIVES:

1. To discuss the imaging findings of the most commonly missed head and neck pathologies.
2. To review the main clinical features, epidemiology and differential diagnoses of these pathologies.
3. To identify the "blind spots" in imaging of the head and neck i.e. areas that should be systematically evaluated when interpreting a CT or MRI of the head and neck.

BACKGROUND: The head and neck has complex anatomy and can present a challenge for radiologists. Findings can be subtle and there are many blind spots, which can lead to a pathology being missed or misdiagnosed. It is therefore important to be systematic when interpreting a CT or MRI of the head and neck, and one needs to pay special attention to these blind spots while also taking into consideration the relevant clinical information.

This poster will discuss the most commonly missed head and neck pathologies, including their key imaging findings, clinical features, and differential diagnosis. The pathologies that will be discussed are : Otosclerosis, Odontogenic Sinusitis, Hemorrhagic labyrinthitis, Vestibular aqueduct syndrome, Calcific tendinitis of the longus colli, Retropharyngeal adenopathy, Sphenoid wing meningocele, Small nasopharyngeal carcinoma, Superior semi-circular canal dehiscence, Malignancies of the oral tongue, tongue base and floor of the mouth, Perineural tumor spread, Branchial cleft cyst versus HPV cystic metastasis, Lytic lesions of the clivus, and Submandibular sialolithiasis.

CONCLUSION: The numerous structures in the head and neck and its resulting complex anatomy can sometimes lead to difficulties in making a diagnosis. Discussing the most commonly missed diagnoses in the head and neck and identifying blind spots to be included in radiologists' systematic evaluation of a CT or MRI of the head and neck will hopefully improve detection of these pathologies.

EE012

CT OF THE SACROILIAC JOINTS: A REVIEW OF PATHOLOGIC FEATURES

Authors: Zaid Jibri, Robert G. Lambert

LEARNING OBJECTIVES: While CT is used less for the assessment of the sacroiliac joint than MRI, it still has an important role in the evaluation of complex and subtle cases. After reading this exhibit, the learner will:

1. Understand the principles of systematic evaluation of CT of the sacroiliac joint.
2. Have a check-list for interpretation of common pathology of the sacroiliac joint.
3. Know the full range of pathological findings that occur in the sacroiliac joint.
4. Better understand the challenges in interpretation of complex and subtle cases through review of proven clinical cases.

BACKGROUND: Interpretation of any modality can be challenging in very early and very late disease when typical manifestations may be absent or obscured. This may be especially important in early inflammatory arthritis when confirmation of the diagnosis may alter therapeutic decisions regarding expensive biologic therapy. Imaging of the sacroiliac joint has traditionally been difficult but CT images are relatively easy to acquire. However, significant sacroiliac joint abnormalities are often overlooked on routine CT studies of the abdomen and pelvis.

CONCLUSION: It is important for radiologists to be familiar with the range of abnormal CT findings of the sacroiliac joints. Many routine CT studies provide detailed imaging of this joint and detection of the features of inflammatory spondyloarthropathy in early disease is important but should be distinguished from other disease entities. Good knowledge and experience of CT of the sacroiliac joint may also assist with interpretation of MRI of this complex structure.

EE013

CURRENT ONCOLOGIC APPLICATIONS FOR WHOLE BODY IMAGING (WBMRI)

Authors: Wendy Tu, Paul Babyn

LEARNING OBJECTIVES:

1. Review the variety of oncologic WBMRI techniques.
2. Review the current role of WBMRI in diagnosis, (re-)staging and therapy response in the most common adult tumors: lung, breast, and prostate cancer.
3. Illustrate upcoming directions for WBMRI including diffusion-weighted imaging, and image fusion for PET/MRI.

BACKGROUND: Imaging plays a key role in tumor assessment with often a multiplicity of imaging modalities needed to obtain accurate and complete information. Whole body MRI (WBMRI) is increasingly used for diagnosis, staging, and follow up with high specificity and sensitivity. We reviewed the literature and illustrate the current techniques, capability and impact of WBMRI for the three most common cancers in Canada (Prostate, Lung and Breast).

CONCLUSION: Benefits of WBMRI include its excellent tissue contrast, high spatial resolution, and detailed morphologic and pathologic information with a whole body screening modality allowing coverage of all possible sites of metastastic disease. WBMRI can assess different organ systems for metastases, and can compete with other whole body techniques, such as FDG-PET-CT, without exposure to ionizing radiation. In addition, WB MRI can be combined with PET as PET/MRI or with diffusion-weighted MRI (DWI-MRI) to provide a functional assessment. Specific values of WBMRI have been demonstrated for TNM staging in NSCLC, and bone metastases detection in prostate cancer and breast cancer.

WBMRI is an evolving imaging modality with many expanding applications for the common adult tumors including diffusion weighted imaging and PET/MRI. It is to be expected in the coming years greater capability will be demonstrated as the modality develops and current limitations are overcome.

EE014

CT IMAGING OF COMPLICATIONS ASSOCIATED WITH PERCUTANEOUS NON-VASCULAR RENAL INTERVENTION: A PICTORIAL ESSAY

Authors: Sandeep Halagatti Venkatesh, N. K. Venkatanarasimha Karaddi

LEARNING OBJECTIVES:

1. To identify various complications associated with percutaneous non-vascular renal intervention and differentiate them.
2. To provide information which helps in deciding either conservative management or active intervention.
3. To provide accurate roadmap if active intervention needed.

BACKGROUND: Various nonvascular percutaneous renal intervention include non-focal renal biopsy for nephropathies or transplant rejection, focal renal biopsies for tumors, cyst aspiration, tumor ablation and percutaneous nephrostomy for obstructed uropathy.

Although relatively safe, complications are known to be associated with percutaneous intervention. Complications include bleeding, infection, and injuries to adjacent organ , pelvicalcyceal system or ureter. Bleeding may be due to injury to renal vessels, bleeding from vascular mass, arteriovenous malformation (AVM) or arteriovenous fistula (AVF). Massive hematuria is usually as a result of renal AVF or AVM. In less severe cases it may be from venous source or necrotic kidney tissue. Mild perinephric hematoma is very common and self-limiting. Massive perinephric hematomas can also occur compressing renal parenchyma. The peripheral lumbar or intramuscular arteries may also be injured leading to bleeding. Injury to pelvicalcyceal system may lead to urinoma formation.

CT being non-invasive and faster with MPR in various vascular phases can easily identify above complications. Associated adjacent visceral injury can also be assessed. It helps in accurate interventional planning and further treatment. By providing quick diagnosis patient morbidity and mortality can be reduced.

We will attempt to provide pictorial essay of various complications and help to differentiate various lesions on CT including perinephric hematoma, AVF, AVM, bleeding from peripheral lumbar or intramuscular arteries, urinoma, bleeding into pelvicalcyceal system, infections such as pyelonephritis and renal abscess.

CONCLUSION: Various life threating complications may occur with percutaneous nonvascular renal intervention and CT plays a vital role in identifying and helping in further management.

EE015

THE IMPORTANT ROLE OF BARIUM ESOPHAGOGRAPHY IN THE EVALUATION OF ESOPHAGEAL PATHOLOGIES

Authors: Babak Maghdoori, Nasir M. Jaffer, Seng Thipphavong

LEARNING OBJECTIVES:

1. Review of esophageal anatomy.
2. Describe imaging techniques used in the evaluation of esophageal pathologies.
3. Illustrate the role of Barium Esophagography in the assessment of esophageal pathologies.

BACKGROUND: Esophagus is a hollow muscular tube that pathophysiogically may be studied in three sub-segments: cervical, thoracic, and the gastric-esophageal junction (GEJ). The esophageal pathologies are diverse, ranging from benign entities (reflux diseases) to life-threatening conditions (adenocarcinomas).

Different imaging modalities are used to diagnose and stage various esophageal pathologies, including: barium esophagography (BaEs), computed tomography (CT), magnetic resonance imaging (MRI), and endoscopic ultrasonography (EUS). Although certain modalities, such as CT, allow the staging of esophageal malignancies, BaEs remains the preferred modality for certain structural abnormalities (cricopharyngeal bar), mucosal diseases (esoinophilic esophagitis), and motility disorders (early achalasia), which are currently not detectable by other imaging modalities.

BaEs is an important screening technique for many esophageal disorders. Thus, it is prudent for radiologists to perform these studies correctly, to have a thorough knowledge of all diseases, and to provide clinicians the anatomical/pathophysiological information for appropriate management. The BaEs technique should routinely include cine, double-contrast, and solid-bolus techniques for optimal detection of various esophageal pathologies.

We will illustrate the appropriate BaEs imaging techniques and showcase a wide spectrum of esophageal pathologies in this educational exhibit.

CONCLUSION: BaEs remains the preferred imaging study for certain esophageal disorders which may not be detectable by other imaging modalities.

EE017

IMAGING HEPATOCELLULAR CARCINOMA: DIAGNOSIS AND TREATMENT CONSIDERATIONS

Authors: Amirkasra Mojtahed, Peter E. Humprey, Steven C. Eberhardt

LEARNING OBJECTIVES:

1. Review the imaging appearance of typical, infiltrating, and multifocal hepatocellular carcinoma (HCC).
2. Discuss the criteria for the imaging diagnosis of HCC.
3. Present imaging features that preclude liver transplantation as a treatment.

BACKGROUND: Hepatocellular carcinoma accounts for up to 90% of all primary liver malignancies and the majority of cases occur in the setting of cirrhosis. Because HCC may be diagnosed by imaging, it is an important entity for radiologists to recognize and be familiar with its typical and atypical imaging appearance. Liver transplantation may be a treatment option for HCC provided certain criteria are met.

CONCLUSION: Diagnosis of most HCC can be made by finding a mass of at least 2 cm in diameter with arterial hyperenhancement followed by subsequent hypoenhancement relative to surrounding liver (washout) on delayed phase imaging, frequently with an encapsulated appearance. HCC is best characterized with CT or MRI, as these modalities allow multiphasic post-contrast imaging to detect early and late phase contrast character. Occasionally, HCC may appear as an infiltrative mass or multifocal masses. The infiltrative subtype can be particularly difficult to diagnose given its permeative appearance and lack of a well-defined mass. Multifocality may preclude liver transplantation if there are three lesions which are 3 cm or larger in diameter. The infiltrative and other subtypes may show venous invasion or extrahepatic involvement: findings that also preclude potentially curative transplantation.

EE018

SPINAL HARDWARE COMPLICATIONS

Authors: Olivia McDonnell, Jason Chew

LEARNING OBJECTIVES: To illustrate the imaging appearances of common and uncommon, early and late complications of spinal instrumentation.

BACKGROUND: Radiography is the mainstay for imaging post operative patients and has the advantage of being quick and inexpensive. MDCT may also be used, but is associated with an increased radiation dose. MRI is most useful at assessing for post operative infection.

Imaging of patients with post operative spinal instrumentation complications was reviewed. The imaging modalities used included plain radiographs, CT and MRI.

We illustrate complications such as instrument malpositioning of pedicle screws, cages, bone grafts and plates. Late complications such as adjacent segment degenerative disease, failure of fusion, hardware fracture, loosening or displacement were also demonstrated, as well as post operative infection.

CONCLUSION: It is important that the radiologist is aware of the possible complications associated with spinal instrumentation and their imaging appearances in order to allow early detection and treatment. Systematic evaluation is required. Although radiography remains the primary modality, MDCT and MRI also have a role in further evaluation.

EE019

DIAGNOSTIC IMAGING APPROPRIATENESS ALGORITHMS FOR PREGNANT WOMEN IN THE EMERGENCY ROOM

Authors: David T. Nakamura, Michael Cody, Marwah Helmy

LEARNING OBJECTIVES:

1. Review potential life threatening pathology of gravid women that requires imaging for diagnosis.
2. Evaluate potential imaging algorithms for the appropriate work up of pregnant women in the emergency room.
3. Make recommendations with fetal safety and radiation biology risks in mind.

BACKGROUND: Over the past decade, imaging utilization in the United States (US) has increased rapidly, especially the use of CT. In the ER, CT is the mainstay for rapid and accurate diagnosis of life-threatening pathology. However, recent events in the US have demonstrated potential safety pitfalls specifically with regards to ionizing radiation. Often, these safety events unrelated to over-utilization. Nonetheless, they have brought imaging safety and appropriateness to the forefront of clinicians, radiologists and the public at large.

One area of emergency radiology that requires special attention is imaging the pregnant patient. Some ailments that present in pregnancy occur because of pregnancy itself, however other urgent illnesses may simply coincide with the pregnancy. We will review common pathologies including acute appendicitis, pulmonary embolism, DVT, cholecystitis, trauma and urolithiasis. At our busy Level I trauma center we use standardized imaging algorithms developed by the radiology department. We will present these as examples for acceptable imaging standards, which are especially useful for the ER radiology staff on call. Modalities that will be covered include nuclear imaging, MRI, CT, ultrasound and radiographs with specific attention on potential safety issues including ionizing radiation to the fetus and breasts as well as contrast reactions.

CONCLUSION: With regards to imaging the pregnant patient it is important to accurately and rapidly diagnose pathology. However requisite imaging should be performed with utmost attention to appropriateness and potential risk to both the mother and fetus. Our presentation will demonstrate potential imaging algorithms for a pregnant patient who presents to the ER.

EE020

UNDERSTANDING MAGNETIC RESONANCE IMAGING APPROPRIATENESS IN CANADA: A LITERATURE REVIEW ON CURRENT PRACTICES, UTILIZATION AND APPROPRIATENESS

Authors: Neil Kalra, Paul Babyn, Sonia Vanderby, Juan-Nicolás Peña-Sanchez

LEARNING OBJECTIVES:

1. To raise awareness on the issues surrounding inappropriate medical imaging exams and their implications for patients, physicians and the health care system.
2. To understand the causes of inappropriate medical imaging exams and the means by which they can be mitigated.
3. To illustrate the areas in which appropriateness studies have been completed in Canada thus far and outline their results.
4. To appreciate the causes of variations in previous study results, specifically regarding the proportion of inappropriate magnetic resonance imaging exams being conducted in Canada.

BACKGROUND: The appropriateness and quality of medical imaging exams, particularly magnetic resonance (MR) imaging, has become a front line discussion topic and mounting concern in Canada. The number of inappropriate imaging exams in Canada has commonly been quoted at approximately 30%, although the validity of this statistic has been questioned. We completed a systematic peer-reviewed literature search on MR appropriateness in Canada using several databases, including EMBASE, PubMed, Medline, and Google Scholar.

CONCLUSION: Very little has been published to date regarding current MR exam evaluation practices, appropriateness or utilization nationally. Our search yielded a total of 16 relevant articles (commentaries and quantitative studies). The majority of the quantitative studies were conducted on a small scale/local academic center level as opposed to population based. Furthermore, the percentage of inappropriate imaging exams found in these studies ranged from 2% to 11% due in part to variations in study design. The commentaries and discussion articles revealed several common themes: 1) inappropriate imaging exams lead to several undesirable consequences; 2) the need to understand the causes of inappropriate imaging and determine how to address them effectively; 3) appropriateness guidelines have been developed in various countries including Canada but are not commonly used in practice.

EE021

PEARLS FOR INTERPRETING CERVICAL SPINE IMAGES IN TRAUMA

Authors: Kathryn Darras, Nivmand Khorrami-Arani, Gordon Andrews, Bruce Forster

LEARNING OBJECTIVES:

1. To illustrate the anatomic relationships of the cervical spine.
2. To review the latest guidelines for imaging patients with suspected cervical spine injuries.
3. To provide a systematic approach for interpretation of both radiographs and CT images, including attention to “blind spots”.
4. To review the imaging findings of stable and unstable cervical spine injuries.

BACKGROUND: All patients presenting to the emergency department with high-impact trauma receive cervical spine imaging, usually in the form of a CT scan, and clinicians rely on timely and accurate interpretation of these studies to guide management. A systematic approach to interpretation of trauma cervical spine imaging will be presented including how best to incorporate reconstructions into the search pattern, highlighting potential pitfalls and blind spots.

CONCLUSION: A practical, stepwise approach to interpreting cervical spine trauma is essential to limiting misdiagnoses and reducing patient mortality and morbidity. This is especially true in the emergency setting due to the complex, multi-system injuries and the increased pressure to interpret images quickly. Illustrative examples will be provided from our experience at Vancouver General Hospital, a quaternary care trauma centre.

EE023

PERCUTANEOUS SPHINCTEROTOMY WITH CUTTING BALLOON ANGIOPLASTY FOR THE REMOVAL OF COMMONAL BILE DUCT STONES

Authors: Stacey L. Speer, Amol Mujoomdar

LEARNING OBJECTIVES:

1. Review the standard therapeutic modality for the removal of common bile duct stones.
2. Highlight a novel Interventional Radiology technique for the removal of common bile duct stones in the context of a failed endoscopic retrograde cholangiopancreatography (ERCP).
3. Describe the clinical context that would clearly illustrate the benefits of this innovative approach.

BACKGROUND: Endoscopic sphincterotomy has been established as the standard therapeutic modality for the removal of common bile duct stones with a successful stone removal rate of more than 92%, morbidity ranging from 2 to 10% and mortality estimated at less than 2%. Unfortunately, there remains certain clinical situations whereby an endoscopic approach is unsuccessful. The use of percutaneous sphincterotomy, through an existing transhepatic biliary access, with cutting balloon angioplasty is an alternate modality to consider.

CONCLUSION: We aim to highlight a novel Interventional Radiology approach to access common bile duct stones via percutaneous sphincterotomy with cutting balloon angioplasty in patients where ERCP is technically unsuccessful and we will provide a review of the clinical context in which this technique might be more appropriate as a means to demonstrate the benefits of this approach.

EE024

ESSENTIAL INTERVENTIONAL PROCEDURES FOR THE GENERAL RADIOLOGIST

Author: Ruairi P. Meagher

LEARNING OBJECTIVES: To review five essential interventional procedures (abscess drainage, PICC line insertion, general biopsy, nephrostomy, and thoracentesis) with special emphasis on indications, contraindications, and complications.

BACKGROUND: Procedures can make up a substantial portion of a community radiology practice. We review five essential interventional radiology procedures for the community radiologist and resident with emphasis on indications, contraindication, anatomy, technique, and possible complications.

CONCLUSION: Participants will be familiar with the indications, contraindications, relevant anatomy, technique, equipment, and possible complications of five essential interventional procedures.

EE025

CLASSICAL SIGNS ON THE ABDOMINAL RADIOGRAPH WITH CROSS-SECTIONAL CT CORRELATION: IMPROVING DETECTION OF IMPORTANT SIGNS USING A PATTERN BASED APPROACH

Authors: Bhim J. Odedra, Ciaran Healy, Sunil Dajee, Adam Barnes, Pari Tiwari, Jacqueline Brown, Patrick Vos

LEARNING OBJECTIVES:

1. Review key abdominal radiographic anatomy.
2. Provide pearls in searching for important pathology on plain radiographs.
3. Demonstrate several well known radiographic signs and show their CT correlates to consolidate your understanding.
4. Test your plain film skills in a quiz, with CT correlates in the answers.

BACKGROUND: With the increasing usage of CT-imaging, there is a risk of neglecting the value of plain film radiography, particularly among trainees and newly qualified radiologists. Understanding key anatomical concepts and radiographic signs combined with practice and experience will enable you to become more efficient at interpreting 2D representations of anatomical structures and pathology superimposed on each other.

It is important to appreciate that there are classical features on radiographs that aid diagnosis without resorting to the cross-sectional imaging.

CONCLUSION: There are many classical abdominal radiographic signs that can be useful in making a diagnosis without initially resorting to the growing use of higher radiation dose cross-sectional imaging. We will provide an approach to detection and characterization of these signs illustrated with examples and demonstrate their CT correlates.

EE026

IMAGING OF THE SACROILIAC JOINTS: A REVIEW OF ANATOMICAL VARIATION

Authors: Zaid Jibri, Robert G. Lambert

LEARNING OBJECTIVES: After reading this exhibit, the learner will:

1. Have a general understanding of the imaging anatomy of the sacroiliac (SI) joint.
2. Be familiar with the range of normal anatomical variants at the SI joint, including those demonstrated on the plain radiograph, CT, MRI and bone scintigraphy.
3. Be able to differentiate these anatomic variants from certain pathologic features.

BACKGROUND: One of the challenges in the imaging evaluation of the SI joint is the presence of a spectrum of recognized anatomic variants. These can result in a few unusual appearances that could confuse image interpretation to the inexperienced observer or indeed mimic disease entities. These variations could result in appearance that may simulate erosions or new bone formation at the SI joint, which could lead to a misdiagnosis of inflammatory sacroiliitis.

CONCLUSION: It is important for radiologists to be familiar with the range of anatomic variation at the SI joints. Recognition of the normal variation in this complex structure is important and needs to be distinguished from the disease entities on the various imaging modalities.

EE027

POINT-OF-CARE TRANSTHORACIC ULTRASOUND: COMMON CLINICAL DIAGNOSES

Authors: Samer Dabbo, Phyllis Glanc

LEARNING OBJECTIVES:

1. Discuss technical factors, probe selection and patient positioning to optimize assessment of the lung on transthoracic ultrasound.
2. Review normal lung ultrasound and associated artifacts.
3. Demonstrate typical ultrasound findings in acute lung pathology such as pneumothorax, pleural effusions, alveolar consolidation, pulmonary edema and rib fractures.
4. Correlate transthoracic ultrasound pathology with chest X-ray and CT findings.

BACKGROUND: Transthoracic ultrasound is emerging as a useful clinical tool for point-of-care assessment of patients. Advantages of this modality over traditional chest x-rays and computed tomography include a rapid portable assessment without ionizing radiation exposure.

For each diagnosis, the ultrasound findings will be correlated to chest X-ray and CT. Normal lung findings will be reviewed via static images and dynamic clips of A-lines, B-lines, lung sliding, and the "sea-shore sign". Abnormal ultrasound findings will include absence of lung sliding and "bar-code sign" in pneumothorax, increased B-lines in pulmonary edema, and "hepatization" of lungs in consolidation.

Finally, limitations of transthoracic ultrasound in detection of pathologies will be highlighted.

CONCLUSION: Point-of-care transthoracic ultrasound can be used in the assessment of patients to diagnose common acute pathologies.

EE028

AS HARD AS THE ROCK: IMAGING OF THE PETROUS APEX

Authors: Rashid Al Sharhan, Jaykumar Nair, Jeffery Chankowsky, Carlos Torres, Raquel del Carpio-O'Donovan

LEARNING OBJECTIVES:

1. To revisit the complex structural anatomy of the petrous apex, the adjoining cranial nerves and neurovascular bundles.
2. To highlight the imaging features and salient differentiating characteristics of various petrous apex pathologies.

BACKGROUND: Based on the underlying cause, petrous apex lesions are classified into developmental, inflammatory, infectious, neoplastic, vascular and osseous. We shall discuss some classical cases under each category having distinctive imaging features.

The exhibit will include but is not limited to characteristic imaging features of the following petrous apex lesions on cross-sectional imaging: Petrous effusion, Pneumatization, Pseudo fractures, Mucocele, Cephalocele. Petrous Apicitis, Osteomyelitis, Cholesterol granuloma, Cholesteatoma, Meningioma, Schwannoma, Paraganglioma, Petrous Carotid Aneurysm, Endolymphatic sac tumor, Osteoblastoma, Giant cell tumors; Fibrous Dysplasia, Paget disease, Plasmacytoma, Chondroma, Chondroblastoma and Metastasis.

CONCLUSION: Lesions related to petrous apex cause diverse clinical sequelae ranging from mass effect to direct invasion of the neurovascular bundles. Due to its inert location, cross-sectional imaging plays an important role in recognizing, characterising and also aids in treatment planning of the lesions. Understanding the anatomical units and their relations can lead to accurate and early diagnosis of petrous apex lesions.

EE029

DUPLEX ULTRASOUND IMAGING OF DIALYSIS FISTULAE AND GRAFTS: EVERYTHING A RADIOLOGIST NEEDS TO KNOW

Authors: Michael E. Cody, David T. Nakamura, Armando S. Garza, Mohammad A. Helmy, Chandana G. Lall

LEARNING OBJECTIVES:

1. Enhance skills in interpreting duplex ultrasound for hemodialysis access (HDA) fistulas and grafts.
2. Learn common locations, surgical techniques, and expected hemodynamic changes and Doppler findings after HDA placement.
3. Recognize findings of and clues to pathologic states and complications related to HDA.

BACKGROUND: Duplex ultrasound has emerged as a useful adjunct for surveillance of hemodialysis access, although we have found many radiologists lack confidence in reading these examinations. Proper interpretation requires understanding of the expected anatomic and hemodynamic changes following fistula or graft placement. In addition, one must be familiar with gray-scale and waveform changes that suggest access site stenosis or occlusion as well as complications such as vascular steal, pseudoaneurysm and central venous stenosis.

CONCLUSION: HDA is readily amenable to ultrasound interrogation. With knowledge of relevant surgical anatomy and common HDA abnormalities and complications, radiologists will be well-equipped in interpreting these seemingly complex cases.

EE030

PANCREATITIS: REVISED ATLANTA CLASSIFICATION AND NEW EVIDENCE BASED MANAGEMENT GUIDELINES – WHAT THE RADIOLOGIST NEEDS TO KNOW

Authors: Triona Walshe, Steven Jepson, Graeme McNeill, Alison Harris, Silvia Chang

LEARNING OBJECTIVES:

1. To discuss the changes of the revised Atlanta classification 2012 and the IAP/APA evidence-based guidelines for the management of acute pancreatitis and highlight the changes that are most important for the radiologist.
2. To discuss how the guidelines for management will affect the imaging of acute pancreatitis and its complications.
3. To illustrate new definitions described in the revised classification using CT images to show types and stages of acute pancreatitis as well as the complications.

BACKGROUND: The revised Atlanta classification of acute pancreatitis and the revised evidence-based guidelines for the management of acute pancreatitis from the IAP/APA were both published in 2012. Both are important international consensus papers which update the previous working classification systems and best practice guidelines to more clearly define the diagnosis, imaging and treatment of acute pancreatitis. In the interim since the publication of the original Atlanta classification in 1992 and the publication of the original International Association of Pancreatology (IAP) treatment guidelines in 2002, there have been substantial advances in knowledge about, the imaging of and the treatment of pancreatitis. The revised system of classification and guidelines will hopefully lead to a standardized approach to imaging and management of acute pancreatitis.

CONCLUSION: Both the revised Atlanta classification and the IAP/APA evidence-based guidelines for the management of acute pancreatitis have refined the definition of acute pancreatitis and its complications in a continued attempt to improve treatment and communication amongst physicians. As the radiologists, it is important to understand these new revisions, classifications and terminology in order to help standardize the diagnosis and management of acute pancreatitis.

EE031

IMAGING IN MENOPAUSE: NEW NORMS AND OLD PATHOLOGIES

Authors: Adam A. Dmytriw, Kathy O'Brien

LEARNING OBJECTIVES:

1. To review the different standards for normal measurements of the menopausal endometrium and unique considerations surrounding HRT, Tamoxifen and others.
2. To detail the common and distinctive pathologies involving the uterus and adnexa during menopause.
3. To illustrate essential findings on spanning common modalities in gynecological imaging.

BACKGROUND: A review of the pre-menopausal endometrium on ultrasound and magnetic resonance imaging (MRI) is presented and contrasted with the menopausal endometrium, with or without history of bleeding, hormone replacement therapy and Tamoxifen use. Common and distinctive presentations spanning, endometrial polyp, adenomyosis and malignancy are presented, with their common ultrasound, MRI and sonohysterographic appearances as applicable.

CONCLUSION: Menopause is defined as the permanent cessation of menstrual periods, and is determined retrospectively after a woman has experienced 12 months of amenorrhea in the absence of other obvious pathological or physiological causes. This normally occurs in women aged 45 – 55 (mean 51.4) years. This stage of a woman's life is unique with the regards to disease presentation and the radiologist must be aware of the changing nature of normal anatomy and imaging presentation of common endometrial pathology.

EE032

MEDICAL EMERGENCIES IN THE RADIOLOGY DEPARTMENT

Authors: Adam A. Dmytriw, Christopher B. Lightfoot, Andrew H. Travers

LEARNING OBJECTIVES:

1. To stress that life-threatening emergencies do arise in radiology departments.
2. To illustrate emergency scenarios in case-based format.
3. To present a standardized initial approach to treatment of commonly encountered radiology emergencies.

BACKGROUND: Although infrequent, life-threatening emergencies do arise in radiology departments. Many radiologists have been removed from front-line clinical care of critical illness. Case-based learning comprising severe allergic reaction, respiratory decompensation, vasovagal response, contrast extravasation, seizure, air embolus, and cardiac arrest is presented.

Management guidelines are provided with proposed standardized flowcharts, as well as a suggested emergency drug kit.

CONCLUSION:

- As reliance on diagnostic imaging increases, radiologists should have a comprehensive understanding of adverse reactions and medical emergencies that may occur in their departments.
- As in all critical medical emergencies, a standardized approach to assessment and management of airway, breathing and circulation is required. Ready access to several key medications and equipment can be life-saving for our patients.
- Often an emergency medical response team can and should be activated but important medical therapies are frequently required before they arrive.

EE033

UNDERSTANDING THE EXTREMES OF HEADACHE: INTRACRANIAL HYPOTENSION OR HYPERTENSION?

Authors: Kathryn Darras, Nivmand Khorrami-Arani, Gordon Andrews, Bruce Forster

LEARNING OBJECTIVES:

1. To review the pathophysiology and clinical presentation of Spontaneous Intracranial Hypotension and Idiopathic Intracranial Hypertension.
2. To define characteristic CT and MR imaging features seen in these conditions and to emphasize the differences in these two syndromes.
3. To review the indications for MR imaging of the head in the context of headache.
4. To provide a checklist of "hot spots" for radiologists when interpreting scans for headache, in order to reduce the incidence of error.
5. To familiarize radiologists with the treatment options available to patients, including the role of interventional radiology.

BACKGROUND: Spontaneous Intracranial Hypotension and Idiopathic Intracranial Hypertension are both headache syndromes with separate and distinct imaging features. The two conditions are often confused due to their similar clinical presentation and nomenclature. Having a high suspicion for these entities when interpreting head imaging and reviewing key "hot spots" will enable the radiologist to make a more timely and accurate diagnosis. A review of the management options, including the role of interventional radiology, will also be discussed.

CONCLUSION: The purpose of this exhibit is to compare and contrast the pathophysiology and imaging features of Spontaneous Intracranial Hypotension and Idiopathic Intracranial Hypertension and to familiarize radiologists with the treatment options available to patients.

EE034

FAT-CONTAINING LESIONS IN ADVANCED CARDIAC IMAGING: A CASE BASED COMPENDIUM

Authors: Binita R. Chacko, Andrew T. Yan, Anish Kirpalani, Andrew M. Crean, Kim Connelly, Djeven Deva

LEARNING OBJECTIVES:

1. To review optimal imaging techniques for identifying and characterizing fat-containing lesions on cardiac magnetic resonance imaging (MRI) and computed tomography (CT).
2. To illustrate the spectrum of fat-containing lesions seen on cardiac MRI and CT.
3. To discuss briefly the clinical relevance of different disease entities.

BACKGROUND: Intramyocardial fat is incompletely understood, but can be incidental (eg. senescent intramyocardial fat infiltration) or clinically significant (eg. arrhythmogenic right ventricular cardiomyopathy/dysplasia - ARVC/D). On steady state free precession imaging, hypointense signal at the fat-water interface due to chemical-shift artifact can help in detecting fat, which may be further characterized on double inversion dark blood T1 or T2 weighted fast-spin echo sequences with and without fat suppression. On CT, fat-containing lesions have attenuation values of between -40 and -120 Hounsfield units.

CONCLUSION: Fatty lesions encountered when reporting cardiac MRI and CT fall into two broad categories; fatty masses (cardiac lipoma, pericardial lipoma, mediastinal teratoma, tracheal lipoma and chest wall lipoma) and, fatty replacement of myocardium (lipomatous hypertrophy of the interatrial septum, fatty metaplasia of chronic myocardial infarct, fibrofatty replacement scarring in ARVC/D, intramyocardial lipomata in tuberous sclerosis and sensescent fatty infiltration).

Various fat containing lesions can be visualized on cardiac MRI and CT in routine clinical practice. Familiarity with the imaging techniques and typical imaging features may prevent diagnostic pitfalls.

EE035

INTERVENTIONAL VASCULAR CLOSURE DEVICE COMPLICATIONS

Authors: Adam A. Dmytriw, Christopher B. Lightfoot

LEARNING OBJECTIVES:

1. To acquaint the reader with possible complications that arise from vascular closure devices, and those specific to certain devices.
2. To review indications and contraindications to use of vascular closure devices.
3. To present a discussion of best practices for closure devices use and peri-procedural precautions.

BACKGROUND: Several closure devices are discussed together with their proposed benefits, rates of complication, and a case highlighting an instance of the latter from the literature is included for each device. Finally, additional local cases are presented and suggestions regarding precautions as well as device-specific guidelines are provided.

CONCLUSION:

- Hemostasis at arterial puncture sites has traditionally been achieved with manual compression, and 10-20 minutes of digital pressure is often enough to prevent access site bleeding. However, suture or collagen-based closure devices have achieved wide acceptance for use following vascular interventional procedures.
- Proposed benefits of closure devices include reduced access site complications, reduced time to ambulation/discharge and improved patient comfort. Appropriate patient selection is essential is an important key to these benefits.
- Closure devices can be associated with complications and pain. Judicious use of these devices is imperative, with adherence to correct technique and knowledge of relative contraindications.

EE036

DUAL ENERGY CT AND INTRA ARTERIAL STROKE THERAPY

Authors: Olivia McDonnell, Niv Khorrami, Jason Shewchuk

LEARNING OBJECTIVES:

1. To demonstrate the usefulness of DECT in patients who have undergone intra arterial stroke therapy
2. Illustrate virtual unenhanced and iodine overlay images in these patients.
3. To demonstrate how DECT enables reliable detection of haemorrhagic transformation a known complication of reperfusion therapy

BACKGROUND: A dual-energy CT scanner was used for imaging at 80 and 140 kV, and a three-material decomposition algorithm was used to obtain virtual unenhanced images and iodine overlay images. Follow up single energy CT images were reviewed and correlation performed.

CONCLUSION: DECT is highly accurate in distinguishing intracranial haemorrhage from iodinated contrast staining and has many advantages over MRI including time and cost benefits patients who have contraindications to MRI. It can play a major role in management of acute stroke management and in guiding future antithrombotic therapy

EE037

COMMON RUNNING-RELATED LOWER EXTREMITY INJURIES AND THEIR IMAGING CHARACTERISTICS

Authors: David Russell, Mark Cresswell

LEARNING OBJECTIVES:

1. Briefly discuss the range of running-related health issues, classified anatomically, with a focus on the lower extremity.
2. Review the common clinical symptoms of a wide range of running-related lower extremity injuries, both acute and chronic (with a short counterpoint brief review of the corollary issues related to sedentarism).
3. Highlight each of the above cases with the spectrum of imaging, including ultrasound, MRI, and nuclear medicine.
4. Provide a diagnostic approach to the imaging of the injured distance runner.

BACKGROUND: Distance running puts enormous strains on the human body, both mechanical and physiological. Acute and chronic health issues occur as a result, which can be further subdivided anatomically, most easily into musculoskeletal issues involving the lower extremity and more systemic issues related to the physiologic stresses induce by running.

A brief review of most common running related health issues will be provided, as well a more in-depth and systemic approach of lower extremity running-related injury imaging, using case-based examples.

CONCLUSION: Running-related injury is a common indication for diagnostic imaging, and recognition of particular clinical presentations and their expected imaging findings allows for more refined diagnoses, inevitably leading to more appropriately directed therapy.

This review will attempt to highlight some of these common presentations, providing representative examples of the associated imaging findings, and finally summarize with a diagnostic approach for running-related injuries of the lower extremity.

EE038

PERIOPERATIVE AND POSTOPERATIVE EPILEPSY SURGERY IMAGING – A PICTORIAL ESSAY

Authors: Ravi M. Venkatesh, Mark Franke, Anton Hasso, Jason Handwerker

LEARNING OBJECTIVES:

1. New techniques in imaging including 3D reconstruction and coregistration fusion images for intraoperative guidance are allowing for a more thorough assessment and evaluation of the patient undergoing epilepsy surgery. Familiarity with these types of images is important to the future of epilepsy management.
2. MRI findings of postsurgical patients should not be confused for other similar appearing entities and well known mimics. While difficult to interpret, imaging confounded by artifact from implantable devices can still provide valuable information.
3. Examples of the common and uncommon complications from epilepsy surgery will be shown, such as the characteristic appearance of hemorrhage from subdural grid electrode placement for electrocorticography.
4. Drawing on the approach of a large epilepsy center, imaging examples depicting features in lobectomy, hemispherectomy, corpus callosotomy, multiple subpial transection, and vagal nerve stimulator patients will be demonstrated.
5. Multiple imaging modalities including 3D reconstructions, fusion of images for intraoperative guidance, PET/CT, fMRI and DTI as well as conventional CT and MRI all play important roles in the evaluation of the surgical epilepsy patient.
6. Intraoperative images and detailed anatomical depictions that can help aid in understanding the characteristic radiologic appearances will also be shown.
7. Numerous implantable devices are in use, and knowing the different kinds and their radiologic appearances is important for the neuroradiologist functioning as part of a multidisciplinary team.

BACKGROUND: Medically intractable epilepsy is a challenging problem utilizing a multidisciplinary surgical approach involving neurologists, neurosurgeons, and neuroradiologists. A plethora of surgical techniques, divided into general categories of resective and disconnective procedures, are available to address this issue, each with unique perioperative and postoperative imaging features. Given the complexity of the cases, the increasing number of surgical epilepsy patients, as well as confounding imaging features involving multiple modalities, familiarity with perioperative imaging features is essential for neuroradiologists.

CONCLUSION: Given the increase in epilepsy surgery, neuroradiologists need to familiarize themselves with perioperative and postoperative imaging appearances of surgical epilepsy patients, especially in the setting of newer tools such as 3D imaging. As part of a multidisciplinary team, the neuroradiologist also should be familiar with common implantable devices and associated imaging pitfalls.



All Scientific Exhibits are in digital format and are available for viewing in the foyer of the Salle de bal, 4th floor.
FRIDAY, APRIL 25, 2014 – SATURDAY, APRIL 26, 2014
Prizes for this contest are funded by the Canadian Radiological Foundation (CRF).

Toutes les expositions scientifiques sont en format numérique et peuvent être visionnées dans le foyer de la Salle de bal au 4e étage.
VENDREDI LE 25 AVRIL 2014 – SAMEDI LE 26 AVRIL 2014
Les prix pour ce concours sont financés par la Fondation radiologique canadienne (FRC).

JUDGES / JUGES : Dr. Gregory Butler, Dr. Erik Jurriaans, Dr. Sheldon Wiebe

SE001

ALTERATION IN HEMODYNAMIC PARAMETERS IN OPHTHALMIC AND CENTRAL RETINAL ARTERIES IN INDIAN PATIENTS WITH INCREASING GRADE OF DIABETIC RETINOPATHY

Authors: Syed Wajahat Ali Rizvi, Mayank Sharma, Adeeb Alam Khan, Mohammed Azfar Siddiqui, Abadan Khan Amitava, Zia Siddiqui

OBJECTIVE: Diabetes, with and without retinopathy, is often associated with hemodynamic alterations in ocular blood flow. Color Doppler Imaging (CDI) is an established noninvasive technique that enables measuring blood flow velocities in small orbital vessels. We set out to measure ocular blood flow hemodynamics by Color Doppler Imaging in the ophthalmic artery (OA) and central retinal artery (CRA) in patients with diabetic retinopathy (DR) and to compare it with healthy subjects.

METHODS: We evaluated 61 eyes of 61 subjects, (controls: 21 and diabetics: 40). Diabetic patients were further classified in two groups: diabetics with either no retinopathy or background retinopathy (NDR/BDR; n=20), and diabetics with preproliferative or proliferative retinopathy (PPDR/PDR; n=20). Three Color Doppler parameters: peak systolic velocity (PSV in cm/s), end diastolic velocity (EDV, cm/s) and resistivity index (RI) were measured in the OA and CRA. Statistical analysis was done using ANOVA and Post-Hoc (Tukey) test to compare the results between NDR/BDR, PPDR/PDR and control groups.

RESULTS: No significant difference was seen in the age of the subjects. We found statistically significant differences only in the OA. Specifically, PSV was significantly greater in NDR/BDR Vs controls (95%CI: 2.25 to 14.92); EDV was significantly decreased in PPDR/PDR as compared to controls (95%CI: 0.43 to 4.12) and NDR/BDR (95%CI: 0.13 to 3.80); RI was significantly increased in PPDR/PDR (95%CI: 0.09 to 0.23) and NDR/BDR (95%CI: 0.03 to 0.17) as compared to controls.

CONCLUSION: We found significant circulatory alterations in the OA in diabetic patients suggesting hemodynamic dysfunction. RI was significantly increased in diabetics as compared to controls.

SE002

REDUCING RADIATION DOSE IN CHILDREN WITH TRAUMATIC BRAIN INJURY WHO UNDERWENT COMPUTED TOMOGRAPHY DOES NOT BRING HARM TO THE DIAGNOSIS, MOTIVATES CONTINUING EDUCATION AND PROMOTES RADIOPROTECTION CAMPAIGN

Authors: Sonia T. Narcizo, Monica O. Bernardo, Fernando A. Almeida

OBJECTIVE:

1. To reduce the radiation dose of computed tomography (CT) scans in children with traumatic brain injury (TBI) without losing radiographs quality and without prejudice to the diagnosis.
2. To promote at the work place and for the children's family discussion of strategies to reduce the radiation dose received by children who need health care.
3. To introduce a radioprotection record for each child under 12 years at Unimed Medical Care System (Sorocaba, SP, Brazil).

METHODS: We selected two series of CT from children with TBI performed in Philips 64 channels Multi Slice scanner. Initially we selected the last 30 CT scans performed with usual radiation dose (RD). To the next 30 CT for TBI we applied the protocols to reduce radiation load (approximately 50%) according to the guidelines of The Alliance for Radiation Safety in Pediatric Imaging. The two CT series were presented to 19 pediatricians, two neurosurgeons and seven radiologists blind to the technical differences. The participants answered if they noticed any difference or if they had any difficulty in making the diagnosis comparing the two series of exams and; if they considered useful to implement an individual radioprotection record for each child.

RESULTS: Four participants reported greater "noise" in those CT scans with reduced RD. None had difficulties in making a diagnosis and taking the right medical conduct; and all agreed that the individual radioprotection record would be useful and educative. Unimed Medical Care System developed a radioprotection campaign in the work place for the pediatricians, families and technical staff.

CONCLUSION: It is possible to reduce the radiation dose of CT scans in children with TBI without any prejudice to the diagnosis and treatment; health professionals are motivated to take actions to reduce the radiation load. An individual radioprotection record was created for children up to 12 years where are recorded their radiological examinations; a radioprotection campaign was well accepted by health professionals and families.

SE003

PAIN PERCEPTION IN PATIENTS UNDERGOING CT GUIDED LUNG BIOPSIES

Authors: Zonia Ghumman, Hassan Shoustari, Ravi Menezes, Yasser Karimzad, Demetris Patsios, Narinder Paul

OBJECTIVE: To identify patients at increased risk for procedure related pain during and after CT guided percutaneous fine needle aspiration biopsy (CT-FNAB) of the lung.

METHODS: Institutional Review Board approved prospective recruitment of patients referred for CT-FNAB from February–May 2013. Patients completed 3 questionnaires: 30 minutes prior to CT-FNAB (Q1), 30 minutes post CT-FNAB (Q2) and ≤72 hours post CT-FNAB (Q3). A validated Brief Pain Inventory (BPI) was included to assess pain severity (PS) and pain interference (PI) with daily activities. The radiologist documented use of IV analgesia (fentanyl 50-100mcg) and sedation (midazolam 1mg) during CT-FNAB (Q4).

RESULTS: The study cohort included 50 patients (29 males, 21 females), mean age 65.2 years ([40, 83], SD 9.5). BPI scores [mean (range)] showed PS and PI scores pre-procedure = 1.14 (0-6.8) and 0.93 (0-7.3), and ≤72 hours post-procedure = 1.05 (0-6.3) and 0.58 (0-6.7). Most patients had low mean PS and PI scores pre- and post-procedure. Lying prone during CT-FNAB (36/50) and pre-existing chronic painful conditions (9/50), were associated with higher pain scores($p=0.013$, Mann-Whitney test). Additional IV analgesia and sedation was only required in 5 patients (10%) all of whom were prone during CT-FNAB.

CONCLUSION: Patients with pre-existing painful conditions and those who require prone positioning during CT-FNAB are at higher risk for procedure related pain. Both risk factors can be identified pre-procedure to allow for individualized pain management. Patients that need to be prone during CT-FNAB can be positioned strategically with extra cushioning and given increased analgesia for improved pain management.

SE004

ATRAUMATIC SOLITARY VERTEBRAL COMPRESSION FRACTURE: MRI PATTERNS FOR DISCRIMINATING MALIGNANT FROM BENIGN SPINAL COLLAPSE

Authors: Mohammed Azfar Siddiqui, Ibne Ahmad, Syed Wajahat Ali Rizvi

OBJECTIVE: Atraumatic spinal compression fractures are a commonly encountered problem in clinics, particularly in the elderly patients. Osteoporosis is the most common cause, but malignant condition like metastasis is also frequently seen in the same age group. Discrimination between benign and malignant collapse, although difficult at times, is important because early treatment has significant influence on the clinical outcome. Our aim was to determine MRI findings useful in making this distinction.

METHODS: MRI findings in 16 patients with metastatic collapse and 34 patients with osteoporotic collapse were compared. The presence or absences of following individual imaging criteria were evaluated: Convex bulge of posterior aspect of the vertebral body, retropulsion of a bone fragment, compression of all vertebral columns, areas of normal vertebral marrow signal intensity, presence of low-signal-intensity band on T1- and T2-weighted sequences, abnormal signal intensity of the pedicle and the posterior element, presence of a epidural mass and a paraspinal mass, and heterogeneous pattern of contrast enhancement. The predictive value of each MRI characteristic was tested by statistical analysis by using the chi-square test.

RESULTS: The following MRI findings were significantly associated with malignant collapse: a convex posterior vertebral border, abnormal signal intensity of the pedicle or posterior element, and an epidural mass. The following MRI findings were significantly associated with benign collapse: presence of a low-signal-intensity band on T1- and T2-weighted images, areas of normal bone marrow signal intensity in the vertebral body, and retropulsion of a posterior bone fragment. MRI findings of paraspinal mass, heterogeneous post contrast enhancement and compression involving all vertebral columns were found to be statistically insignificant.

CONCLUSION: Certain MRI characteristics are effective in differentiating benign from malignant vertebral collapse. Discrimination between benign and malignant causes of spinal fracture is very important because of its significant impact on management. MR imaging is a very useful technique for making this distinction.

SE005

SHOULD BREAST ULTRASOUND BE USED TO ASSESS MAMMOGRAPHIC ABNORMALITIES THAT DO NOT PERSIST ON SPOT COMPRESSION VIEWS?

Authors: Betty Tuong, Derek Muradali

OBJECTIVE: Mammographic abnormalities are often evaluated with spot compression views as the first line in the assessment algorithm. If the lesion persists on spot compression views, it is considered an abnormal finding at assessment, and further imaging tests or biopsies are utilized in the management of the lesion. If the abnormality does not persist, it is usually presumed that the lesion was due to summation artifact from normal surrounding parenchymal tissue, and traditionally the assessment has been deemed negative.

While there is rationale for performing an ultrasound in view of a persisting abnormality on spot compression views, it is not clear if ultrasound should be performed on those patients in which the abnormality has resolved on the mammographic work-up. Nevertheless, there is a developing trend in some facilities to use breast ultrasound to complement spot compression views, regardless of the outcome of these mammographic views.

The objective of this study was to determine if the addition of ultrasound in patients with negative spot compression views would detect breast cancers that otherwise would have been missed.

METHODS: Retrospective chart review was performed over a nine and a half year period from April 2004 to October 2013. All patients in our department with negative spot compression views that were further evaluated with a corresponding breast ultrasound were identified.

Mammograms, ultrasounds and pathology from patients who underwent core biopsy due to an abnormal breast ultrasound (BIRADS 4 or 5) were reviewed. This study was approved by the institutional review board at our institution.

RESULTS: 1860 patients were enrolled in the study. 62 patients (3.3%) underwent core biopsy for suspicious ultrasound findings.

Patients were initially referred for asymmetry (32/62), focal asymmetry (16/62), architectural distortion (8/62) or a mass (6/62). Subsequent spot mammograms were deemed negative.

Breast ultrasound demonstrated a region of shadowing (26/62) or a mass (36/62). Core biopsy pathology showed invasive ductal carcinoma (7/62), invasive lobular carcinoma (1/62), ductal carcinoma in situ (2/62), fibrocystic change (10/62), fibroepithelial lesion (5/62), radial scar (2/62), fat necrosis (2/62), benign papillary lesion (2/62) and benign breast tissue (31/62).

Overall, of the 62 biopsies, 10 were malignant on pathology (16%) and the remaining 38 were benign (84%).

CONCLUSION: A small subset of breast cancers can be occult on spot compression views and detected with ultrasound. However, the prevalence of these breast cancers is low, at 0.5% in our population.

Taking this low prevalence into consideration, we question breast whether ultrasound should be used routinely in all patients with negative spot compression views at assessment.

SE007

WIDESPREAD CORTICAL THICKNESS CHANGES IN PATIENTS WITH INSULAR EPILEPSY

Authors: Sara Jamali, Alan Tucholka, Dang K. Nguyen

OBJECTIVE: To investigate extra-insular changes in patients with insular lobe epilepsy in regards to cortical thickness and volume changes.

METHODS: Nine consecutive patients with (operculo-) insular cortex epilepsy (confirmed by MEG, intracerebral EEG and/or post-insulectomy seizure-freedom) with mean age of 36±7 years were identified. Their 3T MRI T1-weighted images were processed with Freesurfer software. Images were segmented to obtain a 3D segmentation of the cortical surface, hippocampus and amygdala. A cortical thickness map and a group versus control-group node-to-node correspondence were performed to assess regions with cortical thickness changes. The control group was composed of 27 right-handed subjects between the ages of 18 and 35. A 2-tailed t test was performed for analyses of volume change.

RESULTS: The results showed regions with decreased cortical thickness in the contralateral insula, ipsilateral posterior cingulate gyrus, ipsi- and contralateral frontoparietal lobes. Volumetric comparison for hippocampus and amygdala did not show changes in the hippocampus in patient group in comparison to the controls. No regions with increased cortical thickness were identified.

CONCLUSION: To our knowledge this is the first study analyzing cortical thickness of insular cortex epilepsy. We show widespread extra-insular changes in the brain in patients with insular lobe epilepsy indicating that pathology in patients with insular cortex epilepsy involves a wide cortical network. These changes could be the result of disease chronicity as similar studies in patients with temporal lobe epilepsy have found cumulative widespread extratemporal cortical changes. Further longitudinal analyses in a larger number of subjects are required.

SE008

EFFECT OF GOVERNMENTAL INTERVENTION ON APPROPRIATENESS OF LUMBAR MRI REFERRALS: A CANADIAN EXPERIENCE

Authors: Sean A. Kennedy, William Fung, Atiqa Malik, Forough Farrokhyar, Mehran Midia

OBJECTIVE: In 2012, the Ontario government attempted to reduce inappropriate lumbar MRI referrals through guideline and decision-aide distributions to physicians as well as threats of financial penalties. Our goals are:

1. To determine if any change in lumbar MRI referral appropriateness occurred post-policy change at a tertiary care hospital in Ontario.
2. To determine if any change in the number of new lumbar MRI referrals occurred post-policy change.

METHODS: 600 lumbar MRI referral forms were randomly selected; 300 pre-policy change and 300 post-policy change. The American College of Radiology's appropriateness criteria for low back pain imaging were utilized to evaluate the appropriateness of each referral and assign a score from 1-9 (1-3=not appropriate;4-6=may be appropriate;7-9=appropriate). The number of new referrals during a 3 month period both pre-policy change and post-policy change was recorded. Student's t-test was performed to test for significant differences post-policy change.

RESULTS: Pre-policy change, 50.4% of lumbar MRI referrals were appropriate while 47.9% were not appropriate. Post-policy change, appropriateness increased with 62.6% being appropriate and 37.1% of referrals being not appropriate. The mean appropriateness score pre-policy change was 5.08 (95%CI,4.74-5.42) and increased significantly post-policy change to 5.79 (95%CI,5.46-6.12, p=0.004). No significant difference in the number of new lumbar MRI referrals pre-policy change (246 per month, SD=20.1) and post-policy change (232.7 per month, SD=38.3) was noted (p>0.05).

CONCLUSION: The Ontario government's interventions have significantly increased the appropriateness of lumbar MRI referrals. However, many referrals remain inappropriate and no change in the number of new referrals has occurred.

SE010

ROLE OF MRI IN DISCRIMINATION OF TUBERCULAR 'VS' PYOGENIC SPONDYLITIS: A COMPARATIVE STUDY

Authors: Mohammed Azfar Siddiqui, Ibne Ahmad, Syed Wajahat Ali Rizvi

OBJECTIVE: It is important to differentiate tuberculous spondylitis (TS) from pyogenic spondylitis (PS) because early treatment has significant influence on the rate of disability. The purpose of this study was to determine the accuracy of MRI for discrimination between TS and PS.

METHODS: MRI findings in 43 patients with TS were retrospectively reviewed and compared with those of 41 patients with PS. The presence or absence of following individual imaging criteria were evaluated and an overall assessment of the type of spondylitis was made- margin of paraspinal abnormal signal, presence of paraspinal and intraosseous abscess, appearance of the abscess walls, involvement of multiple vertebral bodies, involvement of posterior element, extent of subligamentous spread, presence of intervertebral disc narrowing, presence of epidural extension, signal intensity of involved vertebral bodies, and pattern of contrast enhancement. Statistical analysis was performed with chi-square test.

RESULTS: The incidence of the following MRI findings was significantly higher in patients with TS than in those with PS ($p < 0.05$): a well-defined paraspinal abnormal signal, presence of paraspinal or intraosseous abscess, a thin and smooth abscess wall, subligamentous spread to three or more vertebral levels, involvement of multiple vertebral bodies, and hyperintense signal on T2-weighted images. The involvement of the posterior element, presence of intervertebral disc narrowing, presence of epidural extension and contrast enhancement pattern was not significantly different in TS and PS.

CONCLUSION: MR imaging is a very useful technique for assessment of infectious spondylitis and is reliable for differentiation of TS from PS.

SE012

RADIATION EXPOSURE FROM ABDOMEN-PELVIC CT SCANS IN SASKATCHEWAN: COMPARISON WITH HISTORICAL EFFECTIVE DOSE LEVELS AND EVALUATION OF SIZE-SPECIFIC DOSE ESTIMATES

Authors: Matthew Wright, David Leswick, Adil Adatia, Derek Fladeland

OBJECTIVE: To assess radiation dose of abdomen-pelvis (AP) computed tomography (CT) scans in Saskatchewan using both effective dose (ED) (to compare with historical standards) and size-specific dose estimate (SSDE).

METHODS: Dose data were retrospectively collected from the imaging studies of 500 patients (50 patients from each of 10 provincial centres) with dose data archived on provincial PACS, who received AP contrast-enhanced CT examinations. ED and SSDE were calculated, and ED measurements were compared to historical ED data from previous studies.

RESULTS: The median province-wide ED (±MAD) for AP CT studies was 8.4±3.3 mSv for single-phase scans (22.3% decreased from 10.8±2.9 mSv in 2008; $p<0.0001$), 18.9±8.0 mSv for multi-phase scans (not significantly different from 22.0 ± 7.7 mSv in 2008; $p=0.94$), and 10.2±4.9 mSv for all scans (14.3% decreased from 11.9±3.8 mSv in 2008; $p<0.0001$). The percentage of AP CT investigations that were multi-phase increased from 22.0% in 2008 to 26.8% ($p=0.0452$). As expected, size-specific dose estimates were significantly less correlated with patient size than effective dose ($R2=0.39$ and $R2=0.55$, respectively; $p<0.0001$). Provincial variability was greater with SSDE than ED ($p=0.0025$), which might reflect more provincial dose variability than anticipated. Differences between centres will be presented at the meeting.

CONCLUSION: Overall radiation exposure due to AP CT imaging decreased in Saskatchewan from 2008 by 14.3%, although multi-phase imaging utilization increased. Size-specific dose estimate is less affected by patient size than effective dose and may be a better tool to assess how radiation dose changes over time or differs between centres.

SE013

ROLE OF ACCESSORY RIGHT INFERIOR HEPATIC VEINS IN EVALUATION OF LIVER TRANSPLANTATION

Authors: Awais Ahmed, Umar Amin, Sadia Babar, Rashed Nazir, Atif Rana, Muhammad Y. Chaudary

OBJECTIVE: The objective of the study is to access the prevalence of accessory right inferior hepatic veins and their relevant significance in liver transplantation. If the vein is larger than 3 mm or the distance between the confluence of the main hepatic vein into IVC and the accessory vein is more than 4 cm, the surgical approach must be altered to prevent complications such as bleeding and graft malfunction.

METHODS: After approval from IRB, a retrospective study was done in which the CT of 82 potiential liver transplant candidates between January 2012 and March 2013 were reviewed. Venous phase imaging was reviewed in all cases and 3- dimensional reconstructions were performed. Postsurgical cases and cases of vascular thrombosis and arteriovenous malformation were excluded. The presence of the accessory right inferior hepatic vein was examined; the diameters of the accessory inferior hepatic veins and the distance between the point where they open into the inferior vena cava on the coronal plane and to the right hepatic vein-inferior vena cava junction was measured.

RESULTS: Out of 82 patients, 42 (51%) had accessory right inferior hepatic veins. Right accessory inferior hepatic veins larger than 3 mm were detected in 23 (28%) patients. The distance of these veins to the right hepatic vein-inferior vena cava junction was more than 4 cm in 13 (15%) patients.

CONCLUSION: The precise preoperative knowledge of accessory right inferior hepatic veins is essential when planning for the proper outflow reconstruction of grafts in living donor liver transplantation. This emphasizes the fact, "Doing the Right Thing at the Right Time: Appropriate Imaging Utilization".

SE014

BENEFIT OF A SHARP COMPUTED TOMOGRAPHY ANGIOGRAPHY RECONSTRUCTION KERNEL FOR IMPROVED CHARACTERIZATION OF INTRACRANIAL ANEURYSMS

Authors: Brian O'Meara, Jason P. Rahal, Alexandra Lauric, Adel M. Malek

OBJECTIVE: Computed tomographic angiography (CTA) is the first-line imaging modality used for cerebral aneurysms because of its speed and sensitivity for detection, though digital subtraction angiography is often required for more detailed aneurysm shape delineation. We decided to determine if a sharper CTA reconstruction kernel can better characterize an aneurysm and improve decision-making prior to intervention.

METHODS: 15 patients presenting with aneurysmal subarachnoid hemorrhage underwent 64-row CTA. CTA data were reconstructed using the default H20f smooth kernel and a H60f sharp kernel and compared to contemporaneous catheter three-dimensional rotational angiography (3DRA). Aneurysm neck, width, and aspect ratio measurements were made using intensity line-plots of identical projections on all imaging datasets and compared by matched-pair statistics.

RESULTS: Aneurysm neck measurements from the H20f smooth kernel revealed overestimation compared to both the sharp kernel (greater by 0.64±0.21 mm, $p < 0.01$) and 3DRA (greater by 0.68±0.19 mm, $p < 0.01$). There was no statistically significant difference between 3DRA and the sharp kernel CTA measurements. Neck measurements correlated well between the H60f kernel and 3DRA but not between the H20f Kernel and 3DRA (R 0.97 vs. 0.86).

CONCLUSION: H60f sharp CTA kernel reconstruction provides more accurate anatomic characterization of cerebral aneurysms than the H20f smooth kernel at the expense of less visually pleasing reconstructions. Because it does not require additional contrast, radiation, or imaging hardware and is more akin to 3DRA, it may aid in selecting the appropriate treatment strategy prior to evaluation by catheter-based angiography.

SE015

EVALUATION OF PATIENTS' USE OF ONLINE RESOURCES FOR INTERVENTIONAL RADIOLOGY PROCEDURES

Authors: Vinod Ramlal, Sriharsha Athreya

OBJECTIVE: To assess patients' knowledge and use of online resources for patients regarding interventional radiology procedures.

METHODS: From March 1 to April 30, 2013, any adult out-patient who had a procedure performed by interventional radiology in a teaching hospital was asked to complete a voluntary questionnaire. Patients evaluated on a 5-point Likert scale their knowledge and use of online resources regarding their procedure.

RESULTS: Throughout the study 59 patients (age range: 27-93 years, mean age: 60.4 years) completed the study questionnaire.

88.1% (52 of 59) of patients did not access any internet resources regarding their procedure. The most common cited reason by 19.2% (10 of 52) of patients was their physician provided an adequate explanation of the procedure. 73.1% (38 of 52) indicated they would use internet resources if suggested by their physician.

11.9% (7 of 59) of patients accessed internet resources to learn more about their procedure. 100% (7 of 7) of patients agreed the internet resources were beneficial to them prior to their procedure. All 7 agreed or strongly agreed they would like more internet resources to be provided to them by their physician.

CONCLUSION: There is a lack of use of internet resources by patients regarding interventional radiology procedures. However, there is a clear demand by patients for more internet resources to be made available to them by their physicians. Internet resources about interventional radiology procedures should be provided to patients by physicians to improve quality of care by better educating them and ensuring the use of accurate sources.

SE016

THE EFFECT OF EXTRINSIC MATERIAL AND RADIATION DOSE ON VEO RECONSTRUCTION TIME: A PHANTOM BASED STUDY

Authors: Paul Babyn, Geoffrey Karjala, David Leswick, Troy Anderson, Lori Toews

OBJECTIVE: VEO has emerged as a promising reconstruction technique with reduced radiation dose and preserved image quality. However, this comes at the penalty of extended reconstruction times. We evaluated the effect of adding extrinsic material (eg clothing, blankets, and medical devices), and varying radiation dose, to the VEO reconstruction time.

METHODS: Chest section images of a RANDO phantom were acquired on a GE HD750 CT scanner. At a standard dose, a single scout image and 3 diagnostic series were acquired with no extrinsic material added to the phantom; the addition of a light shirt and blanket; and the addition of a light shirt, 3 blankets, 3 ECG leads, ventilation tubing, and a 1000 cc IV bag. This was repeated with a mA reduction of 50% and 90%. Each diagnostic series was processed via VEO, and the reconstruction time recorded. The signal to noise ratio (SNR) was calculated for each study. ANOVA, regression tests and t-tests statistical methods were applied as appropriate.

RESULTS: The VEO reconstruction times ranged from 37:31 (50% dose, clothing) to 42:24 (100% dose, everything). Reconstruction time is statistically significantly longer (5 – 12%) as extrinsic material is added ($p<0.01$ for all). Reconstruction time does not significantly differ with dose when no extrinsic material is added ($p = 1$). Reconstruction time is shorter (4-6%) with decreased dose at both levels of extrinsic material ($p< 0.01$ for both). Variation in extrinsic material has no statistically significant effect on SNR. Decreased radiation dose decreases SNR at all levels of extrinsic material ($p<0.001$ for all). At each combination of dose and extrinsic material, VEO results in a statistically significant increased amount of SNR ($p<0.01$).

CONCLUSION: VEO reconstruction time increases with added extrinsic material. While the effect on any one scan is mild, the cumulative effect over a workday might affect work flow.

SE017

THE FEMORAL HEAD-NECK CONTOUR VARIES AS A FUNCTION OF PHYSEAL DEVELOPMENT

Authors: Anthony Vo, Paul Beaule, Marcos Sampaio, Carmen Rotaru, Kawan Rakhra

OBJECTIVE: The evolution of the cam deformity is not fully understood, although recent studies suggest it develops in adolescence prior to physeal fusion. The purpose of this study was to investigate whether the femoral head-neck contour changes and correlates with the stages of physeal maturation.

METHODS: MRIs of 86 hips from 43 asymptomatic pediatric volunteers (26 males, 17 females) with mean age 13.0 years (range 8 -18 years) were reviewed. Femoral head physes were graded from 1(completely open) to 6(completely fused). The femoral head-neck contour was evaluated using the alpha angle, measured at the 3:00(anterior) and 1:30 (anterosuperior) positions and correlated with physeal grade. Spearman's rank correlation was used to determine correlation. ANOVA was used to analyse the differences between group means. Inter- and Intra-reader reliabilities were determined using intraclass correlation coefficient (ICC).

RESULTS: Correlation between the physeal grade and alpha angle was moderate in males at both the 3:00($r=0.477, p<0.001$) and 1:30($r=0.509, p<0.001$) positions, whereas there was no significance in females at either 3:00($r=0.052, p>0.05$) or 1:30 ($r=0.100, p>0.05$). A significant difference was found between the alpha angles of the physeal grades (3:00 $p<0.05$, 1:30 $p<0.01$), in males, with the angle increasing with higher grades. In females, there was no significant difference at neither the 3:00 ($p>0.05$) and 1:30 positions ($p>0.05$). For physeal grading, the inter-reader reliability for three readers was substantial (ICC=0.694), and the intra-reader reliability for a single reader was also substantial (ICC= 0.788).

CONCLUSION: The femoral head/neck contour varies with the stage of physeal development, but only in males, with the alpha angle increasing with progressive physeal maturation. This suggests that gender differences exist in the natural physiologic growth, development or remodelling of femoral head-neck junction, and combined with higher alpha angles in males, may account for the higher prevalence of cam femoroacetabular impingement in males.

SE018

CONTRAST-ENHANCED MR VENOGRAPHY IN PATIENTS WITH MULTIPLE SCLEROSIS TO ASSESS STENOSES OF THE INTERNAL JUGULAR VEINS. IS THERE CORRELATION WITH CCSVI CRITERIA?

Authors: Satya N. Patro, Carlos Torres, Santanu Chakraborty, Cheemun Lum, Thanh Nguyen, Stefanie Belanger, Lysa Kingstone-Legault, Betty Anne Schwarz, Miguel Bussière, Mark Freedman, Hamid Dabirzadeh, Mark Schweitzer, Rebecca Thornhill, Matthew J. Hogan

OBJECTIVE: Zamboni et al suggest that multiple sclerosis (MS) may develop secondary to Internal jugular vein (IJV) stenosis in his proposed CCSVI hypothesis.

This study assesses the prevalence of IJV stenosis in patients with multiple sclerosis and age matched controls using contrast enhanced MR venography (CE-MRV). Potential correlation of IJV stenosis with CCSVI defined by Doppler ultrasound (US) is evaluated.

METHODS: This was a single-center, prospective, observational study of 50 subjects with a confirmed diagnosis of multiple sclerosis with age-matched controls. REB approval and informed consents were obtained.

CE-MRV was performed on a 3T magnet. US evaluation of the intra and extracranial circulation was used to define CCSVI criteria. Imaging results were reviewed independently by two neuroradiologists blind to subject assignment. From MRV images the degree of stenosis was graded within the lower, mid and upper 1/3 segments of the IJV. US evaluation was considered positive if 2 or more CCSVI criteria were present.

RESULTS: 100 studies were undertaken. 13 could not be evaluated due to poor MRV quality (6 patients, 7 controls). Median ages were 50 for patients and 54 for controls. The female: male was 1.9 for patients and 0.6 for controls. Inter-observer variability for IJV stenosis was fair for lower 1/3 (ICC 0.45 (0.24-0.61)), poor for mid 1/3 (ICC 0.18 (-0.03-0.38)) and good for upper 1/3 (ICC 0.71 (0.58-0.80)) IJV segments.

IJV stenosis was identified in 85 (98%) of subjects. Stenosis >= 50% was identified in 31 (70%) of patients and 32 (74%) of controls and was more probable in both groups in the upper 1/3 IJV segment.

A positive CCSVI score was identified in 12 patients and no controls ($p < 0.001$, Fisher's exact test).

CONCLUSION: IJV stenosis is highly prevalent on MRV and does not distinguish between MS and control subjects. A weak correlation exists between lower 1/3 segment IJV stenosis and CCSVI criteria.

Departmental Clinical Audit Projects | Concours des projets de vérification clinique au sein des services

SATURDAY, APRIL 26, 2014
Departmental Clinical Audit Project Contest – Oral Presentations – Salon 1, 2nd Floor

SAMEDI LE 26 AVRIL 2014
Concours des projets de vérification clinique au sein des services – Présentations orales – Salon 1, 2e étage

JUDGES / JUGES : Dr. Carl Chartrand-Lefebvre, Dr. Najla Fasih, Dr. Ur Metser

MODERATOR / MODÉRATRICE : Dr. Pascale Audet

10:45 – AP001

IMPACT OF IMPLEMENTATION OF THE SIMPLIFIED WELLS CRITERIA ON REFERRALS FOR PULMONARY EMBOLISM

Authors: Michelle Ong, Vincent Leung, Julian Dobranowski, Ehsan Haider

PLACE OF AUDIT: Diagnostic Imaging, St Joseph's Healthcare, Hamilton, ON

BRIEF BACKGROUND: A CT Pulmonary angiogram (CTPA) is the study of choice to evaluate patients with suspected pulmonary emboli (PE). A CT Pulmonary Embolism (CTPE) Algorithm for ordering CTPA studies was developed between the department of Diagnostic Imaging, Emergency Medicine and Hematology which introduced a simplified Wells score to risk stratify patients and determine the investigation pathway for assessment.

AIM OF THE STUDY: To determine the impact of implementation of the simplified Wells criteria on referrals for suspected pulmonary embolism.

METHODOLOGY: A retrospective study was performed collecting data for three months prior and three months following the implementation of the CTPE Algorithm. These are Group 1 and Group 2 respectively. Non emergency outpatients and hospital inpatients were not included in the study. The data fields collected include patient demographics, D-dimer if done and either, clinical information or positive clinical characteristics from the simplified Wells rule, depending which group the patients belonged to.

RESULTS: There was a 21.7% reduction in CTPA studies following the introduction of the simplified Wells criteria. The positive CTPA studies were also higher, averaging 31.2% in Group 2 compared to 21.7% of Group 1. The average age is older in Group 2 but there was no difference in the gender distribution in both groups.

ACTION PLAN: The findings of the audit were used as feedback to the ER and continued review of improving the algorithm to increase the positive rate is under discussion.

10:55 – AP002

AN ISSUE WITH PROXIMITY: A CLINICAL AUDIT OF OPTIC LENS INVOLVEMENT IN CT HEAD

Authors: Paul S. Benvenuto, Neety Panu

PLACE OF AUDIT: Sioux Lookout Meno Ya Win Health Centre, Sioux Lookout, ON

BRIEF BACKGROUND: Computed tomography (CT) of the head is one of the most commonly used diagnostic tools. However, examination of the optic lens usually only plays a minuscule role in patient management and outcome. Unnecessary exposure of the lens to radiation can result in cataract formation.

AIM OF THE STUDY: To minimize the involvement and resulting radiation of the optic lens during CT head studies.

METHODOLOGY: All CT head images performed at our institution between February to May 2013 were examined. Lens involvement meant partial or complete visualization of either lens or, in cases of cataract surgery; the area of the lens was in the field of examination. Images where the orbits were requested were excluded. Re-audit occurred between November and December 2013.

RESULTS: There were 101 studies in the initial audit, of which 78.2% (n=79) involved the lens. Re-audit included 61 studies, with lens involvement in 22.9% (n=14).

ACTION PLAN: Study results and recommendations were brought to the attention of the technologists. By angling the gantry above the level of the orbits and having patients tuck their chin, lens exposure to radiation can effectively be minimized. Re-audit results demonstrated a significant reduction in the number of cases with lens involvement. Of the 14 studies with lens involvement, 71.4% (n=10) were documented as trauma or c-spine mobility issues. Going forward, this study will help save the lens from unnecessary radiation and lens pathology. It is also suggested that clinical reasoning for desired lens involvement be documented.

11:05 – AP003

VENTILATION/PERFUSION SCANS: CLINICAL AUDIT OF NONDIAGNOSTIC SCANS FOLLOWING WIDER APPLICATION OF SPECT AND TRANSITION TO TRINARY REPORTING

Authors: Ashley Mummery, Kristy Romaniuk, Jonathan T. Abele

PLACE OF AUDIT: University of Alberta Hospital, Edmonton, AB

BRIEF BACKGROUND: Based on recent literature, as of July 1 2013 the Nuclear Medicine department at the University of Alberta (UAH) began performing SPECT imaging, when possible, for all ventilation/perfusion (V/Q) scans for diagnosing pulmonary embolism (PE). With this, a trinary system of reporting (no PE, non-diagnostic or PE present) was also introduced.

AIM OF THE STUDY: To assess how many studies are reported as non-diagnostic following these changes.

METHODOLOGY: All relevant lung perfusion scans preformed at the UAH between July 1 2013 and August 31 2013 were reviewed. Our target was that less than 3.5% should be reported as non-diagnostic. ("Successful and Safe Implementation of a Trinary Interpretation and Reporting Strategy for V/Q Lung Scintigraphy" by Glaser et al 2011).

RESULTS: 112 studies were reviewed. Of these, 102 studies were reported using the trinary system. Of these, 8 (7.8%) were reported as non-diagnostic for PE. Target not met.

ACTION PLAN: The non-diagnostic studies will be reviewed by a multidisciplinary team to determine if technical issues contributed to the number of non-diagnostic studies. A re-audit is planned to assess effectiveness of the interventions.

11:15 – AP004

AN AUDIT TO EVALUATE THE DIAGNOSTIC ADEQUACY AND SAFETY OF PERCUTANEOUS ULTRASOUND GUIDED PEDIATRIC LIVER BIOPSY

Authors: Guan Huang, Suki Dhillon, Atilano Lacson, Consolato Sergi, Ravi Bhargava, Michelle Noga

PLACE OF AUDIT: University of Alberta Hospital, Edmonton, AB

BRIEF BACKGROUND: In our institution, percutaneous ultrasound guided pediatric liver biopsies are performed by radiologists with the patients under sedation.

AIM OF THE STUDY: To assess our biopsy adequacy rate and use the results to help unify the approach to pediatric liver biopsy in our institution.

METHODOLOGY: Pediatric liver biopsies in a period of two years (July 1, 2011 – June 30, 2013) were reviewed. Data items collected include patient age, indication for biopsy, needle type and throw, number of passes, operator, details of post-procedural complications and final pathology reports.

TARGET: Diagnostic adequacy 100%. Complication rate (significant bleed/organ puncture) less than 0.5%.

RESULTS: 57 pediatric liver biopsies were performed by 7 radiologists. The age of the patients ranged from 13 day-old to 17 year-old. Eighteen gauge core needles were used in all biopsies.

Fifty-four (95%) biopsies provided adequate amount of core samples (more than 10 mm in length) for various pathology studies. Two (3%) biopsies did not provide enough tissue samples. One (2%) biopsy provided only lung tissues.

Puncture of lung occurred in 1 (2%) biopsy with no pneumothorax identified on subsequent chest radiographs.

TARGETS: Not met.

ACTION PLAN: The results have been discussed with radiologists, pathologists and pediatric gastroenterologists. The data from the audit will be used to formulate a local standardized protocol for pediatric liver biopsy based on the indication for biopsy and patient age. This will be instituted and audited. The protocol will form part of this presentation.

11:25 – AP005

ADEQUATE COMPLETION OF RADIOLOGY REQUEST FORMS – ARE REFERRERS HELPING US TO HELP THEM?

Authors: Bhim J. Odedra, Ciaran Healy, Sunil Dajee, Adam Barnes, Jacobus Kritzinger, Pari Tiwari, Jacqueline Brown, Mark Cresswell, Jason Clement, David Fenton, Darra Murphy, Jennifer Ellis, Michael Martin, Cameron J. Hague, Jonathon Leipsic, Patrick Vos

PLACE OF AUDIT: Radiology Department, St Paul's Hospital, Vancouver, BC

BRIEF BACKGROUND: Radiology request forms (RRFs) are key communication tools between clinicians and radiologists with recognized minimum data parameters required on RRFs encompassing patient demographics, clinical history, the clinical problem/question, and referring physician details. The usefulness of radiological examinations can be reduced if these data are not provided. Inadequate information can lead to mistakes in patient identification, protocolling, with delays in performing and reporting examinations.

AIM OF THE STUDY: Assess the adequacy of completion of RRFs against local and Royal College of Radiologists standards.s

METHODOLOGY: The request forms of all CT and MRI imaging and interventional procedures performed over a period of 1-week in November 2013 were audited. Adequacy of RRF completion was evaluated by assessing the inclusion of the minimum data parameters described in the Background, as well as legibility of RRFs if hand-written.

RESULTS: 859 CTs, 290 MRIs, and 125 interventional procedures were performed. Inadequately completed forms were found across all modalities, most significantly with in-patient CT-imaging and body-intervention where illegible hand-writing was also noted. The "clinical question" was the most frequent major missing data-set. Of further concern was the lack of referring physician contact details on interventional radiology requests. Patient demographics were completed in over 95% of forms.

ACTION PLAN: Letter circulated to heads of clinical services to disseminate to all clinicians the importance of adequately completed RRFs.

Potentially send back incomplete forms on a case-by-case basis. Results of a repeat audit completing the audit-cycle will be presented.

Introduction of electronic requesting with mandatory data fields may reduce inadequate RRFs.

11:35 – AP006

HOW EFFECTIVE ARE RADIOLOGISTS AT RECOMMENDING BONE MINERAL DENSITOMETRY IN PATIENTS WITH FRAGILITY FRACTURES?

Authors: Dean T. Jeffery, Tammy Randon, Jonathan Abele

PLACE OF AUDIT: Department of Radiology and Diagnostic Imaging, University of Alberta, Edmonton, AB

BRIEF BACKGROUND: Current Canadian clinical practice guidelines state bone mineral densitometry (BMD) should be performed in patients > 40 years old who sustain fragility fractures and in all patients > 65 years old.

AIM OF THE STUDY: To determine the current rate of BMD recommendation by radiologists who report acute hip fractures in at risk patients and attempt to improve the rate with educational intervention. Target compliance is 80%.

METHODOLOGY: A retrospective review of hip and pelvic radiographs in patients > 40 years of age from November 2012 to February 2013 at the University of Alberta Hospital was conducted. The primary outcome measure was the rate of BMD recommendation by radiologists reporting acute hip fractures.

Results of the initial review were presented at a departmental research day, a radiologist partnership meeting, and distributed by e-mail to the division members. A standard macro was placed in all dictation accounts to facilitate adoption.

A post-intervention review was performed from August to December 2013.

RESULTS: 50 and 66 acute hip fractures were identified pre-intervention and post-intervention respectively. 22% and 20% of fractures respectively occurred in patients 40 - 65 years of age without a history of high energy trauma. However, no recommendations for BMD were made.

ACTION PLAN: Radiologists at our institution failed to recommend BMD despite indications to do so and educational intervention. Further investigation is required, but lack of motivation and poor education are potential obstacles. Short one-on-one education sessions followed by repeat audit are the next plan of action.

11:45 – AP007

RADIATION REDUCTION USING 80 KV AND 100 KV PROTOCOLS FOR CT PULMONARY ANGIOGRAPHY

Authors: Edward M. Cheung, Bruce G. Gray, Djeven P. Deva

PLACE OF AUDIT: St. Michael's Hospital, Toronto, ON

BRIEF BACKGROUND: Lower-voltage protocols for CT pulmonary angiography (CTPA) reduce the effective radiation dose. However, no studies to date have quantified this dose reduction using internal controls to account for intrapatient factors.

AIM OF THE STUDY: To evaluate the intrapatient dose reduction with lower-voltage CTPA at our institution since introducing new protocols in April 2013.

METHODOLOGY: Retrospective analysis of patients who underwent CTPA at 80kV (BMI <23 kg/m2), 100kV (BMI 23-30 kg/m2), and 120kV (standard) between April 1, 2013 and December 31, 2013, was performed. Global statistics for these groups were calculated on ICRP-103 effective doses. 80kV and 100kV cases that had also undergone 120kV CTPA between January 1, 2010 and December 31, 2013, were included in a sub-analysis using paired t-test statistics.

RESULTS: 65 patients underwent CTPA at 80kV, 127 patients at 100kV, and 427 patients at 120kV. The average doses and standard deviations for the 80kV, 100kV, and 120kV groups were 2.9±0.8 mSv, 5.2±1.7 mSv, and 10.8±4.0 mSv, respectively.

10 patients in the 80kV group and 20 patients in the 100kV group also underwent 120kV CTPA. Statistically-significant mean dose reductions of 46% (2.6 mSv; 95% CI 1.6-3.6 mSv) for 80kV and 38% (3.2 mSv; 95% CI 2.1-4.2 mSv) for 100kV, compared to 120kV, were achieved (both $p<0.01$).

ACTION PLAN: A letter will be circulated informing radiologists and CT technologists of the audit's findings in order to increase the number of lower voltage studies performed on patients who meet the protocol criteria. A follow-up audit will be performed in a year's time to track progress.

11:55 – AP008

CLINICAL AUDIT OF THYROID BIOPSY ADEQUACY

Authors: Michael Kozoriz, Dipinder Keer, Patrick Vos, Tiwari Pari

PLACE OF AUDIT: St. Paul's Hospital, Vancouver, BC

BRIEF BACKGROUND: Ultrasound guided fine needle aspiration cytology is a principal method to characterize thyroid nodules. Commonly the Bethesda system is used to classify aspirates. Samples classified as "non-diagnostic or unsatisfactory" can be a source of frustration for referring clinician, patient, radiologist and pathologist. An inadequacy rate of approximately 13% has been cited in the literature.

AIM OF THE STUDY: To define inadequate thyroid biopsy rate at our institution. Change practice if required. To compare inadequacy rates pre and post intervention.

METHODOLOGY: Two full audit cycles were performed. First cycle: all thyroid biopsy results at our institution were reviewed over a 3 month period in 2012. Post audit interventions were two-fold. First a change in sample storage solution from Normosol buffer to cytolyt fixative. Secondly sonographic characteristics of all biopsied lesions were communicated with the pathologist particularly of cystic lesions. Appropriate cysts were subsequently reported by the pathologists as cyst fluid only rather than as an inadequate or non-diagnostic sample. During the second cycle, post-intervention, all thyroid biopsy results were reviewed for a 2 month period in 2013.

RESULTS: Pre-intervention 178 samples were reviewed and 32% were found to be non-diagnostic/unsatisfactory. Post-intervention 104 samples were reviewed and the non-diagnostic/unsatisfactory rate declined to 10%.

ACTION PLAN: By changing the thyroid biopsy storage solution and by making the pathologist aware of nodule characteristics, we were able to reduce the number of samples reported as "non-diagnostic or unsatisfactory".

12:05 – AP009

COLONIC AND EXTRACOLONIC FINDINGS OF COMPUTED TOMOGRAPHIC COLONOGRAPHY IN A NON-SCREENING CANADIAN POPULATION AT AN ACADEMIC CENTRE

Authors: Amanzo Ho, Kelly A. MacLean, Jacques Trollip, Gordon Andrews, Alison C. Harris

PLACE OF AUDIT: UBC Hospital, Vancouver, BC

BRIEF BACKGROUND: CT colonography (CTC) has been shown to be a sensitive and specific imaging test for the detection of colonic polyps. At our institution, the most common cohort of individuals having CTC are those that require primary screening for colorectal cancer and are unable to tolerate, or have failed, optical colonoscopy.

AIM OF THE STUDY: This study aims to evaluate our institution's CTC performance in detecting colonic lesions and to assess the clinical and financial impact of extracolonic findings in a non-screening population.

METHODOLOGY: Retrospective review of CTC studies completed between June 2012 and July 2013 at the University of British Columbia Hospital was performed. Patients with significant colonic (C-RADS C3-C4) or extracolonic findings (E-RADS E3-E4) were analyzed for follow-up polypectomy/surgery and extracolonic investigations.

RESULTS: Two hundred and twenty CTC studies (mean age ±SD, 65.3±11.1 years) were analyzed. A history of failed colonoscopy was noted in 131 patients (59.5%). The distribution of C-RADS and E-RADS findings were as follows: C0-5.9%, C1-66.4%, C2-17.3%, C3-6.4%, C4-4.1%, E0-0.9%, E1-25.5%, E2-45%, E3-20.9%, and E4-7.7%. CTC detected 21 polyps/masses >/= 10mm in 19 patients. Follow-up polypectomy/surgery was completed successfully in 17 of these patients, with 15/19 of the evaluated polyps confirmed (78.9%). There were 26 follow-up investigations for extracolonic findings (0.12 per patient), amounting to an additional cost of $36.89 per patient.

ACTION PLAN: Our institution's sensitivity of CTC examinations for colonic polyps >/= 10mm meets the published standards (>75%). A re-audit is recommended in the future to ensure that CT colonography quality metrics are continuing to be met.

SATURDAY APRIL 26, 2014
Radiologists-in-Training Awards – Oral Presentations – Salon 1, 2nd Floor
Prizes for this contest are funded by the Canadian Radiological Foundation (CRF).

SAMEDI LE 26 AVRIL 2014
Concours pour les radiologistes en formation postdoctorale – Présentations orales – Salon 1, 2e étage
Les prix pour ce concours sont financés par la Fondation radiologique canadienne (FRC).

JUDGES / JUGES : Dr. Pavel Crystal, Dr. Angus Hartery, Dr. Matthew McInnes

MODERATOR / MODÉRATRICE : Dr. Micheline Thibodeau

13:30 – RT001

CONGENITAL BRONCHOPULMONARY MALFORMATIONS (BPMS) – PRENATAL SONOGRAPHIC FEATURES WITH POSTNATAL CORRELATIONS

Authors: Juliette Garel, Laurent Garel, Françoise Rypens, Chantale Lapierre

OBJECTIVE: According to C. Langston classification, BPMs include bronchogenic cysts (BC), bronchial atresias (BA) either isolated or associated with intralobar pulmonary sequestrations (ILPS), congenital pulmonary airways malformations (CPAMs) type 1 and 2, and extralobar pulmonary sequestrations (ELPS).

Routine US has resulted in a marked increase in prenatally recognized BPMs.

Recent literature on congenital lung lesions emphasized the lack of correlations between imaging and pathology. Our objective is to compare the prenatal sonograms of BPMs and postnatal diagnoses.

METHODS: Retrospective study over 10 years in a single institution cohort.

Pre and postnatal imaging performed in same radiology department.

Prenatal descriptors: timing of conspicuity, lesion echogenicity, macrocysts, vascular connections (systemic feeder, venous return), bronchocele.

Postnatal diagnoses based upon pathology (surgical cases) or postnatal CT (non operated cases).

RESULTS: 115 cases including 56 surgical cases and 5 upcoming interventions.

Postnatal diagnoses: BC (n=5), CPAM (n=33), PS (n=33) including 11 hybrid lesions (coexisting PS and CPAM), trapping (n=32) including 10 BA, suprarenal PS/hybrid (n=12).

Non surgical cases (n=54): suprarenal location (n=12), spontaneous regression (n=17), embolization (n=3), lost to FU (n=8), expectant management (n=12), fetal demise (n=2).

Prenatal ultrasound and post natal correlations:

- All BPMs visible on mid 2nd trimester US
- Macrocystic BPMs: CPAM type 1 and 2 or hybrid lesions
- Echoic lesions with systemic vascularisation: PS
- Echoic lesions without systemic vascularization: trapping. Bronchocele seen in BA.

CONCLUSION: Conspicuity timing: BPMs always visible on 18-22 WGA sonogram, to the contrary of fetal pulmonary tumors (5 cases in our data bank).

PS almost equally made of ELPS and ILPS: value of color doppler US for assessing venous return.

Focal echoic lesions without systemic feeder likely to be trapping (no CPAM type 3 in our series of born alive patient). Fetal bronchocele very suggestive of BA.

Overall, excellent ultrasound pathology correlations resulting in an improved management (investigations and treatment options) postnatally.

13:40 – RT002

IN SEARCH OF CRITERIA SUPPORTING CHRONIC CEREBROSPINAL VENOUS INSUFFICIENCY (CCSVI) IN PATIENTS WITH MULTIPLE SCLEROSIS

Authors: Satya N. Patro, Carlos Torres, Santanu Chakraborty, Cheemun Lum, Thanh Nguyen, Stefanie Belanger, Lysa Kingstone-Legault, Betty Anne Schwarz, Miguel Bussière, Mark Freedman, Hamid Dabirzadeh, Mark Schweitzer, Rebecca Thornhill, Matthew J. Hogan

OBJECTIVE: Chronic cerebrospinal venous insufficiency (CCSVI) was initially proposed by Palo Zamboni, is a condition closely associated with (MS) and is caused by stenoses within the venous drainage of the brain and spinal cord. We undertook the current study to confirm if these observations are present in a cross section of MS patients as well as in a group of age-matched controls.

METHODS: It's a single-center, prospective study of 50 subjects with MS and 50 age-matched controls, who underwent Doppler ultrasound evaluation. REB approval and informed consent was obtained. Subjects were randomly selected from a list of volunteers divided into 6 MS categories (relapsing remitting (RR), secondary progressive (SP), and primary progressive (PP) of either less than or greater than 10 years duration). Controls were age-matched relatives or friends.

An ultrasonographer, blind to the status of the study subject, evaluated the intra and extracranial venous circulation.

Two neuroradiologists blind to subject group independently evaluated the studies to document CCSVI criteria with a study considered positive if 2 or more criteria were present. Evaluators were asked to reach consensus on disagreement between positive study results.

RESULTS: Recruitment was completed over 5 months. Median ages were 52 for patients and 52.5 for controls. The female: male was 1.9 for patients and 0.6 for controls. Inter-observer variability for CCSVI criteria was good (ICC 0.89 (0.85-0.93)). Consensus between observers was obtained for a CCSVI score >= 2 in 4 subjects.

Our primary outcome of a positive CCSVI score >= 2 was found in 13 subjects. All were in the patient group with no positive results in the control group ($p < 0.001$, Fisher's exact test). At least one DCV signal was identified in 77% of subjects but no reflux was seen.

CONCLUSION: We identified CCSVI criteria in a small subset of subjects with MS. Our results do not support CCSVI as a cause or key pathogenetic factor in MS.

13:50 – RT003

DISCLOSURE OF THE RESIDENT ROLE IN THE INTERVENTIONAL RADIOLOGY SUITE: HOW DO INTERVENTIONAL RADIOLOGISTS BALANCE PATIENT CARE AND RESIDENT EDUCATION?

Authors: Rebecca Zener, Daniele Wiseman

OBJECTIVE: The objectives of this study are to investigate:

1. How interventional radiologists determine the intra-procedural role of residents;
2. What interventional radiologists disclose to patients about the role of radiology residents in the IR suite;
3. How interventional radiologists balance their responsibility between delivering excellent patient care and providing hands-on training to radiology residents.

METHODS: A qualitative study consisting of in-person interviews with 7 academic interventional radiologists from 3 tertiary care centres was conducted. Interviews were transcribed, and underwent modified thematic analysis whereby overarching themes were extracted from the transcripts. The study protocol and interview guide were fully approved by the University Research Ethics Board.

RESULTS: Five major themes emerged.

1. Interventional radiologists permit residents to perform increasingly complex procedures with graded responsibility. While observed technical ability is an important factor determining the extent of a resident's intra-procedural participation, possessing good judgment and knowing personal limitations are paramount.
2. Interventional radiologists do not explicitly inform patients in detail about residents' intra-procedural role, as trainee involvement is viewed as implicit at academic institutions.
3. While patients are advised of radiology resident participation in IR procedures, detailed disclosure of their intra-procedural role is viewed as potentially detrimental to both patient well-being and trainee education.
4. Interventional radiologists recognize the trust and confidence placed in them by patients. While it is rare that patients refuse resident participation in their care, interventional radiologists' duty to respect patient autonomy supersedes their obligation to resident education.
5. Ultimately, interventional radiologists hold responsibility for any intra-procedural, trainee-related complication.

CONCLUSION: Interventional radiologists recognize the confidence placed in them, and they do not inform patients in detail about residents' role in IR procedures. Respecting patient autonomy is paramount, and while rare, obeying patients' wishes can potentially be at the expense of resident education. Future studies investigating interventional radiology patients' perspective may be beneficial for patient-centered care.

14:00 – RT004

ARE CHEST CT REQUISITIONS DANGEROUSLY INCOMPLETE?

Authors: Matthew Walker, Daria Manos, Joy Borgaonkar

OBJECTIVE: Technological advancements and the ever-increasing use of Computed Tomography (CT) have greatly increased the detection of incidental findings. The management of many "incidentalomas" depends on the pre-test probability of malignancy, which is significantly influenced by a patient's history of cancer. The study aim is to evaluate the quality of CT requisitions for patients who have a history of cancer to determine whether referring physicians provide adequate clinical information to report the CT findings.

METHODS: Retrospective chart review comparing information included on the CT requisition with patient responses to a questionnaire, completed at this time of CT scan.

Setting: Nova Scotian tertiary care hospital during the month of April 2012.

Participants: 569 requisitions for chest CTs were reviewed. Patients were excluded from the study if the patient questionnaire was incomplete or if the purpose of the CT was for cancer staging or follow up.

Main outcome measures: Patient self-reporting of cancer history compared to information supplied by the referring physician.

RESULTS: 327 patients met inclusion criteria. 79 of the 327 patients reported a history of cancer on the patient questionnaire. 49% (95% CI [0.38, 0.61]) of the requisitions did not include the patient's previous history of cancer. Of the 43 cancers that were omitted from requisitions 35% (n=15) were cancers that commonly metastasize to the lung.

CONCLUSION: A significant number of requisitions for chest CT scans fail to disclose a history of cancer. Because the importance and management of incidental findings is heavily dependent upon the presence or absence of a known malignancy, these incomplete requisitions may lead to errors in radiology reports.

14:20 – RT006

THE EXPOSURE DEFICIT: A QUALITATIVE STUDY OF MEDICAL STUDENT OPINIONS AND PERCEPTIONS OF RADIOLOGY

Authors: Kari L. Visscher, Georges Nassrallah, Lisa Faden, Daniele Wiseman

OBJECTIVE: According to a national survey of over 900 Canadian medical students, the misperception of an isolated radiologist working flexible hours in a dark room continues to persist. Since the future of radiology depends on recruiting well-informed medical students that are motivated to further advance the field, identifying the factors that perpetuate the misperceptions is needed. The purpose of this study is to explore the ways exposure to radiology in medical school impacts on the personal, contextual and experiential factors that shape students' perceptions, interest, and choice to pursue or not pursue a career in radiology.

METHODS: After receiving ethics approval from Western's Research Ethics Board, 4 focus groups were conducted, one per year of undergraduate medical training at Western University. Semantic realist thematic analysis was performed on the transcribed audio recordings and accompanying notes, as well as on the open-ended questions obtained from the national survey.

RESULTS: 556 students in medical school years 1 and 2 (preclerkship) participated in the national survey and 18 in the focus groups. 332 students in years 3 and 4 (clerkship) participated in the national survey and 10 in the focus groups. Participants considering a career in radiology were 29% in the focus groups and 21% in the national survey. In both studies, the number of medical students considering a career in radiology was highest in year 1. From the national survey, 71 students contributed free text opinions to the open-ended questions.

Three major themes emerged from the analysis of the data. (1)Informal interactions perpetuate radiology stereotypes, but students want accurate information to refute or support these perceptions. (2)There is limited exposure to radiology in medical school, especially in preclerkship. (3) Students want to know that you care and enjoy your job, that your work has value and impact, and what to expect from a career in radiology.

CONCLUSION:

1. Medical students, especially those in preclerkship, want accurate information to modify or reinforce the persistent radiology stereotype.
2. Every contact you have with a medical student has a significant impact, either positive or negative.
3. To help create meaningful and caring interactions explain, engage, offer and converse.

14:30 – RT007

ARE WE MISSING TRAUMATIC BOWEL AND MESENTERIC INJURIES?

Authors: Bret A. Landry, Michael N. Patlas

OBJECTIVE: Traumatic bowel and mesenteric injury (TBMI) is an uncommon entity that can be lethal if not detected and treated in a timely manner. The purpose of our study was to evaluate the diagnostic accuracy of 64MDCT for the detection of TBMI in patients at our level 1 trauma centre.

METHODS: We used our hospital's trauma registry to identify patients with a diagnosis of TBMI from January 1, 2006 to June 30, 2013. Only patients who had a 64MDCT scan at presentation and subsequently underwent laparotomy/laparoscopy were included in the study cohort. Using the surgical findings as the gold standard, the accuracy of prospective radiology reports was analyzed.

RESULTS: Of the 4781 trauma patients who presented to our institution, 44(0.9%) had surgically proven TBMI. 22/44 were excluded as they did not have MDCT before surgery. The study cohort consisted of 14 males and 8 females with a median age of 41.5 years and a median Injury Severity Score of 27. 17/22 had blunt trauma and 5/22 had penetrating injury. A correct preoperative imaging diagnosis of TBMI was made in 14/22 of patients. The overall sensitivity of the radiology reports was 63.6% (95% CI: 41-82%), specificity was 79.6% (95% CI: 67-89%), PPV was 53.9% (95% CI: 33 -73 %) and NPV was 85.5% (95% CI: 73-94 %). However, only 59% (10/17) of patients with blunt injury had a correct preoperative diagnosis. Review of the findings demonstrated that majority of patients with missed blunt TBMI (5/7) demonstrated only indirect signs of injury.

CONCLUSION: The detection of TBMI in trauma patients on 64MDCT can be improved, especially in patients presenting with blunt injury. Missed cases in this population occurred because the possibility of TBMI was not considered despite the presence of indirect imaging signs.

14:40 – RT009

MAGNETIC RESONANCE IMAGING FOR THE DETERMINATION OF FEMORAL HEAD PHYSIS CLOSURE STATUS

Authors: Anthony Vo, Paul Beaule, Marcos Sampaio, Carmen Rotaru, Kawan Rakhra

OBJECTIVE: Traditional reference age thresholds are currently used to predict the femoral head physis closure status. Historically, these were derived based on radiographs, although MRI would be expected to allow more accurate assessment of the physis due to its cross-sectional capability. The purpose of this study was to compare MRI with age threshold technique for the determination of femoral head physis closure.

METHODS: 82 hips in 41 asymptomatic pediatric volunteers, 25 males (10-18 years) and 16 females (8-16 years), were imaged with 1.5T MRI using a T1 weighted, three dimensional, isotropic gradient echo sequence with radial reformations. Images were reviewed by two blinded readers, classifying the femoral head physis as open (including partially fused) or closed (completely fused). Age thresholds for femoral head physis closure were 16 years in males and 14 years in females, above which closure would be expected. Using MRI as a reference standard, the ability for the age threshold technique (Age) to predict physis closure was evaluated. Inter- and intra-observer reliability of MRI assessments were evaluated using intraclass correlation coefficient (ICC). The number of closed physes, determined by MRI and Age methods was tabulated.

RESULTS: The sensitivity, specificity, positive predictive value, negative predictive value and accuracy of Age for detecting physis closure were 0.79, 0.81, 0.46, 0.95, 0.80, respectively, for Reader 1 and 0.89, 0.78, 0.33, 0.98, 0.79 for Reader 2. Strong intra-observer (ICC=0.659,$p<0.001$) and fair inter-observer(ICC= 0.353,$p<0.001$) reliabilities were found for MRI evaluation of physis status. Age classified 26(16 males, 10 females) physes as closed, whereas MRI found only 11(7 males, 4 females) and 8(5 males, 3 females) physes to be closed, for Readers 1 and 2, respectively. Readers 1 and 2 identified 9/16 and 11/16 male physes over the age threshold of 16 years, and 4/8 and 5/8 females physes over the age threshold of 14 years, with open physes respectively.

CONCLUSION: Traditional age thresholds overestimate proximal femoral head physis closure in males and females compared to MRI.

15:30 – RT010

DOES DISTANCE MATTER? PRESENCE OF A CT SCANNER WITHIN THE EMERGENCY DEPARTMENT AND ITS EFFECT ON REQUISITION, DIAGNOSTIC AND DISPOSITION TIMES FOR EMERGENCY PATIENTS

Authors: Wilfred Dang, Ania Z. Kielar, Angel Y. Fu, Suzanne T. Chong, Matthew McInnes

OBJECTIVE: Shortening the time from computed tomography (CT) requisition to completion of imaging may improve emergency room (ER) workflow, and affect outcomes for patients with acute abdominal emergencies. We hypothesize that having a CT scanner close to the ER will decrease the time between imaging requisition and completion, as well as having an effect on final patient disposition.

METHODS: A retrospective study was conducted of 2,142 consecutive, abdominal imaging requests from our two affiliated academic ER departments from August 1 to October 31, 2012. Both are acute, tertiary care, teaching hospitals that share the same, rotating, radiology staff and residents. The CT scanner is present in the ER department at one campus while at the other, it is located approximately 300m away from the ER. Imaging requests indicated for trauma were excluded, since only once center is the designated trauma center. Patients were stratified based on indication for the abdominal/pelvic CT (hyperacute, acute, and subacute), those requiring oral contrast, radiologist training level, and the time of day (morning, evening and overnight) in which the scan was completed. Three time points were compared between hospitals: 1) ER CT requisition to scan completion, 2) CT scan completion to the preliminary report by staff to the ER, and 3) CT requisition to patient disposition.

RESULTS: The approximate difference in average times between hospitals for: CT requisition to CT completion, CT completion to preliminary/verbal report, and from CT requisition to final disposition, are 16 ($P<0.0001$), 15 ($P<0.0001$), and 19 minutes ($P<0.04$), respectively. Consistently, times were significantly shorter when the CT scanner was placed within the ER department instead of the radiology department. Differences were also notable for subacute and acute ER indications, as well as morning and evening shifts between hospitals.

CONCLUSION: The presence of an ER CT scanner improves ER efficiency by decreasing time to CT scan completion, radiological interpretation and patient disposition times.

15:40 – RT011

COMPARISON OF THE DIAGNOSTIC ACCURACY OF CLINICAL EXAMINATION AND MRI FOR DETECTING TRAUMATIC MENISCAL LESIONS WITH ARTHROSCOPY AS THE REFERENCE STANDARD

Authors: Mohammed Azfar Siddiqui, Ibne Ahmad, Aamir bin Sabir, Syed Wajahat Ali Rizvi

OBJECTIVE: There is growing trend towards using MRI over clinical examination in evaluation of traumatic meniscal lesions. The aim of our study was to compare diagnostic accuracy of CE and MRI versus arthroscopic findings in cases of traumatic meniscal lesions.

METHODS: A total of 51 patients of traumatic knee injury were identified and prospectively reviewed clinically, with MRI scan followed by arthroscopy. All patients had a clinical examination and criteria used for diagnosis of meniscal injury included history, medial and lateral joint line tenderness test, Apley test and McMurray's test. CE and MRI findings were compared with the arthroscopic findings. Sensitivity, specificity, positive predictive value (PPV), negative predictive value (NPV), and overall accuracy of clinical diagnosis and MRI in evaluation meniscal lesions were then calculated.

RESULTS: Arthroscopic evidence of medial meniscal injury was found in 19 out of 25 clinically suspected cases and 18 out of 31 cases with positive MRI scan. CE had better sensitivity (86.4% vs. 75%), specificity (79.3% vs. 51.9%), PPV (76% vs. 58.1%), NPV (88.5% vs. 70%), and diagnostic accuracy (82.4% vs. 62.7%) than MRI for medial meniscal tears. Arthroscopic evidence of lateral meniscal injury was found in 7 out of 9 clinically suspected cases and 8 out of 11 cases with positive MRI scan. There was only marginal difference in sensitivity (58.3% vs. 61.5%), specificity (94.9% vs. 92.1%), PPV (77.8% vs. 72.7%), NPV (88.1% vs. 87.5%), and diagnostic accuracy (86.3% vs. 84.3%) in diagnosis of lateral meniscal injury using CE and MRI respectively.

CONCLUSION: Carefully performed clinically examination is better or as reliable as MRI in diagnosis of traumatic meniscal lesions. Using MRI as a routine diagnostic supplement to the clinical examination is unnecessary. MRI should be used to rule out such injuries rather than to diagnose them.

15:50 – RT012

LIVER MRI WITH GADOFOSOVESET TRISODIUM (ABLAVAR™)

Authors: Helen M. Cheung, Martin Shoichet, Caitlin T. McGregor, Megan Snoyer, Masoom A. Haider, Liang Zeng, Chirag Patel, George Tomlinson, Calvin Law, Laurent Milot

OBJECTIVE: Distinguishing benign from malignant focal liver lesions can be challenging, but is crucial for patient prognosis and management. Pilot studies suggest that the blood-pool MRI contrast agent, Gadofosoveset, may be useful in distinguishing benign from malignant lesions. The goal of this study is to compare the dynamic enhancement pattern of Gadofosveset with extracellular contrast agent Gadobutrol.

METHODS: We conducted a retrospective study of patients who have received both Gadobutrol- and Gadofosveset-enhanced liver MRI's at our institution between September 2009 and May 2013. Signal intensities of liver lesions relative to background parenchyma in the arterial, portovenous, 5-minute delayed, and 10-minute delayed phases relative to the precontrast phase were measured. Enhancement patterns for benign and malignant lesions across time points as well as enhancement patterns at each time point were compared for Gadofosoveset versus Gadobutrol, adjusting for correlation and clustering. Statistical significance was achieved at $p<0.05$.

RESULTS: Our study included 28 patients with 33 benign solid lesions (hemangiomas, focal nodular hyperplasia, and adenoma) and 118 malignant lesions (colorectal, breast, melanoma, and neuroendocrine metastases and mixed hepatocellular carcinoma-cholangiocarcinoma). The model showed a difference in enhancement pattern between benign and malignant lesions for Gadofosoveset and Gadobutrol (ß for interaction=0.35±0.17, p=0.03). There was a significant difference in the enhancement ratio with Gadofosoveset versus Gadobutrol for malignant lesions in the arterial (mean difference=-0.23, p=0.002), 5-minute delayed (mean difference=-0.30, p=0.02), and 10-minute delayed (mean difference=-0.22, p=0.01) phases, but no difference for malignant lesions in the portovenous phase or at any time point for benign lesions.

CONCLUSION: There is a greater difference in enhancement pattern between benign and malignant lesions for Gadofosoveset than for Gadobutrol. There was a significant difference in the enhancement with Gadofosoveset versus Gadobutrol for malignant lesions at the arterial, 5-minute delayed and 10-minute delayed phases, but not for malignant lesions in the portovenous phase or at any time point for benign lesions.

16:10 – RT014

IS ORAL CONTRAST NECESSARY FOR MDCT OF EMERGENCY ROOM PATIENTS WITH ACUTE ABDOMINAL PAIN?

Authors: Abdullah Alabousi, Michael N. Patlas

OBJECTIVE: The purpose of this study was to validate the hypothesis that discontinuing the use of oral contrast (OC) for multidetector computed tomography (MDCT) studies of the abdomen and pelvis will not affect the detection of acute abnormalities in emergency room (ER) patients.

METHODS: We conducted a retrospective study to assess the effect of eliminating OC use for MDCT scans of the abdomen and pelvis (AP) for patients with BMI greater than 25 presenting with acute abdominal pain to the ER. The study was approved by the research ethics board at our institution. Informed consent was waived. Patients with BMI less than 25 continued to receive oral contrast. All patients who underwent AP 64-MDCT imaging in the portal venous phase without oral contrast were included. The electronic medical records were reviewed to determine the rate of repeat imaging within one week from initial CT scan, as well as delayed or missed diagnoses related to the lack of OC.

RESULTS: 1378 patients had an AP 64-MDCT between November 1 2012 and October 31 2013. 375 patients met the inclusion criteria (174 males/201 females, mean age 57, range 18-97). Only 7 patients had repeat CT examination with OC within 7 days (1.9%). Of these 7 patients, none had a change in the course of their management due to the utilization of OC. No delayed or missed diagnoses related to the lack of OC were identified.

CONCLUSION: Imaging patients with BMI greater than 25 presenting with acute abdominal pain in an ER setting resulted in no delayed or missed diagnoses. There was a need for repeat imaging in a small fraction of patients.



16:20 – RT015

MRI EVALUATION OF BECKER MUSCULAR DYSTROPHY

Authors: Neda Faridian-Aragh, Kathryn R. Wagner, Doris G. Leung, John A. Carrino

OBJECTIVE: There is little information on MRI phenotypes of Becker muscular dystrophy (BMD). This study presents the MRI phenotyping of a large cohort of BMD patients and is the first to assess involvement of their upper extremities.

METHODS: The MR images of 116 muscular dystrophy subjects were evaluated by a radiologist who was blinded to the diagnoses. Subsequently, the 33 subjects with confirmed molecular diagnoses of BMD were selected for further analysis. Axial proton density and T2-weighted non-fat saturated MR images of bilateral shoulders, arms, pelvis and thighs were obtained. A semi-quantitative scale was used to rank the muscles. Descriptive statistics were used to analyze distribution, symmetry and severity of involvement. A muscle was considered to be affected in a subject if changes of fatty infiltration were observed in at least one side. Involvement was considered to be frequent if it was observed in75% or more of subjects and infrequent if it was observed in less than 10% of subjects. Muscle involvement was considered to be symmetric if severity scores on the left and right sides were within one grade of each other. If a muscle was symmetrically involved in 75% or more of subjects, it was classified as highly symmetric. The severity of involvement in individual muscles was determined by calculating the mean score for each muscle for all subjects.

RESULTS: Teres major, triceps long head, biceps brachii long head, gluteus maximus, gluteus medius, vasti, adductor longus, adductor magnus, semitendinosus, semimembranosus, and biceps femoris showed the highest severity and frequency of involvement. All analyzed muscles showed high frequency of symmetric involvement. There was significant variability of involvement between muscles within some muscle groups.

CONCLUSION: Our study of BMD subjects showed a distinctive MRI pattern of involvement of extremity muscles.

16:30 – RT016

RATE OF DUPLICATE PUBLICATION IN RADIOLOGY JOURNALS

Authors: Chris J. Hong, Matthew D. McInnes, Rebecca M. Hibbert, Wilfred Dang, David Li, Zuhaib Mir

OBJECTIVE: The purpose of our study was to evaluate the rate of duplicate publication in radiology journals for articles published from 1993 to 2009 using a database of highly similar citations. Secondary objectives were to determine: a) whether the rate of duplicate publications differs between journals; b) if the rate has changed over time; c) the association with impact factor.

METHODS: Déjà Vu, a database of highly similar citations, was used to search for citations in radiology journals from 1993 to 2009. Citations were screened independently by two reviewers and subsequently verified by a third using pre-defined criteria to determine whether the citations were true cases of duplicate publications. The overall rate of duplicate publications was calculated, and an analysis of rate by journal, impact factor and publication year was performed. In addition, the percentage of Déjà Vu 'flagged' citations deemed to be duplicates was calculated.

RESULTS: From the 128,818 citations in the included journals, 1,786 were flagged as duplicates by Déjà Vu, but only 225 were deemed to be true duplicate publications after careful review giving an overall rate of 1.75/1,000 citations. The rate varied widely across journals from 0 to over 9/1,000 citations, showed a negligible inverse correlation with impact factor and showed a decline over the last three years.

CONCLUSION: Duplicate publications in radiology journals are relatively uncommon but the rate varies widely between journals. Recent declines in the rate of duplicate publications indicate that measures implemented to reduce this may be effective.

16:40 – RT017

COMPARISON OF DUAL ENERGY SUBTRACTION CHEST RADIOGRAPHY AND TRADITIONAL CHEST X-RAYS IN THE DETECTION OF PULMONARY NODULES

Authors: Farheen Manji, Jiheng Wang, Geoff Norman, Zhou Wang, David Koff

OBJECTIVE: Dual energy subtraction (DES) radiography is a powerful but underutilized technique which aims to improve the diagnostic value of an x-ray by separating soft tissue from bones, producing two different images. Compared to traditional chest x-rays, DES requires exposure to higher doses of radiation but may achieve higher accuracy. The objective of this study was to assess the clinical benefits of DES radiography by comparing the speed and accuracy of diagnosis of pulmonary nodules with DES versus traditional chest x-rays.

METHODS: Five radiologists and five radiology residents read the DES and traditional chest x-rays of 51 patients, 34 with pulmonary nodules and 17 without. Their accuracy and speed in the detection of nodules were measured using specialized image display software.

RESULTS: DES radiography reduced reading time from 13 sec. to 10 sec. ($p<.0001$) in staff and from 21 sec. to 15 sec. in residents ($p<.0001$). There was also a small increase in sensitivity .58 to .67 overall ($p< 10$) with no change in specificity (.85 overall).

CONCLUSION: By eliminating rib shadows in soft tissue images, DES improved the speed and accuracy of radiologists in the diagnosis of pulmonary nodules.

The Canadian Radiological Foundation

Fondation radiologique canadienne

DONATE TODAY

Join us in promoting the art and science of radiology through research and education. The future of medical imaging and radiology's impact on the future of the Canadian healthcare system lies with you. Through your support we can make a major contribution to helping future generations see beyond and discover new frontiers.

FAITES UN DON AUJOURD'HUI

Joignez-vous à nous à promouvoir la radiologie en tant qu'art et science par notre implication dans la recherche et l'éducation. L'avenir de l'imagerie médicale et son impact sur le système de soins de santé au Canada dépendent de vous. Grâce à votre appui, nous pouvons contribuer largement à aider les générations futures à voir au-delà et à découvrir de nouvelles frontières.

www.car.ca/crf 613 860-3111 foundation@car.ca

The CRF is a registered charity, BN 871123337

La FRC jouit du statut d'organisme de bienfaisance, BN 871123337

Faculty

Corps professoral

SHIELA APPAVOO, FRCPC

Medical Imaging Consultants, Edmonton, AB, Canada

Dr. Appavoo is a general radiologist living and working in Edmonton. She has a particular interest in breast imaging. Her current involvement with the CAR includes chairing the Breast Imaging Working Group, which recently revised the *CAR Practice Guidelines and Technical Standards for Breast Imaging and Intervention.*

MODERATOR

- Breast Imaging: Pg 42

MOSTAFA ATRI, MD

University of Toronto, Toronto, ON, Canada

Dr. Atri is Director of Ultrasound, Joint Department of Medical Imaging, professor of radiology, and head of abdominal imaging at the University of Toronto. Dr. Atri is a Member of the Gynecology Committee of ACRIN (American College of Radiology Imaging Network).

PRESENTATION:

- Acute Abdominal Pain: Don't Investigate the Patient to Death – Right Lower Quadrant Pain: Pg 39

PASCALE AUDET, MD, FRCPC

Centre hospitalier de l'Université de Montréal, Montréal (QC), Canada

La Dre Audet a complété ses études en radiologie diagnostique à l'Université de Montréal en 1999. Elle a par la suite effectué un fellowship en imagerie abdominale à l'Hôpital général de Montréal, affilié à l'Université McGill, et à Paris à l'Hôpital Beaujon. Elle pratique en milieu universitaire au CHUM en imagerie abdominale depuis ses débuts avec des secteurs d'intérêt particulier en imagerie hépatobiliaire, colorectale et uro-oncologique.

La Dre Audet poursuit présentement une formation de maîtrise internationale en administration de la santé (qualité-performance) à l'École de santé publique de l'Université de Montréal, par le biais du programme QUEOPS-i. Elle poursuit sa pratique diversifiée en radiologie abdominale et pelvienne. Elle est conseillère à l'exécutif du CMDP du CHUM depuis quelques années, démontrant ainsi un intérêt grandissant en administration de la santé – secteur qualité-sécurité-optimisation de processus et gestion de risque.

MODERATOR:

- Departmental Clinical Audit Project Contest: Pg 49

MANON BÉLAIR, MD

Centre hospitalier de l'Université de Montréal, Montreal, QC, Canada

Dr. Bélair is an assistant professor at the University of Montreal and has been working as a neuroradiologist at the CHUM since 1999, where she teaches and leads the Head and Neck Imaging Section. She obtained a master's degree in audiology and speech therapy in 1988 and went on to graduate in radiology in 1998 from the Université de Montréal. Dr. Bélair also completed a one-year MRI fellowship at the Université de Montréal and the Mallinckrodt Institute of Radiology in St. Louis (U.S.) prior to accepting her current position.

PRESENTATION:

- Back to Basics – Head & Neck – Head and Neck Case Emergencies: Should I Call the Surgeon?: Pg 47

STEVEN BELLEMARE, MD, FRCP

Canadian Medical Protective Association, Ottawa, ON, Canada

Dr. Bellemare completed his medical training at the University of Ottawa, and his residency in pediatrics at the University of Alberta. Having specialized in child abuse pediatrics, he worked as part of the child protection team at the IWK Health Centre and Dalhousie University in Halifax. During that time, he gained expertise in the preparation of medico-legal reports and learned to communicate in an efficient and prudent manner with police, social workers, and lawyers. He was called upon to testify as a medical expert numerous times before joining the CMPA in November 2009.

MODERATOR:

- Slipping Through the Cracks and Into the Courtroom: A Mock Trial: Pg 56

RAVI BHARGAVA, MD, FRCPC

University of Alberta / Stollery Children's Hospital, Edmonton, AB, Canada

Dr. Bhargava, founder of pediatric radiology, is a graduate of the University of Ottawa (medical school and radiology residency) who completed fellowships in MRI at St. Jude Children's Research Hospital and in pediatric radiology at the University of Tennessee. He is a professor at the University of Alberta, partner at Medical Imaging Consultants, program director of the Pediatric Radiology Residency program, site leader of radiology at the Stollery Children's Hospital, a Royal College of Physicians and Surgeons of Canada examination board member, and an avid golfer.

His research interests include MRI contrast agents, fetal MRI, and the use of MRI in surgical research protocols. His main love is teaching, and he is actively involved in teaching medical students and residents from a variety of disciplines. He is also involved in supervising master's and doctorate students in radiology.

PRESENTATION:

- Back to Basics – Pediatric – Pediatric: Neuroradiology: Pg 53

ANA-MARIA BILAWICH, MD, FRCPC

Vancouver General Hospital, Vancouver, BC, Canada

Dr. Bilawich is staff cardiothoracic radiologist at Vancouver General Hospital, clinical assistant professor of radiology at the University of British Columbia and co-director of the cardiothoracic imaging fellowship at the Vancouver General Hospital. She has a special interest in teaching.

PRESENTATION:

- Back to Basics: Chest – Pulmonary Infection: Pg 45

ROBERT BLEAKNEY, MB, BAO, BCH, FRCPSC

Mount Sinai Hospital, Toronto, ON, Canada

Dr. Bleakney attended medical school at Queen's University in Belfast, Northern Ireland, and completed a radiology residency at Aberdeen Royal Infirmary in Aberdeen, Scotland. His fellowship in musculoskeletal radiology was completed in Toronto. Currently, Dr. Bleakney is a staff musculoskeletal radiologist at the Joint Department of Medical Imaging, comprising UHN, Mount Sinai and Women's College Hospitals; head of the Musculoskeletal Division, musculoskeletal fellowship supervisor, and assistant professor at the University of Toronto. His clinical and research interests are in clinician education, sports imaging, musculoskeletal tumors, bone density, and atypical femoral fractures.

PRESENTATION:

- Mistakes We All Make – Musculoskeletal: Pg 55

HEATHER BRAY, FRCPC

BC Children's Hospital, Vancouver, BC, Canada

Dr. Bray is a pediatric radiologist at the British Columbia Children's Hospital and clinical associate professor at the University of British Columbia. She is the director of the pediatric radiology fellowship and of ultrasound at the BC Children's Hospital.

PRESENTATION:

- Resident Review – Pediatric: Pg 38

PATRICE M. BRET, MD

University of Toronto, Toronto, ON, Canada

Dr. Bret is the former chair of medical imaging at the University of Toronto, and the former radiologist-in-chief at the Joint Department of Medical Imaging in Toronto.

He has always been interested in the role played by intuitions and emotions in leadership. During his recent sabbatical, he studied the science of consciousness and the psychology of happiness. He also went to an accredited coaching school and became a Leadership Coach. He currently leads a campaign, the Happiness Transformation Project, to raise the level of happiness among healthcare professionals.

PRESENTATION:

- Young Radiologists – Work-Life Balance and Happiness at Work: Pg 51

GREGORY J. BUTLER, FRCPC FACR

Valley Regional Hospital, Canning, NS, Canada

Dr. Butler has held many years of leadership positions with the CAR, ACR, CMA, CRF, RSNA, Doctors Nova Scotia, and the College of Physicians and Surgeons of Nova Scotia. Currently, he is chair of the CAR Practice Guidelines Working Group and a Director of the Canadian Radiological Foundation. He is a recipient of the Editor's Recognition Award for reviewer of the *Journal of the American College of Radiology* and is also a reviewer for *Radiographics*.

Dr. Butler is a frequent guest speaker at CAR ASMs and Medical Informatics ASMs. He has career-long interest in issues of quality and professionalism in radiology, teleradiology and informatics, and the sustainability of the Canadian healthcare system. He is also the cofounder and Chair of Real Time Medical Inc.

PRESENTATION:

- The Right Thing – Teleradiology: Is Appropriateness Impacted? : Pg 36

CONTEST JUDGE

Faculty | Corps professoral

YANNICK CARTIER, MD, FRCPC

Hôpital du Sacré-Cœur de Montréal, Montréal (QC), Canada

Le Dr Cartier est présentement chef du Département de radiologie, Hôpital du Sacré-Cœur de Montréal et professeur adjoint de clinique à l'Université de Montréal depuis 2012. Après avoir complété sa résidence en radiologie diagnostique à l'Université de Montréal et ensuite son fellowship en imagerie thoracique à l'University of British Columbia en 1998, il occupa le poste de chef de section d'imagerie thoracique (Département de radiologie) au Queen Elizabeth II Health Sciences Centre de l'Université Dalhousie pendant 10 ans. Il occupa ensuite le poste de chef du service de radiologie diagnostique à l'Hôpital du Sacré-Cœur de Montréal et de professeur adjoint de clinique à l'Université de Montréal en 2011. Il consacra aussi quatre ans (2008–2012) à l'Hôpital du Sacré-Cœur de Montréal, où il était chef de section d'imagerie thoracique et professeur adjoint de clinique dans leur Département de radiologie.

PRESENTATION:

- Mistakes We All Make – Chest: Pg 55

SILVIA D. CHANG, MD, FRCPC

University of British Columbia, Vancouver, BC, Canada

Dr. Chang is a radiologist at Vancouver General Hospital and associate professor of radiology at the University of British Columbia (UBC). She is also the UBC Radiology Residency Program Director. Dr. Chang completed her medical degree and her diagnostic radiology residency at the University of British Columbia. She then completed an abdominal imaging fellowship at the University of California, San Francisco. Following her fellowship, she returned to Vancouver to become a staff radiologist at Vancouver General Hospital. Her areas of interest are abdominal imaging and medical education.

PRESENTATION:

- Acute Abdominal Pain: Don't Investigate the Patient to Death – Right Upper Quadrant Pain: Pg 39

CARL CHARTRAND-LEFEBVRE, MD

Centre hospitalier de l'Université de Montréal (CHUM), Montreal, QC, Canada

Dr. Chartrand-Lefebvre is currently a radiologist at the University of Montreal Medical Centre (CHUM), Cardiothoracic Section and clinical professor at the Faculty of Medicine, University of Montreal. He is also director of the chest and cardiac imaging fellowship programs in the Department of Radiology, University of Montreal, and associate researcher at the CHUM Research Centre.

CONTEST JUDGE

TANYA P. CHAWLA, FRCPC

Joint Department of Medical Imaging, University of Toronto, Toronto, ON, Canada

Dr. Chawla graduated from the University of London, Charing Cross and the Westminster Medical School (UK), and completed her radiology residency training at the University of Southampton (UK).

She completed her fellowship in abdominal imaging at the University of Toronto. Prior to taking up her current post as assistant professor at the JDMI, she was a staff radiologist in abdominal and oncological imaging at the Portsmouth Hospital in the UK.

She leads the CT Colonography program at the JDMI and is Head of GI Imaging. She is also head of body imaging at the Women's College Hospital. Her research interests remain in GI imaging and gynecology and she is heavily involved in teaching at the postgraduate and undergraduate levels.

PRESENTATION:

- Gynecology – Imaging of the Endometrium: Pg 46

MODERATOR:

- Back to Basics – Body Imaging: Pg 50

CHRISTINA M. CHINGKOE, MD

Department of Medical Imaging, University of Toronto, Toronto, ON, Canada

Dr. Chingkoe is a PGY-4 resident from the University of Toronto. She completed her medical school training at the University of British Columbia. Although she enjoys many aspects of radiology, her main interests are in abdominal and genitourinary imaging.

PRESENTATION:

- The Thinking Radiologist – Jeopardy: Radiology Style: Pg 54

MODERATOR:

- The Thinking Radiologist – Jeopardy: Radiology Style: Pg 54

ANIKA CLARK, LLB

Gowlings, Ottawa, ON, Canada

Ms. Clark is an associate in Gowlings' Ottawa office practicing with the advocacy law group. She specializes in the areas of medical defence, with a focus on professional liability, medical malpractice and disciplinary matters, and Aboriginal land claims.

She has represented clients at the Superior Court of Justice and before the College of Physicians and Surgeons of Ontario, the Health Professions Appeal and Review Board, and at coroners' inquests.

During her studies, she completed internships in the federal government with the Supreme Court of Canada and the Public Prosecution Service of Canada. Prior to attending law school, she worked as a project manager for Central and Eastern Canada for the national non-profit organization, Youth Canada Association (YOUCAN).

PRESENTATION:

- Slipping Through the Cracks and Into the Courtroom: A Mock Trial: Pg 56

ERROL COLAK

University of Toronto, Etobicoke, ON, Canada

Dr. Colak is a staff radiologist at St. Michael's Hospital and an assistant professor at the Department of Medical Imaging, University of Toronto. He is actively involved in many educational initiatives and is supervisor of the cross-sectional body imaging fellowship at St. Michael's Hospital. His main research interests include genitourinary imaging, bowel imaging, gynecologic malignancies, and medical informatics.

PRESENTATION:

- Case of the Day – Body: Pg 44

BENVON CRAMER, MD, FRCPC

Memorial University/Health Science Centre, St. John's, NL, Canada

Dr. Cramer completed her undergraduate and initial postgraduate training at University College Cork, Ireland. She underwent diagnostic imaging residency training in London (U.K.) and fellowship training in pediatrics and neuroradiology at McGill University from 1982 to 1984.

In 1984, Dr. Cramer was appointed to the Diagnostic Imaging Department at the Health Care Corporation of St. John's, Janeway site, and as clinical assistant professor of radiology at Memorial University of Newfoundland. She progressed to clinical professor of radiology in 1998 and was appointed professor and chair of radiology at Memorial University of Newfoundland in April 2001.

Dr. Cramer has had an active research career with numerous presentations and publications, mainly in ultrasound in pediatrics and, more recently, teleradiology and discrepancies in pediatric imaging.

PRESENTATION:

- Back to Basics – Pediatric – Pediatric: MSK Imaging: Pg 53

MODERATOR:

- Back to Basics – Pediatric: Pg 53

MARK E. CRESSWELL, MB BCH, FRCPC

University of British Columbia, Vancouver, BC, Canada

Dr. Cresswell grew up in South Africa, where he did his undergraduate training in anthropology and medicine. He initially started specializing in anesthesia before moving to do his radiology residency at St. Mary's Hospital in London and musculoskeletal fellowship in Oxford, after which he moved to Vancouver. He had great fun assisting with the management and imaging at the Vancouver Olympic and Paralympic Games in 2010. He still likes to get involved in "real" medicine, and has been actively involved with Médecins Sans Frontières for the past 12 years, currently serving on the boards of the MSF Operational Center in Geneva, and as the Vice-Chair of the MSF-Canada Board.

PRESENTATION:

- Live Ultrasound Simulation Workshop – Approach to Ankle Tendons & Ligaments: Pg 38

PAVEL CRYSTAL, MD, FSBI

Mount Sinai Hospital, Princess Margaret Hospital, Women's College Hospital, University of Toronto, Toronto, ON, Canada

Dr. Crystal is Division Head of breast imaging at the Joint Department of Medical Imaging, Mount Sinai Hospital, Princess Margaret Hospital, and Women's College Hospital and assistant professor of radiology at the University of Toronto.

Throughout his career, Dr. Crystal has authored more than 30 peer-reviewed manuscripts and 2 editorials in the field of breast imaging. He has been a reviewer for several scientific journals, including *NEJM, Radiology, Investigative Radiology, European Radiology*, and *Canadian Association of Radiologists Journal*.

For his contributions to the field of breast imaging, Dr. Crystal has been named Fellow of the Society of Breast Imaging. He also received the 2010 Radiology Editor's Recognition Award for reviewing with distinction.

Dr. Crystal serves on the Ontario Quality Management Partnership Mammography Expert Panel. He is a member of the Breast Imaging Standards Board Working Group and Chair of the Breast Disease Referral Guidelines Working Group for the Canadian Association of Radiologists (CAR).

CONTEST JUDGE

SAMER DABBO, MD

University of Toronto, Toronto, ON, Canada

Dr. Dabbo is a PGY-3 resident in diagnostic radiology at the University of Toronto. He completed medical school at the University of Toronto and currently sits on the University of Toronto Ultrasound in Undergraduate Medicine Committee.

PRESENTATION:

- How I Do It – Live Action – Transthoracic Ultrasound: What Every Radiologist Should Know: Pg 48

SAM J. DANIEL, MDCM, FRCSC

McGill University, Montreal, QC, Canada

Dr. Daniel received his medical degree from McGill University and completed his postgraduate training in otolaryngology-head and neck surgery at the McGill University Health Centre. Following this, he completed a pediatric otolaryngology fellowship at the Hospital for Sick Children. A tireless learner, he was recently designated Clinical Scholar by the American Academy of Otolaryngology.

Dr. Daniel is a clinician-scientist. He established the McGill Auditory Sciences Laboratory, a world-class facility developing models to further the diagnosis and treatment of hearing loss. He also runs a busy tertiary care clinical practice in pediatric otolaryngology at the Montreal Children's Hospital, where he heads the otolaryngology division.

Dr. Daniel is an associate professor at McGill University. He won the Best Teacher Award three times over the past five years and has been an instructor at the American Academy of Otolaryngology. He has chaired the pediatric group of the Canadian Society of Otolaryngology and sits on the executive council of the Canadian Society of Otolaryngology. He currently sits on a number of international faculty panels, program committees, and advisory boards and is the director of CPD for the federation of medical specialists of Quebec.

Dr. Daniel is a recipient of multiple awards, including Canada's Top 40 Under 40. However, the two awards that perhaps speak the most for his character are: the Montreal Children's Hospital Foundation's Medical Award of Excellence, "awarded to a physician whose exceptional patient care, superior knowledge, valued teaching abilities and generous accessibility to the Hospital Community are an inspiration to others", and the McGill Faculty of Medicine Ronald Douglas Naymark Award, "awarded to the member of the graduating class who most enriches the life of the class in the eyes of his peers, and most inspires trust, confidence, optimism, and enthusiasm in his medical colleagues".

PRESENTATION:

- Young Radiologists – Continuing Professional Development: Where Are We Going, and Why Should I Care?: Pg 51

RAQUEL DEL CARPIO-O'DONOVAN, FRCPC

McGill University, Montreal, QC, Canada

Dr. del Carpio-O'Donovan has been recognized by the McGill Faculty of Medicine in their Honour List for Educational Excellence, by the Royal College of Physicians and Surgeons of Canada as Mentor of the Year, and by the Quebec Medical Association with a Clinician-Teacher Award. She is also considered one of the 10 Most Influential Hispanics in Canada. Dr. del Carpio-O'Donovan is a frequent international speaker and member of educational boards in ISMRM, ASNR and SILAN. She has served on the Board of Directors of the Canadian Association of Radiologists, in their ASM Working Group and is currently on the Board of Directors of the Canadian Radiological Foundation.

MODERATOR:

- Young Radiologists: Pg 51

CAROLE DENNIE, MD, FRCP

The Ottawa Hospital, Ottawa, ON, Canada

Dr. Dennie is a professor at the University of Ottawa in the Department of Diagnostic Imaging with a cross-appointment to the Department of Medicine (Cardiology). She is a medical graduate from the University of Ottawa and did her residency at the University of Ottawa and McMaster University. She completed fellowship training in thoracic radiology and pursued additional subspecialty training in cardiac MRI.

Dr. Dennie is head of thoracic and cardiac imaging at The Ottawa Hospital and co-director of cardiac radiology at the University of Ottawa Heart Institute. She is Director of Continuing Medical Education in the Department of Diagnostic Radiology at the University of Ottawa. She is also Vice-Chair of the Diagnostic Radiology Examination Committee of the Royal College of Physicians and Surgeons of Canada.

CHAIR:

- CAR 77th Annual Scientific Meeting

MODERATOR:

- Plenary Sessions: Pg 34 and 35

IVAN DIAMOND, MD

University of Toronto, Toronto, ON, Canada

Dr. Diamond is currently a PGY-4 resident in diagnostic radiology at the University of Toronto and the Chief Resident of that program. Dr. Diamond transferred to radiology from general surgery after completing a PhD in clinical epidemiology. Prior to his transfer, Dr. Diamond had an interest in critical care, and continues to teach Advanced Life Support to healthcare professionals at various levels.

PRESENTATION:

- How I Do It – Live Action – What to Do When Everything Goes Wrong: Pg 48

GINA DI PRIMIO, MD, FRCPC

Ottawa Hospital and University of Ottawa, Ottawa, ON, Canada

Dr. Di Primio is currently head of the Musculoskeletal Section at the Ottawa Hospital and associate professor at the University of Ottawa. She completed her undergraduate education and medical school at the University of Ottawa with a bachelor's in biochemistry/biology. She also completed her diagnostic radiology residency at the University of Ottawa with the first year in Ottawa on a rotating internship. Her musculoskeletal fellowship was subsequently completed at the Mayo Clinic (Jacksonville and Rochester) under the supervision of Drs. Thomas Berquist and Laura Bancroft. She then went on to complete a mini-fellowship with Dr. Caroline Reinhold in Montreal, Quebec in body MRI, specializing in pelvic MRI imaging. Upon completion of her fellowship, she returned to Ottawa to lead the musculoskeletal section at the Ottawa Hospital.

Her special interests include bone and soft tissue tumor imaging, arthritis, ultrasound and MRI imaging in MSK, peripheral nerve imaging as well as the female pelvis.

PRESENTATION:

- Live Ultrasound Simulation Workshop – Approach to Ankle Tendons & Ligaments: Pg 38

GUS DOTSIKAS, MD, PhD, FRCPC

Lakeridge Health, Oshawa, ON, Canada

Dr. Dotsikas received his undergraduate degree and PhD in experimental surgery from McGill University. He attended medical school and completed his radiology residency training at the University of Toronto.

Dr. Dotsikas has been the Chief/Medical Director of Diagnostic Imaging and staff radiologist at Lakeridge Health, a multi-site institution in Ontario, for 13 years.

He is the regional lead for diagnostic imaging in the central east Local Health Integration Network for the Cancer Imaging Program, one of the clinical programs of Cancer Care Ontario.

Dr. Dotsikas is the Chair of the Synoptic Reporting multi-disciplinary committee at Cancer Care Ontario. Their mandate is to promote and expand the use of synoptic reporting in cancer imaging by radiologists.

PRESENTATION:

- The Thinking Radiologist – Debate – Should Structured Reporting be Mandatory?: Pg 54

NAJLA FASIH, FRCR

University of Ottawa, Ottawa, ON, Canada

Dr. Fasih has been a fellowship-trained staff abdominal radiologist and associate professor in the Abdominal Imaging Division at the University of Ottawa since 2006.

Dr. Fasih's subspecialty interests include oncological and gynecological imaging. She has been involved in several teaching and research initiatives at the University of Ottawa and is the humble recipient of teaching awards, both at undergraduate and postgraduate levels. She has been a course director for several CME courses as well.

CONTEST JUDGE

GIRISH M. FATTERPEKAR, MBBS, MD

NYU Langone Medical Center, New York, NY, USA

Dr. Fatterpekar is an associate professor of radiology at NYU Langone Medical Center. He received his MBBS from King Edward Memorial Hospital in Mumbai and completed his radiology residency and neuroradiology fellowship at Mount Sinai, New York.

Dr. Fatterpekar has received several awards including cum laude, magna cum laude and summa cum laude awards from ASNR and RSNA. He has received numerous teaching awards, including the Outstanding Teacher Award from Mount Sinai, NY for 2008 and 2009, and Attending of the Year for 2010.

Dr. Fatterpekar's main areas of interest are brain tumor and temporal bone imaging. His scholarly work includes more than 70 articles. He has co-authored 3 textbooks. He serves as the section editor for the *AJNR* Case-of-the-Week and Case-of-the-Month. He is on the Scientific Program Committee of ASNR and ASHNR. He has been a member of the Executive Committee of ENRS, serving as its program chair in 2011 and president in 2012.

PRESENTATION:

- Back to Basics – Head & Neck – Temporal Bone Imaging: Hear It to Master It: Pg 47

KAREN FINLAY, MD

McMaster University, Hamilton Health Sciences, Hamilton, ON, Canada

Dr. Finlay completed her residency in diagnostic radiology and a musculoskeletal fellowship at McMaster University. She is a full-time staff radiologist at Hamilton Health Sciences, Juravinski Hospital, and an associate professor of radiology at McMaster University. Scholarly work includes numerous peer-reviewed publications, scientific exhibits and presentations at national and international meetings. Book chapters include musculoskeletal ultrasound and residency education. She is a member of the International Skeletal Society and Society for Skeletal Radiology and is an invited speaker and demonstrator at national and international meetings.

Recently appointed as Associate Chair of Education and Department Education Coordinator for radiology at McMaster, Dr. Finlay also served as Residency Program Director from 2001–2012. Dr. Finlay is an examiner for the Royal College of Physicians and Surgeons of Canada and serves on the Examination Board executive.

PRESENTATION:

- Live Ultrasound Simulation Workshop – Approach to Ankle Tendons & Ligaments: Pg 38

BRUCE B. FORSTER, MSc, MD, FRCPC

University of British Columbia, Vancouver, BC, Canada

Dr. Forster is professor and head at the University of British Columbia (UBC) Department of Radiology, head of Diagnostic Imaging, Vancouver Coastal Region, and Director of Medical Imaging at Vancouver General and University of British Columbia hospitals. He was recently director of diagnostic imaging for the Vancouver 2010 Winter Olympics/Paralympics Games. As an associate member of the Allan McGavin Sports Medicine Centre, he has been involved in the clinical, education, and research aspects of sports imaging for 17 years. He is associate editor of the journals *Radiology* and *British Journal of Sports Medicine*, and is on the Honorary Editorial Board of *Open Access Journal of Sports Medicine*. He is the author of over 95 peer-reviewed scientific publications and 98 educational exhibits, and has served as president of the Pacific Northwest Radiology Society, and on the Board of Directors of the CAR.

PRESENTATION:

- Slipping Through the Cracks and Into the Courtroom: A Mock Trial: Pg 56

JAMES D. FRASER, MD, FRCPC

Queen Elizabeth II Health Sciences Centre, Dalhousie University, Halifax, NS, Canada

Dr. Fraser is a cardiac radiologist and professor of radiology and cardiology at Dalhousie University in Halifax. He is the immediate past president of the Canadian Association of Radiologists and a member of the Choosing Wisely Canada Working Group. He is also the co-chair of the Nova Scotia Provincial Diagnostic Imaging and Laboratory Quality and Patient Safety Working Group.

PRESENTATION:

- The Right Thing – Appropriate Use of Imaging in Canada: Pg 36

BENOÎT GALLIX, MD, PhD

McGill University, Montreal, QC, Canada

Dr. Gallix is professor of radiology and medicine at McGill. After completing medical school and radiology residency at the University of Montpellier (France) in 1995, he joined the McGill Department of Radiology for a clinical fellowship in abdominal imaging. He then returned to the Montpellier University Hospital and Medical School for 15 years where he was appointed full-time professor (tenured) in 2006.

His work focused on abdominal imaging, both diagnostic and interventional, with special interest in liver cancer. His main interest is developing new imaging techniques for the detection of cancer, as well as methods to assess early response of tumours to treatment.

PRESENTATION:

- Young Radiologists – Leadership Roles: Pg 51

PHYLLIS GLANC, MD, FRCPC(C)

Sunnybrook Health Science Centre, Toronto, ON, Canada

Dr. Glanc is an associate professor at the University of Toronto, based at Sunnybrook Health Sciences Centre. She currently is co-director of the Obstetrical Ultrasound Centre of Sunnybrook Health Sciences Centre and a member of the body division within the Department of Medical Imaging.

PRESENTATION:

- The Right Thing – Imaging Appropriateness In Pregnancy: What to Choose, When and Why: Pg 37
- The Thinking Radiologist – Jeopardy: Radiology Style: Pg 54

MODERATOR:

- How I Do It – Live Action: Pg 48

ALISON C. HARRIS, BSc(Hons), MBChB, MRCP, FRCR, FRCPC

Vancouver General Hospital, Vancouver, BC, Canada

Dr. Harris is a clinical associate professor at the University of British Columbia and a staff radiologist at the Vancouver General and University of British Columbia hospitals. She is the medical head of the Abdominal Division and the Abdominal Fellowship Program Director.

Dr. Harris attended medical school at the University of Leicester, England and undertook her radiology residency at St Mary's Hospital in London, England. She did a fellowship in abdominal imaging and intervention at Vancouver General Hospital (1999–2000). She worked at the BC Cancer Agency in Vancouver for three years and then at the University Health Network in Toronto for one year, returning to Vancouver in 2004. She has been on staff at VGH since 2005. Her clinical and research interests are in CT and MR imaging of the abdomen, non-vascular intervention, contrast-enhanced ultrasound and non-invasive methods of assessing liver fibrosis. She is a member of the Liver Tumor Board and of the Prostate Imaging group.

PRESENTATION:

- Gynecology – Benign Uterine Pathology: Diagnosis and Management Options: Pg 46

CONTEST JUDGE

ANGUS HARTERY, FRCPC, ABR

St. Clare's Mercy Hospital, St. John's, NL, Canada

Dr. Hartery currently works as a diagnostic imager at Eastern Health, Newfoundland. He trained as a radiology resident at Memorial University in St. John's with subspecialty training in abdominal imaging at the Joint Department of Medical Imaging in Toronto, Ontario.

CONTEST JUDGE

JULIE HURTEAU-MILLER, MD, FRCPC

Children's Hospital of Eastern Ontario, Ottawa, ON, Canada

Dr. Hurteau-Miller completed her medical school and radiology residency at the Université de Sherbrooke. From 1996 to 1998, she completed a pediatric radiology fellowship including six months of pediatric neuroradiology at the University of California, Los Angeles (UCLA) and at the Children's Hospital in Los Angeles. For two years, she worked as a pediatric radiologist at the Montreal Children's Hospital. Since 2000, Dr. Hurteau-Miller is assistant professor at the Children's Hospital of Eastern Ontario. Special interests include pediatric neuroradiology, neonatal imaging and fetal MRI.

PRESENTATION:

- Resident Hot Seat Sessions: Pg 43

ALI JAHED, MD, PhD

University of Toronto PGME, Mississauga, ON, Canada

Dr. Jahed studied 10 years at Queen's University attaining a BA, BSc, MSc and PhD. He studied medicine at the University of Western Ontario. Dr. Jahed is currently completing his radiology residency at the University of Toronto. In his spare time, he competes in running races and triathlons but spends most of his time with his three-year-old and his beautiful and supportive wife.

PRESENTATION:

- The Thinking Radiologist – Jeopardy: Radiology Style: Pg 54

ERIK JURRIAANS, MBChB, FRCR, FRCPC

Hamilton Health Sciences, McMaster University, Hamilton, ON, Canada

Dr. Jurriaans graduated from the University of Cape Town, South Africa. He completed a radiology residency at Addenbrooke's Hospital in Cambridge, UK, followed by a fellowship in musculoskeletal imaging at McMaster University and the McMaster University Medical Centre.

Dr. Jurriaans is a staff radiologist at Hamilton Health Sciences and associate professor at McMaster University. He is division head of musculoskeletal imaging at Hamilton Health Sciences. He has an interest in all aspects of musculoskeletal imaging and has authored numerous publications, scientific exhibits and presentations at national and international meetings.

CONTEST JUDGE

JOHN R. KACHURA, MD, FRCPC

University of Toronto, Toronto, ON, Canada

Dr. Kachura completed his radiology residency at the University of Toronto in 1994 and his fellowship in vascular and interventional radiology (VIR) at the University Hospital and Boston City Hospital (Boston Medical Center) in Boston, Massachusetts in 1995. He is currently associate professor, Department of Medical Imaging, University of Toronto. Dr. Kachura is VIR fellowship supervisor for the UHN/MSH and the University of Toronto Department of Medical Imaging. He is past president of the Canadian Interventional Radiology Association (CIRA), and was a member of the Board of Directors of the CAR, (2009–2011). Dr. Kachura's clinical and research interests include radiofrequency ablation of tumours, oncologic embolotherapy, and interventional radiology in obstetrics.

PRESENTATION:

- Resident Review – Interventional Radiology: Pg 40

ELLA KAZEROONI, MD, MS

University of Michigan Medical School, Ann Arbor, MI, USA

Dr. Kazerooni is a professor, associate chair for Clinical Affairs, and division director, Cardiothoracic Radiology at the University of Michigan. Dr. Kazerooni serves as a trustee of the American Board of Radiology, and chairs the American College of Radiology's Committee on Lung Cancer Screening. She has served as president of ARRS, AUR and Society of Thoracic Radiology, as a member of the ACR Board of Chancellors, and is an elected member of SCBT/MR. With a master's degree in clinical research design and statistical analysis, her research focuses on the development/evaluation of advanced imaging technologies applied to the heart/lungs, including lung cancer screening, coronary disease, PE, and diffuse lung diseases.

She has given over 400 lectures and has written over 200 peer-reviewed manuscripts, 60 chapters and 3 books. She began the Radiology Service Excellence Program at her institution and is a frequently invited speaker on the topics of patient satisfaction and service excellence.

PRESENTATION:

- Opening Lecture: Patient-Centered Radiology: The Right Thing for the Right Patient at the Right Time: Pg 34
- Plenary Session: Patient Satisfaction and Service Excellence in Radiology: Pg 35
- The Right Thing – Who is Accountable for the Appropriateness of Studies: The Radiologist or the Referring Physician or Both?: Pg 36

VIVIANE KHOURY, MD

University of Pennsylvania, Philadelphia, PA, USA

Dr. Khoury is an assistant professor in the Musculoskeletal Division of the Department of Radiology at the University of Pennsylvania in Philadelphia, Pennsylvania, where she has been practicing since August 2011.

Dr. Khoury earned her medical degree from McGill University's Faculty of Medicine in Montreal, Quebec. She completed an internship in internal medicine and surgery, and a residency in diagnostic radiology at Dalhousie University in Halifax, Nova Scotia. She then completed a fellowship in musculoskeletal imaging at the University of California San Diego Medical Center.

Dr. Khoury served as an attending radiologist at the Université de Montréal and at the McGill University Health Centre. She specializes in all aspects of musculoskeletal imaging, including MRI, CT, and fluoroscopically-guided procedures. Her subspecialty is ultrasound diagnosis and treatment of tendon and joint disorders and she is currently the Director of Musculoskeletal Ultrasound at the University of Pennsylvania, where she established this service.

Dr. Khoury is board-certified by the American Board of Radiology, the Royal College of Physicians and Surgeons of Canada, and the Collège des Médecins du Québec. She is a member of the Radiological Society of North America, the Society of Skeletal Radiology, and the American College of Radiology.

PRESENTATION:

- Live Ultrasound Simulation Workshop – Approach to Ankle Tendons & Ligaments: Pg 38

ANIA Z. KIELAR, MD, FRCPC

University of Ottawa, Ottawa, ON, Canada

Dr. Kielar completed her radiology training at the University of Ottawa in 2005, followed by a one-year clinical fellowship at the University of Michigan. Dr. Kielar is an assistant professor at the University of Ottawa. She is the director of abdominal imaging at the Ottawa Hospital. She is also a member of the emergency radiology division. Dr. Kielar's current areas of clinical interest and expertise include radiofrequency ablation, imaging during pregnancy and quality initiatives for decreasing errors in radiology reporting.

PRESENTATION:

- Acute Abdominal Pain: Don't Investigate the Patient to Death – Left Lower Quadrant Pain: Pg 40

MARK S. LANDIS, MD, FRCPC(C)

London Health Sciences Centre – Victoria Hospital, London, ON, Canada

Dr. Landis received his medical degree from the University of Toronto and completed his residency in diagnostic radiology at the University of Western Ontario, earning his FRCP(C) in 2011. He subsequently completed his fellowship in thoracic imaging in the Division of Cardiothoracic Imaging at the University of Toronto in the Joint Division of Medical Imaging at the University Health Network in 2012. He currently practices as an academic thoracic radiologist in London, Ontario, at the London Health Sciences Centre – Victoria Hospital.

PRESENTATION:

- Back to Basics – Chest – That Blurry Beating Bag of Blood: The Heart on Radiography and Non-Gated Thoracic Imaging: Pg 45

DAVID LANDRY, MD, FRCPC

McMaster University, Hamilton, ON, Canada

Dr. Landry graduated from McMaster University Medical School in 2002 and completed a diagnostic radiology residency at McMaster University in 2007. He is an assistant professor, Department of Diagnostic Radiology at the Hamilton General Hospital. His clinical interests are cardiac imaging and medical education. He is currently the Program Director for the Diagnostic Radiology Residency Program.

CONTEST JUDGE

JONATHON A. LEIPSIC, MD, FRCPC, FSCCT

University of British Columbia, Vancouver, BC, Canada

Dr. Leipsic is the Chairman of the Department of Radiology for Providence Health Care and the Vice-Chairman of Research for the UBC Department of Radiology. He acts as the co-director of Advanced Cardiac Imaging for the Providence Health Care Heart Centre at St. Paul's Hospital. Dr. Leipsic is actively involved in cardiac CT and MR research with prior involvement in a multi-centre trial evaluating coronary CT angiography vs. QCA. He has over 115 peer-reviewed manuscripts in press or in print in journals including the *JAMA, Circulation* and *JACC* and over 125 scientific abstracts in the last 5 years. These include, but are not limited to, diagnostic performance of CCTA, radiation reduction, FFRCT as well as CT to guide minimally invasive valve intervention.

He speaks internationally on a number of cardiovascular imaging subjects with over 100 invited lectures in the last 4 years. He is currently on the executive committee for the Society of Cardiovascular Computed Tomography and serves as the Society's Treasurer and Vice-President.

PRESENTATION:

- The Thinking Radiologist – Debate – Should Structured Reporting be Mandatory?: Pg 54

BRIAN C. LENTLE, MD

University of British Columbia, Victoria, BC, Canada

Dr. Lentle is a Professor Emeritus in the Department of Radiology at the University of British Columbia (UBC). He was formerly head of the Department of Radiology at UBC and at the Vancouver General Hospital. He serves as consultant radiologist to the Osteoporosis Clinic at the Women's Health Centre in Vancouver, and as radiologist to the Canadian Multicentre Osteoporosis Study (CaMos) and the Steroid-Induced Osteoporosis in a Pediatric Population (STOPP) Studies. He is Chair of the CaMos Quality Assurance Committee.

Dr. Lentle is a past president and Gold Medal recipient of both the Canadian Association of Radiologists and the Radiological Society of North America.

He was awarded the 2011 Lindy Fraser Memorial Award by Osteoporosis Canada and its Scientific Advisory Committee, and the 2014 Paul D. Miller Service Award by the International Society for Clinical Densitometry. In 2013, the Department of Radiology at UBC created the Brian Lentle Teaching Fellowship.

PRESENTATION:

- The Right Thing – Osteoporotic Vertebral Fractures: Pg 37

MICHAEL L. MARTIN, MD

University of British Columbia, Vancouver, BC, Canada

Dr. Martin works as a diagnostic and interventional radiologist at St. Paul's Hospital in Vancouver, BC. He holds the position of Vice-Chair, Quality and Patient Safety in the Department of Radiology at UBC.

MODERATOR:

- The Right Thing: Pg 36
- The Thinking Radiologist – Debate – Should Structured Reporting be Mandatory?: Pg 54

CAITLIN McGREGOR, MD

Sunnybrook Health Sciences Centre, Toronto, ON, Canada

Dr. McGregor completed an honours co-op degree in biochemistry at the University of Waterloo, followed by a degree in medicine at the University of Toronto. Staying in Toronto, she finished her radiology residency in 2001 and followed this with a one-year fellowship in abdominal imaging at Sunnybrook Health Sciences Centre in Toronto where she has been on staff in the abdominal Imaging department for 10 years.

MODERATOR:

- Mistakes We All Make: Pg 55

MATTHEW D. MCINNES, FRCPC

University of Ottawa/The Ottawa Hospital, Ottawa, ON, Canada

Dr. McInnes completed his radiology training at the University of Toronto in 2006, followed by a one-year clinical fellowship in abdominal imaging at the University Health Network at the University of Toronto. He is an associate professor at the University of Ottawa and is currently the Diagnostic Radiology Residency Program Director. He works as a radiologist in the divisions of abdominal and chest radiology in the Department of Medical Imaging at the Ottawa Hospital and is a clinical investigator in the OHRI Clinical Epidemiology program. Dr. McInnes' current area of clinical and teaching interest is imaging of the genitourinary system.

Dr. McInnes' areas of research interest are systematic review and meta-analysis and assessment techniques in post-graduate education. Dr. McInnes is deputy editor for the *Journal of Magnetic Resonance Imaging* and is a manuscript reviewer for *Radiology*.

PRESENTATION:

- Slipping Through the Cracks and Into the Courtroom: A Mock Trial: Pg 56

CONTEST JUDGE

ALEC J. MEGIBOW, MD, MPH, FACR

NYU–Langone Medical Center, New York, NY, USA

Dr. Megibow has been at New York University (NYU) since beginning residency in 1974; he is currently professor of radiology and surgery. Publications include the first series of CT in diverticulitis, collaborations with Dr. Emil Balthazar on CT for acute pancreatitis and acute appendicitis, and the first description of CT for bowel obstruction. He has published over 200 papers, multiple book chapters and text books. He was a principal investigator on NCI-funded technology assessment trial comparing CT and MR in diagnosis of pancreatic colon cancer.

Dr. Megibow served as president of the Society of Computed Body Tomography and is immediate past president of the Society of Abdominal Radiology. He is an Honorary Fellow of the European Society of Gastrointestinal Radiology. He served on the initial ACR incidentaloma task force, responsible for pancreatic cyst recommendations. Current research interests include dual energy CT, pancreatic imaging and rational minimization of radiation dose in CT.

PRESENTATION:

- Plenary Session: The Incidental Findings Conundrum and Integrating the ACR Recommendations Into Practice: Pg 44
- Back to Basics – Body Imaging – An Approach to Pancreatic Lesions: Pg 50
- The Thinking Radiologist – Debate – Should Structured Reporting be Mandatory?: Pg 54

UR METSER, MD

University of Toronto, Toronto, ON, Canada

Dr. Metser is head of the Division of Molecular Imaging and a staff radiologist at the Joint Department of Medical Imaging (UHN, Mount Sinai Hospital and Women's College Hospital) and holds the position of associate professor of radiology, Department of Medical Imaging at the University of Toronto. He has published over 50 manuscripts in peer-reviewed journals and several book chapters. He is also the Chair of the Ontario Provincial Positron Emission Tomography (PET) Steering Committee, as well as acting medical advisor and expert panel member for Cancer Care Ontario's Special PET Access Program. He is also the clinical lead in the core of radiochemistry and nanotechnology at the Techna Institute. Research interests include novel molecular imaging probes, hybrid imaging (PET/CT and PET/MR) for tumor detection and characterization and assessment of response to therapy with functional imaging.

CONTEST JUDGE

LAURENT MILOT, MD, MSc

Sunnybrook Health Sciences Centre, Toronto, ON, Canada

Dr. Milot has done his imaging training in Lyon, France. After a fellowship at the University of Toronto, he joined the staff at Sunnybrook Health Sciences Centre six years ago.

As clinician scientist and member of the Sunnybrook Institute and of the Institute of Medical Science, he is involved as private investigator or co-investigator on multiple research projects around cancer imaging and therapeutics with ultrasound and MRI. He was recently appointed as head of the abdominal imaging division at Sunnybrook, with a goal of unifying clinical practice and research endeavours.

PRESENTATION:

- How I Do It – Live Action – How I Perform an Ultrasound of the Abdomen: Pg 48

DEREK MURADALI, MD, FRCPC(C)

University of Toronto, St. Michael's Hospital, Toronto, ON, Canada

Dr. Muradali is an associate professor of medical imaging, head of the Division of Breast Imaging at the University of Toronto and the radiologist-in-chief of the Ontario Breast Screening Program (OBSP). He has authored multiple publications and book chapters on breast imaging and ultrasound, and has lectured extensively on these topics. His main areas of research include ultrasound contrast agents in the breast, as well as techniques involved in improving breast cancer staging.

PRESENTATION:

- Breast Imaging – Breast Ultrasound Screening: Pg 42

JESSICA MURPHY-LAVALLÉE, MDCM

Centre hospitalier de l'Université de Montréal, Westmount, QC, Canada

Dr. Murphy-Lavallée is a graduate of McGill University in medicine (1998) and a graduate of the Université de Montréal in diagnostic radiology (2004). After completing a fellowship in abdominal imaging at the University of Toronto, she joined the team of radiologists at the Centre hospitalier de l'Université de Montreal where she is presently an assistant clinical professor for the Department of Radiology. She specializes in abdominal imaging and her sub-specialty is contrast ultrasonography. Her scientific research projects are centered on the development of contrast ultrasonography and the teaching of this method in both Quebec and throughout Canada.

CONTEST JUDGE

SANDEEP S. NAIK, MD, FRCPC

University of Alberta, Edmonton, AB, Canada

Dr. Naik completed his radiology residency at the University of Toronto in 1999, followed by a fellowship in neuroradiology at the University of Western Ontario. He returned home to Edmonton in 2001, joining the University of Alberta and becoming a member of Medical Imaging Consultants. He is an assistant professor in the Department of Radiology and Diagnostic Imaging and served as the program director for the University of Alberta Diagnostic Radiology residency program from 2007 to 2013.

PRESENTATION:

- Resident Review – Neuroradiology: Pg 40

ELSIE T. NGUYEN, MD, FRCPC

University of Toronto, Toronto, ON, Canada

Dr. Nguyen completed her thoracic imaging fellowship at Vancouver General Hospital, University of British Columbia, and her cardiovascular imaging fellowship at Stanford University Medical Center, Stanford University, before working as a cardiothoracic radiologist at Toronto General Hospital, University of Toronto. She is the cardiac imaging fellowship director and radiology resident cardiac imaging rotation supervisor at the Toronto General Hospital and Director of the Cardiac Imaging program at Women's College Hospital. Dr. Nguyen won several teaching awards for resident and fellow teaching. She is passionate about mentoring radiology residents and involving them in research with the goal of inspiring them to pursue careers in academic radiology.

MODERATOR:

- The Right Thing – Chest Imaging: Pg 41

PRESENTATION:

- The Right Thing – Chest Imaging – Acute Chest Pain in the Emergency Department: Acute Coronary Syndrome: Pg 41

PATRICIA NOËL, MD, FRCPC

Centre hospitalier universitaire de Québec, Québec, QC, Canada

Dr. Noël completed her abdominal and musculoskeletal MRI fellowship at McGill University in 2005. She is currently radiologist at the CHU de Québec and professor of radiology at Université Laval. Her main academic and research interests are in the field of gynecologic oncology MRI.

MODERATOR:

- Gynecology: Pg 46

HARON OBAID

University of Saskatchewan, Saskatoon, SK, Canada

Dr. Obaid graduated from the College of Medicine at Al-Mustansiriyah University (Iraq) in 1994. He did surgical training in the United Kingdom in 2000–2002 and obtained a surgical fellowship from the Royal College of Physicians and Surgeons of Glasgow (UK). He completed his radiology residency at the University of Leicester (England) in 2007 and obtained a fellowship from the Royal College of Radiologists (London, UK) in 2005. Dr. Obaid then worked as a consultant radiologist with special interest in musculoskeletal radiology in England (2007–2010). He completed his musculoskeletal radiology fellowship training at the University of Toronto in 2010. Since 2011, Dr. Obaid has been working as a clinical assistant professor in musculoskeletal radiology at the University of Saskatchewan.

PRESENTATION:

- Case of the Day – MSK: Pg 35

KATHY O'BRIEN, MD, FRCP(C)

IWK Health Centre, Halifax, NS, Canada

Dr. O'Brien, associate professor of radiology at Dalhousie University, is a pediatric radiologist and women's imaging specialist at the IWK Health Centre in Halifax, Nova Scotia. She is also the division head, Pediatric Radiology at the IWK Health Centre. Her clinical work includes pediatric imaging and obstetric and gynecologic imaging. Her research interests include pediatric MRE for Crohn's Disease, pediatric osteoporosis, neonatal cranial ultrasound and MR of adnexal masses and urogynecology.

PRESENTATION:

- Back to Basics – Pediatric – Pediatric: Body Imaging: Pg 53

ANASTASIA OIKONOMOU, MD, PhD

Sunnybrook Health Sciences Centre, Toronto, ON, Canada

Dr. Oikonomou graduated from the Aristoteles Unversity Medical School in Thessaloniki, Greece (1995). She did her residency in radiology at the Ippokration Hospital of Thessaloniki, Greece (2000) and completed her doctoral thesis at the medical school of Democritus University of Thrace, Greece (2000). Her clinical fellowships included thoracic imaging at Royal Brompton Hospital, London, UK (2001), and thoracic imaging and body MRI at the Ottawa Hospital, Ottawa, Canada (2001–2002). Dr. Oikonomou's research fellowships included thoracic imaging at Vancouver General Hospital (2002), and cardiac imaging at the Heart Institute and Ottawa Hospital (2012). She became a fellow of the Society of Cardiovascular Computed Tomography (2013). Dr. Oikonomou worked as a lecturer and assistant professor of radiology in the Department of Medical Imaging, University Hospital of Alexandroupolis, Democritus University of Thrace, Greece (2003–2013). She is currently working as assistant professor in chest radiology at the Sunnybrook Health Sciences Centre of Toronto.

Dr. Oikonomou is first author or co-author of 52 articles in peer-reviewed journals and has given 22 invited lectures in international congresses. She has authored or co-authored 3 chapters in radiology books. She is a member of the Executive Committee of European Society of Thoracic Imaging and of the Editorial Board of European Radiology and is also the Section Editor for chest imaging in EURORAD.

PRESENTATION:

- The Right Thing – Chest Imaging – Practice Guidelines for Management of Solid and Subsolid Nodules: Pg 41

MARTIN E. O'MALLEY, MD

Joint Department of Medical Imaging, University of Toronto, Toronto, ON, Canada

Dr. O'Malley is a staff radiologist in the Abdominal Imaging Division, Joint Department of Medical Imaging, University of Toronto. He is the site director for medical imaging at Princess Margaret Hospital and supervisor of the Abdominal Imaging Fellowship Program. He has a clinical and research interest in genitourinary radiology and is the author/co-author of over 40 peer-reviewed articles in major radiology and medical journals. He has received multiple teaching awards from the radiology residency and fellowship programs at the University of Toronto.

PRESENTATION:

- Back to Basics – Body Imaging – An Approach to Renal Lesions: Pg 50

JOSEPH P. O'SULLIVAN, FRCPC

The Ottawa Hospital, Ottawa, ON, Canada

Dr. O'Sullivan, an Ottawa native, received his medical degree at the University of Ottawa in 1982. After being in general practice in French and English in Quebec and the Maritimes, he returned to Ottawa and completed his training in radiology in 1990.

He has been a radiologist in abdominal and pelvic imaging at the Ottawa Hospital since it was created. He has seen many changes in radiology over the years, which have mostly increased the relevance and scope of the specialty. He is concerned by the push for structured reporting and how it may alter the practice of radiology at a fundamental level.

PRESENTATION:

- The Thinking Radiologist – Debate – Should Structured Reporting be Mandatory?: Pg 54

ANUKUL PANU, MD, FRCPC

University of Alberta, Edmonton, AB, Canada

Dr. Panu is a radiologist working with Medical Imaging Consultants at the University of Alberta. He completed a musculoskeletal radiology fellowship at the Hospital for Special Surgery in New York City in 2013. When not at the workstation, he can be found on the tennis courts.

PRESENTATION:

- Resident Review – Musculoskeletal: Pg 38

NEETY PANU, MD, FRCPC

Pembroke Regional Hospital, Pembroke, ON, Canada

Dr. Panu is currently on staff at the Pembroke Regional Hospital and Sioux Lookout Meno Ya Win Health Centre, both in Ontario. Dr. Panu completed her radiology training at the University of Saskatchewan, followed by a fellowship in breast and body imaging at Memorial Sloan-Kettering Cancer Center in New York City.

Dr. Panu is involved with the CAR as a board member and is actively involved in different groups on the board, as well as on provincial and national organizations in the field of breast imaging. Her main focus is resident teaching, standardized reporting and standardization of radiology practice with the appropriate use of practice guidelines.

When not involved in radiology, Dr. Panu can be found running ultra marathons or trekking around the globe and cross-country skiing in the winter months.

PRESENTATION:

- Resident Review – Mammography: Pg 38
- Resident Hot Seat Sessions: Pg 43

MODERATOR:

- Resident Review: Pg 38 and 40

CHIRAG PATEL, BSc, MBBS, MRCP, FRCR

Sunnybrook Health Sciences Centre, Toronto, ON, Canada

Dr. Patel is a cross-sectional staff radiologist at Sunnybrook Health Sciences Centre, University of Toronto in the division of abdominal imaging. Clinical interests include emergency and oncology radiology with specific clinical and research interests in image-guided diagnostic intervention.

PRESENTATION:

- Mistakes We All Make – Abdominal Imaging: Pg 55

MICHAEL N. PATLAS, MD, FRCPC

McMaster University, Hamilton, ON, Canada

Dr. Patlas is associate professor of radiology and chief of the Emergency/Trauma Division at McMaster University in Hamilton. He pursued fellowships in abdominal and women's imaging at the University of Toronto. Dr. Patlas joined the McMaster University faculty in 2004. He is an editorial board member of *Annals of Clinical & Laboratory Science* and reviewer for multiple journals. He is a member of the Scientific Program Committee of the RSNA and the RadioGraphics Subspecialty Panel. He served as faculty for numerous North American and international conferences.

His main research interests include imaging of traumatic and non traumatic abdominal emergencies. Dr. Patlas is proud to serve as chair of submissions with the CAR for 2014–2016, as member of the Annual Scientific Meeting and CPD working groups, as session leader and faculty.

PRESENTATION:

- Acute Abdominal Pain: Don't Investigate the Patient to Death – Left Upper Quadrant Pain: Pg 39

MODERATOR:

- Acute Abdominal Pain: Don't Investigate the Patient to Death: Pg 39

DEMETRIS PATSIOS, BA, BM BCh, MRCP (UK), FRCR (UK)

Mount Sinai and Women's College Hospitals, Toronto, ON, Canada

Dr. Patsios is currently staff radiologist in thoracic imaging, Joint Department of Medical Imaging for the University Health Network, Mount Sinai and Women's College Hospitals. He obtained his BA and BM BCh at Oxford University and completed his fellowship in thoracic imaging at the University of Toronto. From 1995 to 1999, Dr. Patsios was a resident in internal medicine in Manchester, UK and from 1999 to 2003, he was a resident in diagnostic radiology, Manchester Radiology Training Scheme, UK.

Dr. Patsios is the author of numerous journal articles and papers and he has also participated in several conferences as an invited lecturer/speaker.

PRESENTATION:

- Case of the Day – Chest: Pg 44

MODERATOR:

- Case of the Day – MSK and Neuroradiology: Pg 35
- Case of the Day – Body and Chest: Pg 44

LAURENCE PÉLOQUIN, MD

Centre hospitalier de l'Université de Montréal (CHUM), Montreal, QC, Canada

Dr. Péloquin obtained her medical diploma from McGill University in 2002. Following her residency training at the Université de Montréal, she completed her fellowship training in breast and body imaging at Memorial Sloan-Kettering Cancer Center in New York. In July 2008, she joined the radiology department at the Centre hospitalier de l'Université de Montréal (CHUM) in the abdominal imaging section. A member of the CAR Board of Directors, she is also actively involved in teaching. She was selected as a pedagogical leader by the training committee at the Université de Montréal with the mandate to improve and design evaluation tools for CanMEDS competencies for radiology residents. Her principal field of interest is oncologic imaging, particularly gynecological and genitourinary imaging.

PRESENTATION:

- Resident Review – Abdominal MRI: Pg 38
- Gynecology – Practical Approach to Ultrasound Evaluation of Cystic Adnexal Masses: Pg 46

ELENA PEÑA

The Ottawa Hospital, Ottawa, ON, Canada

Dr. Peña is a cardiothoracic radiologist in the Department of Medical Imaging, Cardiothoracic and Emergency Radiology section at the Ottawa Hospital and an assistant professor at the University of Ottawa.

A graduate of the Universidad Autónoma de Madrid, she trained in radiology in Madrid, Spain, and followed with a fellowship in cardiac and chest radiology at the University of Ottawa. She is involved in medical student, resident and fellow training, as well as in post-fellowship teaching. She is the resident supervisor for the cardiac imaging rotation and has been a lecturer at the Resident Review Course held in Ottawa in March annually since 2010. She was the co-director for the past CME course entitled "Cardiopulmonary Imaging Update" held in June 2013 in Quebec City.

Dr. Peña has published several peer-reviewed articles and two book chapters, and presented many oral presentations and posters at regional, national and international meetings. Her primary clinical interest is in cardiopulmonary imaging. Her major research interests are in pulmonary vascular diseases, pulmonary hypertension, heart failure and cardiomyopathies, use of cardiac CT in acute chest pain in the emergency department, and interstitial lung diseases.

PRESENTATION:

- The Right Thing – Chest Imaging – The Right Test at the Right Time: Acute Pulmonary Embolism: Pg 41

LINDA PROBYN, MD, FRCPC

Sunnybrook Health Sciences Centre, University of Toronto, Toronto, ON, Canada

Dr. Probyn is a musculoskeletal radiologist at Sunnybrook Health Sciences Centre, University of Toronto. She received her medical degree from the University of Western Ontario. After completing her residency in diagnostic radiology at McMaster University, she did a fellowship in musculoskeletal imaging at the University of Toronto. She is the past program director for the Residency Program and is now the Vice-Chair of Education for the Department of Medical Imaging.

Dr. Probyn has a strong interest in teaching, mentoring and evaluating residents and has won several teaching awards for residency education. She has developed and implemented curricula into the residency program and has presented her scholarly work at national and international conferences. She is currently developing a program and researching ultrasound simulation to teach diagnostic and procedural skills to trainees.

PRESENTATION:

- Live Ultrasound Simulation Workshop – Approach to Ankle Tendons and Ligaments: Pg 38

MARTIN H. REED

University of Manitoba and Winnipeg Children's Hospital, Winnipeg, MB, Canada

Dr. Reed is the Chair of the Referral Guidelines Working Group of the CAR. He is also a member of the Appropriateness Criteria Committee of the American College of Radiology and of the Editorial Board of the Diagnostic Imaging Pathways, and is a co-convenor of the IRQN/WHO International Guidelines Working Group. He is a professor of radiology and of pediatrics and child health at the University of Manitoba, and a member of the Department of Diagnostic Imaging at the Children's Hospital in Winnipeg. His research interests include health services research in radiology, in particular, guidelines, utilization and quality improvement. He was the lead investigator for the Clinical Decision Support in Diagnostic Radiology Project (carried out at the Children's Hospital of Winnipeg), and for a similar project at the Steinbach Family Medical Centre, which were designed to test the effect of embedding the CAR's guidelines for diagnostic imaging in an electronic order entry software program.

PRESENTATION:

- The Right Thing – Point of Order Decision Support: Pg 37

CAR GOLD MEDAL AWARD 2014

SHIA SALEM, MD, FRCPC

Mount Sinai Hospital, Toronto, ON, Canada

Dr. Salem is an associate professor of radiology at the University of Toronto, and a radiologist in the Joint Department of Medical Imaging at Mount Sinai Hospital, University Health Network and Women's College Hospital. His main area of practice is ultrasound, with specific interest in obstetrics and gynecology.

Dr. Salem has been intimately involved in the development of national standards for ultrasound practice for the past 20 years, both for the CAR as chair of its Working Group and with the Society of Obstetricians and Gynaecologists of Canada (SOGC) as the CAR representative on their Diagnostic Imaging Committee.

In 2004, he was the second recipient of the Lifetime Achievement Award of the Ontario Association of Radiologists.

This past year, Dr. Salem received a Certificate of Appreciation from the Royal College of Physicians and Surgeons of Canada for his exemplary leadership and dedication to excellence in obstetric ultrasound education, followed shortly thereafter by the CAR Gold Medal.

PRESENTATION:

- Resident Review – Ultrasound: Pg 38

MARCOS L. SAMPAIO, MD

University of Ottawa, Ottawa, ON, Canada

Dr. Sampaio is a clinical teacher and assistant professor of radiology at the University of Ottawa. He is also the MSK rotation residents supervisor, radiation protection officer of The Ottawa Hospital/ General Campus and lead of x-ray modality.

He graduated in electronic engineering (1994) and in medicine in 2002 from the University of Sao Paulo (USP-Sao Paulo, Brazil), his place of birth. He also completed his radiology residency and clinical fellowship in MSK radiology (INRAD–FMUSP). In 2007, he completed a six-month research fellowship at the Hospital for Bone and Joint Diseases (New York University).

Areas of interest include: ultrasound and MRI applications in MSK imaging, optimization of imaging protocols, sports medicine, rheumatology, anatomy, biomechanics, imaging-guided MSK procedures and medical education.

PRESENTATION:

- Live Ultrasound Simulation Workshop – Approach to Ankle Tendons and Ligaments: Pg 38

MATTHIAS SCHMIDT

Dalhousie University, Halifax, NS, Canada

Dr. Schmidt received his bachelor's and master's degrees and his medical doctorate from the University of Toronto. He completed a residency in diagnostic radiology at the University of Western Ontario and fellowship training in pediatric radiology at The Hospital for Sick Children. He completed a second fellowship in diagnostic and interventional neuroradiology at Dalhousie University.

Dr. Schmidt is currently associate professor of radiology and medical neuroscience at Dalhousie University. He is Director of Research in the Department of Radiology. He continues to be active in neuroimaging research and contributes to the development of national guidelines and standards for pediatric imaging, neuroimaging and MRI as an invited member of committees, working groups and expert advisory panels.

PRESENTATION:

- Mistakes We All Make: Neuroradiology: Pg 55

JEAN SEELY, MD

The Ottawa Hospital, Ottawa, ON, Canada

Dr. Seely is head of the Breast Imaging Section at the Ottawa Hospital, in the Department of Medical Imaging and at the Women's Breast Health Centre in Ottawa. She is associate professor at the University of Ottawa, and regional breast imaging lead for the Ontario Breast Screening Program in the Champlain – Ottawa region. She set up the breast MRI program in 2001 in Ottawa and specializes in breast and chest disease.

PRESENTATION:

- Breast Imaging – Breast MRI: When Is It Not Useful?: Pg 42

CAROLINA SOUZA, MD

The Ottawa Hospital / University of Ottawa, Ottawa, ON, Canada

Dr. Souza is a thoracic radiologist and the Thoracic Imaging Fellowship Director at the Ottawa Hospital. She is also an associate professor of the University of Ottawa.

Dr. Souza is originally from Brazil where she obtained her medical degree. In 2004, she completed her residency program in radiology and was accepted for a two-year research and clinical fellowship in thoracic imaging at the Vancouver General Hospital under Dr. Nestor Muller's supervision. During her first year as a research fellow, Dr. Souza completed several research projects that were published in renowned peer-reviewed journals. In May 2006, she obtained her PhD in radiology from the University of Rio de Janeiro, Brazil.

Since the completion of her thoracic imaging fellowship in 2006, Dr. Souza has been working as a staff radiologist at the Ottawa Hospital where she actively teaches medical students, residents and thoracic fellows. She obtained the "Teacher of the Year Award" in 2008 and received the Honorable Mention for the same award the following year. Dr. Souza has lectured at local, provincial and national levels, including thoracic imaging CME courses in Canada and the Ottawa Residents' Review Course. She continues to work on research in thoracic radiology. Her main areas of interest include interstitial and diffuse lung diseases and recent advances in lung cancer.

PRESENTATION:

- Resident Review – Chest: Pg 38
- Back to Basics – Chest – Interstitial Lung Disease: Don't Panic!: Pg 45

MODERATOR:

- Back to Basics – Chest: Pg 45

AN TANG, MD, MSc

Centre hospitalier de l'Université de Montréal (CHUM), Montreal, QC, Canada

Dr. Tang completed his specialty degree in radiology at the Université de Montréal in 2005. He subsequently pursued fellowship training in abdominal imaging at the University of Toronto in 2006. In September 2006, Dr. Tang joined the team of radiologists at the CHUM. Supported by fellowship awards from the Fulbright Program and the Canadian Institutes of Health Research, he pursued a research fellowship in liver magnetic resonance imaging at the University of California, San Diego in 2011–2012. He is a contributor and member of the Liver Imaging Reporting and Data System (LI-RADS) Committee for the standardized interpretation and reporting of CT and MR examinations of hepatocelllular carcinoma (HCC).

Dr. Tang is presently an assistant professor of radiology at the Université de Montréal. His current research interest is focused on the comparison of MR- and US-based elastography for the non-invasive staging of liver fibrosis.

PRESENTATION:

- Back to Basics – Body Imaging – An Approach to Liver Lesions: Pg 50

JANA TAYLOR, BSc, MDCM

McGill University Health Centre, Montreal, QC, Canada

Dr. Taylor has been a thoracic and abdominal radiologist at the McGill University Health Centre since 2005 where she is also an assistant professor. She completed her medical school and residency at McGill University followed by fellowships at the Massachusetts General Hospital and McGill University Health Centre (MUHC).

She has been a member of the board of directors of the CAR since 2010. She is an examiner for the Royal College of Physicians and Surgeons of Canada and the Director of the Thoracic Imaging Fellowship program at the MUHC.

Lung cancer screening is a particular area of interest. Dr. Taylor is currently the principal investigator for the Montreal site of the International Early Lung Cancer Screening Project (I-ELCAP) and the chairperson of the Radiology Guidelines Working Group for the Pan-Canadian Lung Cancer Screening Network.

PRESENTATION:

- Slipping Through the Cracks and Into the Courtroom: A Mock Trial: Pg 56

MICHELINE THIBODEAU, MD, FRCP(C)

Centre hospitalier de l'Université de Montréal, Montreal, QC, Canada

Dr. Thibodeau has been working in abdominal radiology at the Centre hospitalier de l'Université de Montréal (CHUM) since 2001. She completed medical school at the Université de Montréal, followed by a residency in radiology at McGill University. She did two fellowships: one in abdominal radiology at the Montreal General Hospital with Dr. Patrice Bret, and one in interventional radiology at the Hospital of the University of Pennsylvania (Philadelphia) with the late Dr. Igor Laufer.

Prior to her arrival at CHUM, she worked at the McGill University Centre for 10 years, and at the Hôpital Sacré-Cœur in Montreal (1987–1991).

Dr. Thibodeau is actively involved as member of the Revision Committee at the Collège des Médecins du Québec (she was a board member of the College for 4 years) and as President of the French-Canadian Society of Radiology.

MODERATOR:

- CAR Radiologists-in-Training Awards: Pg 52

ANTS TOI, MD, FRCPC, FAIM

Mount Sinai Hospital, Toronto, ON, Canada

Dr. Toi is a professor of radiology and of obstetrics and gynecology at the University of Toronto and works at the Mount Sinai Hospital. He trained and taught at other universities: University of Toronto, Harvard, University of California at San Francisco and McMaster University. He has been involved with prenatal fetal diagnosis for many years and has written and spoken extensively in this area. He is active in standards committees for the CAR, the SOGC and the ISUOG.

PRESENTATION:

- How I Do It – Live Action – Obstetrical Ultrasound: The Second Trimester: Pg 48

R. PETTER TONSETH, BSC, MD, FRCPC

BC Cancer Agency, Vancouver, BC, Canada

After attending the University of Victoria and obtaining a Bachelor of Science in biology, Dr. Tonseth completed medical school at the University of British Columbia (UBC) in 1988 and a rotating internship through the Dalhousie University program in 1989 before working as a general practitioner in many coastal BC communities. In 1999, the opportunity to enter the UBC radiology residency brought Dr. Tonseth and his wife back from sailing offshore on their 34-foot sailboat. They lived aboard the vessel in False Creek while Dr. Tonseth completed the dual radiology/nuclear medicine program. In 2004, he began practicing with Night Hawk Radiology Services (NRS), providing teleradiology support to multiple sites across the United States, while doing locums in various communities in BC, the Northwest Territories, Alberta and Australia. In early 2011, he returned to BC to accept a position in the Functional Imaging Department at the BC Cancer Agency.

PRESENTATION:

- Resident Review – Nuclear Medicine: Pg 40
- Resident Hot Seat Sessions: Pg 43

CARLOS TORRES, MD

University of Ottawa, Ottawa, ON, Canada

Dr. Torres is an assistant professor of radiology at the University of Ottawa and a staff neuroradiologist at The Ottawa Hospital since 2008. He pursued a two-year neuroradiology fellowship at McGill University before joining the Department of Diagnostic Imaging at The Ottawa Hospital.

Dr. Torres has been Director of the Royal College-accredited Neuroradiology Fellowship Program since 2010 and he is currently the Interamerican College of Radiology Vice-President for North America. He has been invited to lecture in multiple national and international meetings and is an international visiting professor for the Radiological Society of North America (RSNA). Since 2010, Dr. Torres is also visiting professor for the Colegio Interamericano de Radiología (Interamerican College of Radiology – CIR).

Dr. Torres is actively involved in medical education and research. His main areas of interest are demyelinating disease, brachial plexus, cord and tumor imaging.

PRESENTATION:

- Case of the Day – Neuroradiology: Pg 35
- Young Radiologists – Preparation for Academic Promotion: Pg 51

NANCY WADDEN, MD

Memorial University of Newfoundland, St. John's, NL, Canada

Dr. Wadden is the Medical Director of the Breast Screening Program for Newfoundland and Labrador and clinical associate professor in the Faculty of Medicine at Memorial University of Newfoundland.

Dr. Wadden graduated from Memorial University in 1977 with a bachelor's of science, majoring in biochemistry, and was awarded the Birks Gold Medal for contributions to student affairs. She graduated from the Memorial University School of Medicine in 1984 and went on to an internship at Toronto General Hospital. In 1989, she completed residency training in diagnostic radiology at the University of Toronto, then a fellowship in breast and body imaging at the Toronto General Hospital.

While a staff radiologist at the Toronto Hospital and a faculty member of the University of Toronto, Dr. Wadden received several teaching excellence awards. In 1996, she co-authored an award-winning educational CD ROM entitled "Fundamentals of Breast Imaging".

Dr. Wadden is the chair of the Mammography Accreditation Program Staff Working Group and a member of the Practice Guidelines in Breast Imaging in Canada for the CAR. She has organized numerous breast imaging courses and has delivered many invited lectures. She continues to be involved with the Canadian Breast Cancer Screening Initiative and with the Canadian Mammography Quality Standards Working Group. She serves on several other provincial and national committees dealing with diagnostic imaging, breast screening and breast cancer.

PRESENTATION:

- Breast Imaging – Woman Aged 40–49: The Case In Favour of Screening: Pg 42

SHELDON WIEBE, MD, MSc, FRCPC

University of Saskatchewan, Saskatoon, SK, Canada

Dr. Wiebe received his medical degree in 1995 from the University of Saskatchewan and his FRCPC (diagnostic radiology) in 2002 at the University of Saskatchewan. He completed his pediatric radiology fellowship (2002–2004) at The Hospital for Sick Children, University of Toronto and later on completed his Master's of Science in 2012 at the University of Saskatchewan.

Since July 2004, Dr. Wiebe has been in clinical practice in the areas of pediatric and general radiology at the Royal University Hospital, Saskatoon, Saskatchewan.

CONTEST JUDGE

EUGENE YU, MD, FRCPC

Princess Margaret Cancer Centre, Toronto, ON, Canada

Dr. Yu is an assistant professor in the departments of medical imaging and otolaryngology and of head and neck surgery at the University of Toronto. He completed his medical degree at the University of Toronto in 1996. His residency training was in medical imaging at the University of Toronto and he is currently a fellow of the Royal College of Physicians and Surgeons of Canada. Dr. Yu did a post-residency fellowship in neuroradiology at the University of Toronto. He is also the site director of the Neuroradiology Fellowship Program and of the Radiology Residency Program at Princess Margaret Hospital.

Dr. Yu's academic focus is in head and neck radiology. He is an active member of the American Society of Head and Neck Radiology, the North American Skull Base Society, the Eastern Neuroradiological Society and an associate member of the American Head and Neck Society. He is also a member of the Faculty Advisory Committee of the *University of Toronto Medical Journal* and a member of Medical Imaging Committee for undergraduate medical education at the University of Toronto.

PRESENTATION:

- Back to Basics – Head & Neck – Head and Neck Case Review: Cases Referred from Outside Non-Specialist MDs: Pg 47

MODERATOR:

- Back to Basics – Head & Neck: Pg 47

AGFA

HealthCare

Christie innoMed

Solutions · Evolution · Vision

Christie InnoMed Inc. a acquis une excellente réputation au Canada durant les 60 dernières années en tant que distributeur, intégrateur et concepteur solide et fiable dans les domaines de l'imagerie médicale et des solutions de gestion de l'information. Notre partenariat unique et exclusif avec quelques uns des meilleurs fournisseurs d'équipements d'imagerie médicale au monde nous permet de fournir aux établissements de santé du Canada des technologies modernes qui améliorent considérablement les soins aux patients ainsi que l'efficacité des flux de travail. Notre approche axée sur l'excellence nous permet de choisir les meilleures options pour nos clients et de personnaliser des solutions de pointe qui maximiseront leurs investissements en biens d'équipement.

Notre filiale, **Stat-Dev Inc.,** se spécialise dans le développement d'applications cliniques dans le domaine de la santé. Stat-Dev est présente dans le secteur de la santé avec plus de 60 implantations. Depuis sa fondation en 2003, Stat-Dev a concentré ses efforts et ses investissements en recherche et développement dans la création de sept nouveaux produits, dont le triage à l'urgence, la gestion des lits, le transport et la gestion des aires d'attente.

Une compagnie importante de solutions logicielles, **ABS Systems** qui est une compagnie du groupe Christie, se spécialise dans la mesure du rendement dans le domaine de la santé, l'extraction d'information d'entreprise, et les technologies d'aide à la décision. En combinant une technologie de pointe avec une excellente compréhension des besoins des professionnels dans le domaine de la santé, ABS Systems a développé une technologie primée de la mesure du rendement - la solution idéale pour la gestion d'une entreprise de soins de santé à n'importe quelle échelle.

Christie InnoMed Inc. has built a sound reputation within Canada for the past 60 years as a trusted and reliable distributor, integrator and designer of medical informatics and imaging solutions. Our unique and exclusive partnerships with some of the top global medical imaging vendors allow us to provide Canadian healthcare institutions with state-of-the-art technologies that significantly improve patient care and workflow efficiencies. Our best-of-breed approach enables us to select the best options for our customers and customize a leading edge solution that will maximize their return on investment for capital equipment.

Christie InnoMed Inc.'s subsidiary, **Stat-Dev Inc.,** specializes in the development of clinical applications in healthcare. Stat-Dev is present in the health sector at more than 60 locations. Since it was founded in 2003, Stat-Dev has concentrated its efforts and investments in Research and Development (R&D), resulting in the creation of seven new products, such as emergency triage, bed management, transport and flow management of waiting areas.

ABS Systems, a Christie Group company, is a leading software company specializing in healthcare performance measurement, business intelligence, and decision support technologies. Combining cutting edge technology with in-depth understanding of the needs of healthcare professionals, ABS Systems developed an award winning performance measurement technology - the ideal solution for managing a healthcare business of any scale.

www.christieinnomed.com **1888882-8898**


CT


Gastrointestinal Imaging


Cardiac and Vascular Imaging


MRI

BRACCO IMAGING Canada

Solutions for diagnostic imaging

For additional information concerning our products, please contact us by dialing 1-800-465-5820
BRACCO IMAGING Canada, 11065 Louis H.-Lafontaine, Anjou, Québec, H1J 2Z4

BRACCO
BRACCO IMAGING Canada